



حقيبة تعليمية

التشريح والفسلجة

Anatomy and physiology

إعداد

التدريسي الرئيسي: م.م سل سعد فائق

التدريسي الثانوي: م.د جاسم محمد

2023 - 2022

المقدمة

تهدف المادة الى تحضير الطالب لدراسة و فهم الاجهزة الطبية وذلك بتوضيح التغيرات الفسلجية وخاصة الكهربائية منها و التي تتم عند قيام الاعضاء المختلفة للجسم بوظيفتها وعلاقتها بالاجهزة التي تستعمل لقياس و تشخيص الظواهر والامراض المختلفة

The course aims to prepare the student to study and understand medical devices by clarifying the physiological changes, especially the electrical ones, which occur when the various organs of the body perform their function and their relationship to the devices that are used to measure and diagnose various phenomena and diseases.

فهرس المحتويات

الصفحة	الموضوع	م
2	المقدمة	1
3	فهرس المحتويات	2
4	وصف المقرر الدراسي	3
13	إرشادات للطلبة	4
14	المحاضرة الاولى cell	5
20	المحاضرة الثانية: tissue	6
22	المحاضرة الثالثة: integumentary system	7
26	المحاضرة الرابعة skeletal	8
28	المحاضرة الخامسة: Articulation p1	9
31	المحاضرة السادسة: Articulation p2	10
34	المحاضرة السابعة: muscular	11
39	المحاضرة الثامنة: nervous	12
43	المحاضرة التاسعة: CNS	13
49	المحاضرة العاشرة: Atuonomic nervus system	14
52	المحاضرة الحادية عشر: sensory- motor function p1	15
56	المحاضرة الثانية عشر: sensory-motor p2	16
60	المحاضرة الثالثة عشر: endocrine	17
62	المحاضرة الرابعة عشر: blood p1	18
67	المحاضرة الخامسة عشر: blood p2	19
70	المحاضرة السادسة عشر: heart 1	20
76	المحاضرة السابعة عشر: heart2	21
83	المحاضرة الثامنة عشر: blood vessels 1	22
87	المحاضرة التاسعة عشر: blood vessels 2	23
91	المحاضرة العشرون: lymphatic and immune p1	24
98	المحاضرة الحادي والعشرون: lymphatic and immune p2	25
103	المحاضرة الثانية والعشرون: respiratory p1	26
107	المحاضرة الثالثة والعشرون: respiratory p2	27
109	المحاضرة الرابعة والعشرون: digestive p1	28
112	المحاضرة الخامسة والعشرون: digestive p2	29
115	المحاضرة السادسة والعشرون: metabolisim	30
119	المحاضرة السابعة والعشرون: the urinary system	31
123	المحاضرة الثامنة والعشرون: fluid-electrolyte p1	32
125	المحاضرة التاسعة والعشرون: fluid-electrolyte p2	33
128	المحاضرة الثلاثون: reproductive	34

وصف المقرر الدراسي

COURSE SPECIFICATION

This Course Specification provides a concise summary of the main features of the course and the learning outcomes that a typical student might reasonably be expected to achieve and demonstrate if he/she takes full advantage of the learning opportunities that are provided. It should be cross-referenced with the programme specification.

1. Teaching Institution	AL-Rasheed University College
2. University Department/Centre	Medical Instrumentations Techniques Engineering
3. Course title/code	Anatomy & Physiology
4. Programme(s) to which it contributes	
5. Modes of Attendance offered	Weekly (theoretical + practical)
6. Semester/Year	2022-2023
7. Number of hours tuition (total)	120(60theoretical + 60practical)
8. Date of production/revision of this specification	2022
9. Aims of the Course	
	1- study and understand medical devices by clarifying the physiological changes
	2-study the various organs of the body perform their function and their relationship to the devices
	3-understand the anatomy of human body and the physiological function of its organs.
	4- training on ways are used to measure and diagnose various phenomena and diseases.

<p>A- Knowledge and Understanding</p> <p>A1. Understand the basic components of the medical device</p> <p>A2 - Studying laboratory equipment and types</p> <p>A3-Learn the usefulness of each laboratory device</p> <p>A4 - Studying sterilization devices</p> <p>A - Studying old and modern medical devices</p> <p>A6 - Study of radiation and physiotherapy equipment</p> <p>A7 - Studying the infant incubator and its usefulness</p>					
<p>B. Subject-specific skills</p> <p>B1. Explains the cause of the malfunction of the medical device</p> <p>B. The computer is used to store the specifications of the medical device</p> <p>B.3. The computer is used as a means of comparing the medical conditions taken from the medical device with data for natural cases stored in the computer B-</p> <p>Diagnoses the results of the medical system</p>					
Teaching and Learning Anatomical positions					
Laboratory experiments with human body anatomical models					
Assessment methods					
Daily / quarterly tests					
Practical activities or public activities					
<p>C. Thinking Skills</p> <p>C1 - to listen attentively to the student to explain the stadium student.</p> <p>C2- A student should feel the suffering of victims of racial discrimination</p> <p>C3- to recognize the student the impact of science and scientists in life</p> <p>C4- The student should describe the importance of learning medical equipment</p>					
Teaching and Learning Methods					
Seminars - Educational guidance					
Assessment methods					
Discuss the stadium with the student - discuss the student with his colleague					
<p>D. General and Transferable Skills (other skills relevant to employability and personal development)</p> <p>D1 - Office skills outside the scientific subject</p>					
11. Course Structure					
	Hours		Unit/Module or Topic Title		Assessment Method

Week		ILOs		Teaching Method	
1-2	4TH+4P	The student understands the lesson	Cells & Tissues	Theoretical lecture	Pretest-post test
3	2TH+2P	The student understands the lesson	The integumentary system.	Theoretical lecture	Pretest-post test
4	2TH+2P	The student understands the lesson	The skeletal system.	Theoretical lecture	Pretest-post test
5-6	4TH+4P	The student understands the lesson	Articulations	Theoretical lecture	Pretest-post test
7	2TH+2P	The student understands the lesson	The muscular system.	Theoretical lecture	Pretest-post test
8	2TH+2P	The student understands the lesson	Nervous tissue	Theoretical lecture	Pretest-post test
9	2TH+2P	The student understands the lesson	Central nervous system.	Theoretical lecture	Pretest-post test
10	2TH+2P	The student understands the lesson	Autonomic nervous system	Theoretical lecture	Pretest-post test
11-12	4TH+4P	The student understands the lesson	Sensory, motor and integrative functions	Theoretical lecture	Pretest-post test
13	2TH+2P	The student understands the lesson	The endocrine system.	Theoretical lecture	Pretest-post test
14-15	4TH+4P	The student understands the lesson	The cardiovascular system: Blood.	Theoretical lecture	Pretest-post test
16-17	4TH+4P	The student understands the lesson	the cardiovascular system: the heart	Theoretical lecture	Pretest-post test
18-19	4TH+4P	The student understands the lesson	the cardiovascular system: Blood vessels.	Theoretical lecture	Pretest-post test

20-21	4TH+4P	The student understands the lesson	the lymphatic system and immunity.	Theoretical lecture	Pretest-post test
-------	--------	------------------------------------	------------------------------------	---------------------	-------------------

22-23	4TH+4P	The student understands the lesson	The respiratory system.	Theoretical lecture	Pretest-post test
24-25	4TH+4P	The student understands the lesson	the digestive system.	Theoretical lecture	Pretest-post test
26	2TH+2P	The student understands the lesson	Metabolism	Theoretical lecture	Pretest-post test
27	2th+2p	The student understands the lesson	The urinary system.	Theoretical lecture	Pretest-post test
28-29	4 th +4p	The student understands the lesson	Fluid, electrolyte and Acid – Base balanc	Theoretical lecture	Pretest-post test
30	4 th +4p	The student understands the lesson	The reproductive system	Theoretical lecture	Pretest-post test

D - the student's ability to scientific research

D3 - the student's ability to participate in extra-curricular activities

12. Infrastructure

13. Admissions

Pre-requisites

Minimum number of students

Maximum number of students

نموذج وصف المقرر

وصف المقرر

يوفر وصف المقرر هذا إيجازاً مقتضياً لأهم الكلية خصائص تقني وهندسية لتعلم المتوقعة من الطالب تحقيقها مبرهنأ عما إذا كان قد حقق الاستفادة القصوى من فرص التعلم المتاحة. ولا بد من الربط بينها

كلية الرشيد الجامعة	9. المؤسسة التعليمية
هندسة تقنيات الاجهزة الطبية	. القسم العلمي /
الاجهزة الطبية	11. اسم / رمز المقرر
اسبوعي (نظري + عملي)	12. أشكال الحضور المتاحة
2022-2023	13. الفصل / السنة
120 (60 نظري + 60 عملي)	14. عدد الساعات الدراسية (الكلي)
2022	15. تاريخ إعداد هذا الوصف

طرائق التعليم والتعلم
تجارب مختبرية على الاجهزة الطبية
طرائق التقييم
اختبارات يومية / فصلية انشطة عملية او انشطة عامة

ج- الأهداف الوجدانية والقيمية ج1- ان يصغي الطالب بانتباه الى شرح الاستاد ج2- ان يحس الطالب بما يعانیه ضحايا التمييز العرقي ج3- ان يتعرف الطالب على اثر العلم والعلماء في الحياة ج4- ان يصف الطالب اهمية تعلم مادة الاجهزة الطبية
طرائق التعليم والتعلم
ندوات – ارشاد تربوي
طرائق التقييم
مناقشة الاستاد مع الطالب – مناقشة الطالب مع زميله

الاسبوع	الساعات	مخرجات التعليم المطلوبة	اسم الوحدة	طريقة التعليم	طريقة التقييم
1-2	4ن+4ع	الطالب يفهم الدرس	Cells & Tissues	محاضرة نظرية	امتحانات اسبوعية اسئلة قبلية وبعدي
3	2ن+2ع	الطالب يفهم الدرس	The integumentary system	محاضرة نظرية	امتحانات اسبوعية اسئلة قبلية وبعدي
4	2ن+2ع	الطالب يفهم الدرس	The skeletal system	محاضرة نظرية	امتحانات اسبوعية اسئلة قبلية وبعدي
6-5	4ن+4ع	الطالب يفهم الدرس	Articulations	محاضرة نظرية	امتحانات اسبوعية اسئلة قبلية وبعدي
7	2ن+2ع	الطالب يفهم الدرس	The muscular system.	محاضرة نظرية	امتحانات اسبوعية اسئلة قبلية وبعدي
8	2ن+2ع	الطالب يفهم الدرس	Nervous tissue.	محاضرة نظرية	امتحانات اسبوعية اسئلة قبلية وبعدي
9	2ن+2ع	الطالب يفهم الدرس	Central nervous system	محاضرة نظرية	امتحانات اسبوعية اسئلة قبلية وبعدي
10	2ن+2ع	الطالب يفهم الدرس	Autonomic nervous system	محاضرة نظرية	امتحانات اسبوعية اسئلة قبلية وبعدي

12-11	4ن+4ع	الطالب يفهم الدرس	Sensory, motor and integrative functions	محاضرة نظرية	امتحانات اسبوعية اسئلة قبلية وبعدي
13	2ن+2ع	الطالب يفهم الدرس	The endocrine system.	محاضرة نظرية	امتحانات اسبوعية اسئلة قبلية وبعدي
15-14	4ن+4ع	الطالب يفهم الدرس	The cardiovascular system: Blood.	محاضرة نظرية	امتحانات اسبوعية اسئلة قبلية وبعدي

امتحانات اسبوعية اسئلة قبلية وبعدي	محاضرة نظرية	The cardiovascular system: the heart.	الطالب يفهم الدرس	ع4+ن4	17-16
امتحانات اسبوعية اسئلة قبلية وبعدي	محاضرة نظرية	The cardiovascular system: Blood vessels.	الطالب يفهم الدرس	ع4+ن4	19-18
امتحانات اسبوعية اسئلة قبلية وبعدي	محاضرة نظرية	The lymphatic system and immunity	الطالب يفهم الدرس	ع4+ن4	21-20
امتحانات اسبوعية اسئلة قبلية وبعدي	محاضرة نظرية	the respiratory system	الطالب يفهم الدرس	ع4+ن4	23-22
امتحانات اسبوعية اسئلة قبلية وبعدي	محاضرة نظرية	The digestive system.	الطالب يفهم الدرس	ع4+ن4	25-24
امتحانات اسبوعية اسئلة قبلية وبعدي	محاضرة نظرية	Metabolism	الطالب يفهم الدرس	ع2+ن2	26

امتحانات اسبوعية اسئلة قبلية وبعدي	محاضرة نظرية	The urinary system.	الطالب يفهم الدرس	ع2+ن2	27
امتحانات اسبوعية اسئلة قبلية وبعدي	محاضرة نظرية	Fluid, electrolyte and Acid – Base balance.	الطالب يفهم الدرس	ع4+ن4	29-28
امتحانات اسبوعية اسئلة قبلية وبعدي	محاضرة نظرية	The reproductive system.	الطالب يفهم الدرس	ع2+ن2	30

إرشادات للطلبة

- الرغبة والحماس للتعليم
- كن مشاركاً في جميع الأنشطة
- احترم أفكار المدرس والزملاء

- أنقد أفكار المدرس والزملاء بأدب إن كانت هناك حاجة.
- احرص على استثمار الوقت
- تقبل الدور الذي يسند إليك في المجموعة
- حفز أفراد مجموعتك في المشاركة في النشاطات
- احرص على بناء علاقات طيبة مع المدرس والزملاء أثناء المحاضرة
- احرص على ما تعلمته في المحاضرة وطبقه في الميدان .
- ركز ذهنك بالتعليم و احرص على التطبيق المباشر
- تغلق الموبايل قبل الشروع بالمحاضر

المحاضرة الأولى - الزمن: 120 دقيقة

أهداف المحاضرة الاولى:

يتوقع في نهاية الجلسة أن يكون الطالب قادراً على معرفة ما هي خلايا الجسم بصورة عامه و وظائفها.

موضوعات المحاضرة الاولى:

Cells & Tissues

الأساليب والأنشطة والوسائل التعليمية

م	الأساليب والأنشطة التدريبيه	الوسائل التدريبيه
1	<ul style="list-style-type: none"> • نشاط التعارف • محاضرة • مناقشة • سؤال وجواب 	<ul style="list-style-type: none"> • وسائل ايضاح • جهاز عرض • سبورة • اوراق واقلام

خطة إجراءات تنفيذ المحاضرة الاولى

الوحدة	المحاضرة	الإجراءات	الزمن بالدقيقة
الأولى	الأولى	<ul style="list-style-type: none"> الترحيب بالطلبة والتعارف معهم التعريف بالبرنامج وأهدافه وأهميته والبدء باعطاء المادة العلمية للمحاضرة 	120 دقيقة

المادة العلمية:

Anatomy: **Is the study of structure; and examine the relationships among parts of the body along with the structure of individual organs.**

It is a Greek word means **“ to cut up “**

The science that studies the function of body structures is called **“ physiology”**.

Subdisciplines of anatomy

Generally into two categories ,

- **Microscopic Anatomy** : structures not visible to the unaided eye

- **Cytology** : (cells)

- **Histology** : (tissues)

- **Macroscopic Anatomy** : observed by unaided eye Organs (ex : Stomach , brain , heart ...)

Structural Organization of the body :

The simplest level of **organization within the body is the chemical level (composed of Atoms and molecules)**.

The **Atoms** are the smallest units , two or more atoms combined to form a molecule such as (**protein , water molecule**)

Larger molecules joins to form cells (cellular level). Groups of similar cells with a common function form the tissue. (tissue level) . **Different tissue types are combined to form an organ such as (lungs , stomach , heart) (organ level)**

Related organs that work together to coordinate activities and achieve a common function (Organ system level).

The cell

Cells are the structural and functional units of all living organisms

. **They are the building blocks of the human body. An adult human body contains about 75 trillion cells. There are approximately 200 different cell types in human body.**

- All cells share some **common characteristics :**

1- all cells perform the general functions necessary to sustain life. (each cell must obtain nutrients and other materials essential for survival)

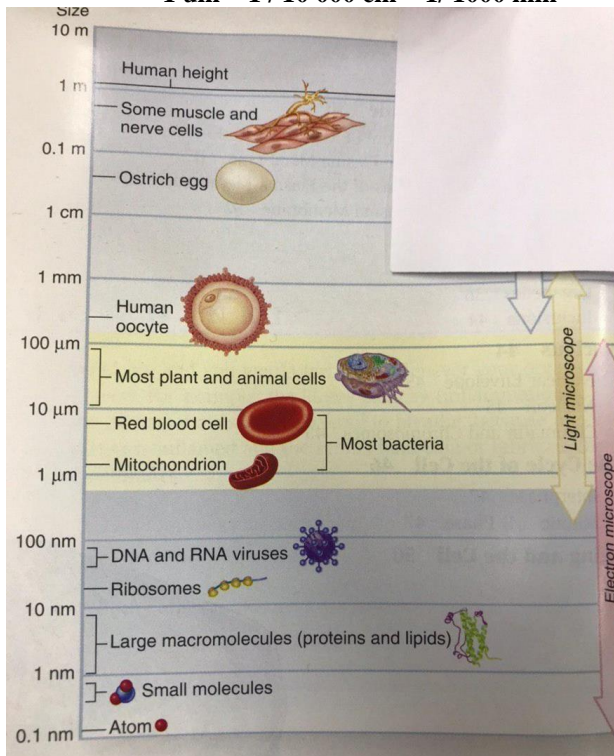
2- cells must dispose of the wastes they produce .

3- the shape and integrity of the cell is maintained by both its internal contents and its surrounding membrane .

-The study of cells is called **Cytology**.

cells were discovered after microscopes were invented, and high magnification microscopes are required to see the smallest human body cells. The unit of measurement often used to measure cell size is the micrometer (μm).

$$- 1 \mu\text{m} = 1 / 10\,000 \text{ cm} = 1 / 1000 \text{ mm}$$

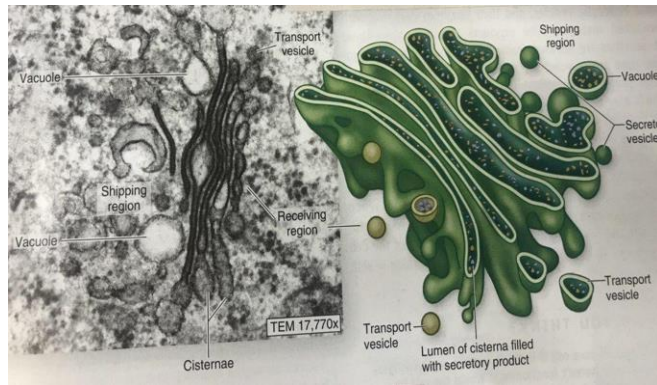


The use of microscopy has become a valuable asset in anatomic investigations . Most commonly used are the light microscope (LM) , the transmission electron microscope (TEM) and the scanning electron microscope (SEM) .

Is differ in both size and shape. The shapes may be flat, cylindrical, oval, or quite irregular .

Functions of cells :

- 1- Covering :** such as skin cells over the external body surface.
- 2- Lining :** Epithelial cells line the internal surfaces of our organs, such as the small intestine .
- 3- Storage :** Some body cells , such as fat cells (adipocytes), store nutrients or energy reserves for the body.
- 4- Movement :** Muscle cells that contracts allowing movement to occur. Also muscle cells in the heart wall contract and pump blood throughout the body.
- 5- Connection :** Multiple cell types are found in connective tissues , which help connect and support other tissues.(like cells found in ligament)
- 6- Defense :** protect the body against pathogens or antigen . White blood cells (called leukocytes) are designed to recognize antigens and attack them.
- 7- Communication:** Nerve cells (called neurons) transmit nerve impulses from one part of the body to another.
- 8- Reproduction :** Some cells are designed solely to produce new cells. For example, within the bone marrow are stem cells that continuously produce new blood cells for the body.



- Cytoplasm

Is a nonspecific term for all of the materials contained between the plasma membrane and the nucleus . The cytoplasm include three separate parts: Cytosol , organelles (except nucleus) , inclusion.

Cytosol : (cytoplasmic matrix or intracellular fluid)

Is a viscous fluid medium with dissolved solutes (ions, nutrients, proteins, carbohydrates, lipids, others)

Function : provides support for organelles; serves as viscous medium through which diffusion occurs .

Organelles :

Are complex , organized structures with unique, characteristic shapes. Each type of organelle performs a different function for the cell. And divided into (membrane bound and non membrane bound organelles)

brane – bound organelles : (surrounded by a membrane) 1- Rough endoplasmic reticulum (rough ER) :

Flattened intracellular network of membrane sacs called cisternae; ribosomes attached on cytoplasmic surface.

2- Smooth endoplasmic reticulum (smooth ER):

Interconnected network of membrane tubules and vesicles; no ribosomes

Function of endoplasmic reticulum :

1- Synthesis :

- Rough ER : synthesizes proteins for secretion, plasma membrane and lysosomes
- Smooth ER : is the site of lipid synthesis and carbohydrates metabolism

2- transport : move molecules from one part of the cell to another.

3- Storage : stores newly synthesized molecules

4- Detoxification: smooth ER detoxifies both drugs and alcohol

3- Golgi apparatus :

Also called Golgi complex , composed primarily of a series of cisternae , which are arranged in stack.

Function :

- 1- Modification : modifies new plasma membrane**
- 2- Packaging : packages protein for secretion and enzymes for lysosomes**
- 3- Sorting : sorts all materials for plasma membrane, secretion and lysosomes.**
- 4- Lysosomes :**

Are membrane sacs formed by Golgi apparatus. Contains enzymes used by the cell to digest waste products and ingested macromolecules. Sometimes referred to “garbagemen” of the cell .

Function :

- 1- Digestion (Microbes , solutes , special molecules)**
- 2-Removal : worn out or damaged organelles and cellular components; recycle small molecules for resynthesis (autophagy)**
- 3- Self – destruction : digest the remains after cellular death.**

5- Peroxisomes :

Are membrane enclosed sacs that are usually smaller in diameter than lysosomes .

Function : detoxify harmful substances , convert hydrogen peroxide into water

6- Mitochondria :

Are organelles with a double membrane that are involved in producing large amounts of the cell’s energy (ATP).

For this reason they are called the “ powerhouses “ of the cell.

The number of mitochondria in a cell depends upon the cell’s energy needs. Because it can self-replicate , the numbers are reater in cells that have a high energy demands.(ex in muscle cells).

Non membrane bound organelles :

1- Ribosomes :

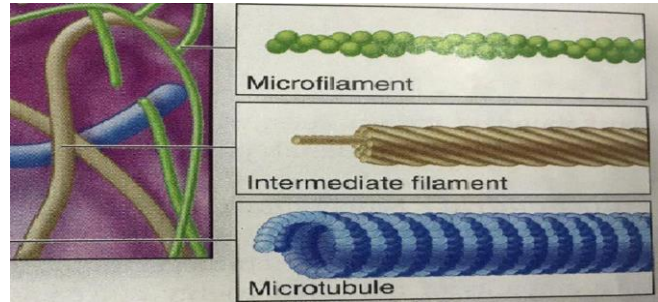
Are very small , dense granules that are responsible for protein production (synthesis).

They may be free in cytoplasm (free ribosomes) or bound to rough ER (fixed ribosomes) .

2- Cytoskeleton :

Is composed of protein subunits organized either as filaments or hollow tubes . Has three separate components :

- **Microfilaments (7 nm in diameter)(the smallest component)**
- **Intermediate filaments (8-12 nm)**
- **Microtubules (~ 25 nm)**



Function :

- Structural support of cell
- Organelle movement and cell motility
- Cytosol streaming

3- Centrosome :

Are closely adjacent to the nucleus in most cells .

Function : microtubule organization

4- Cilia and Flagella :

Are projections extending from the interior of cell.

They are composed of cytoplasm and supportive microtubules and they are enclosed by plasma membrane.

Function : move fluid , mucus, and dissolved material over some exposed cell surfaces (ex, respiratory cells movement of mucin toward the throat)

5- Microvilli :

Are thin microscopic projection extending from the surface of the plasma membrane . They are much smaller than cilia, much more densely packed together, and do not have powered movement.

Main function : increase membrane surface area for increased absorption and/ or secretion.

C- The Nucleus :

It is the control center of cellular activity. Usually, it is the largest structure within the cell and appears as a single spherical or oval structure .average size (5 μm - 7 μm). Generally its shape mirror the shape of cell.

The nucleus houses deoxyribonucleic acid (DNA), an enormous macromolecule that contains the genetic material of the cell.

DNA is organized into discrete units called Genes.

When a cell is not dividing, the DNA is in the form of chromatin (finely filament). Once the cell begins to divide , the chromatin rearranges itself in more precise and identifiable elongated structures called chromosomes .

the nucleus contains three basic structures:

1- Nuclear Envelope :

double membrane boundary between cytoplasm and nuclear content . Contains pores that regulate exchange of materials with the cytoplasm.

2- Nucleolus (pl. Nucleoli)

The cell nucleus may contain one or more nucleoli . Are responsible for making the small and the large subunits of ribosomes . Which are composed of both ribonucleic acid (RNA) and protein.

3- Chromatin and Chromosomes :

Filamentous association of DNA and protein.

الوحدة الثانية - المحاضرة الثانية - الزمن: 120 دقيقة

أهداف المحاضرة الثانية:

يتوقع في نهاية الجلسة أن يكون الطالب قادراً على معرفة ماهو tissues واستخداماته وانواعه

موضوعات المحاضرة الثانية:

Tissue

الأساليب والأنشطة والوسائل التعليمية

الوسائل التدريبيه	الأساليب والأنشطة التدريبيه	م
<ul style="list-style-type: none">• جهاز حاسوب• جهاز عرض• سبورة• اوراق واقلام	<ul style="list-style-type: none">• محاضرة• مناقشة• سؤال وجواب	2

المادة العلمية:

Tissues

Tissue: - A group of similar cells specialized to perform a set of function.

There are 4 types of tissues: -

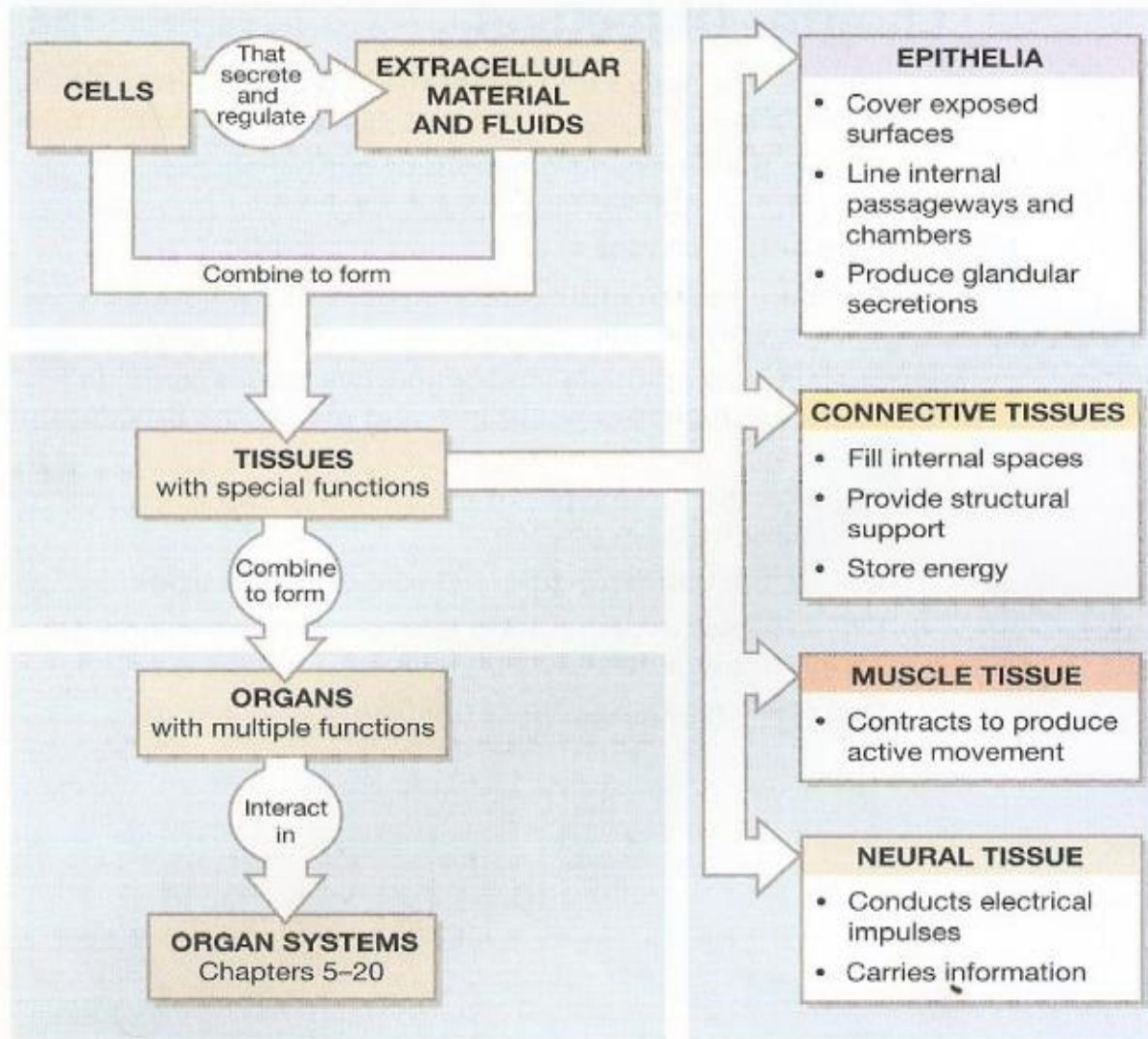
- 1- Epithelial
- 2- Connective
- 3- Muscle
- 4- Neural tissue.

The human body is composed of only four basic types of tissue:

- 1.** Epithelial tissue (lines body surface and cavities)
- 2.** Connective tissue is characterized by the abundant extracellular matrix “ECM” produced by its cells.
- 3.** Muscular tissue is composed of elongated cells specialized for contraction and movement.

4. Nervous tissue is composed of cells with long, fine processes specialized to receive, generate, and transmit nerve impulses.

These tissues, which all contain cells and molecules of the extracellular matrix (ECM), exist in association with one another and in variable proportions and morphologies, forming the different organs of the body .



● **FIGURE 4-1** An Orientation to the Tissues of the Body.

↳ The stroma, the cells of which have a supporting role in the organ.(blood vessels ,nerves ...)

Epithelial tissue

● **Contain:** -

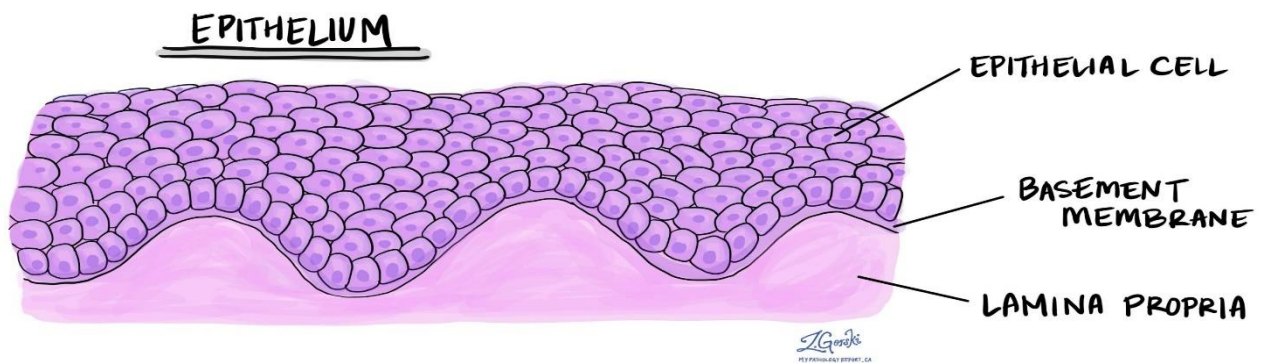
1-**Epithelia:** - Are layers of cells that cover internal or external surface. (Line the cavities of organs and cover the body surface)

2- **Gland:** - Composed of secreting cells derived from epithelia.

The principal functions of epithelial tissues include the following:

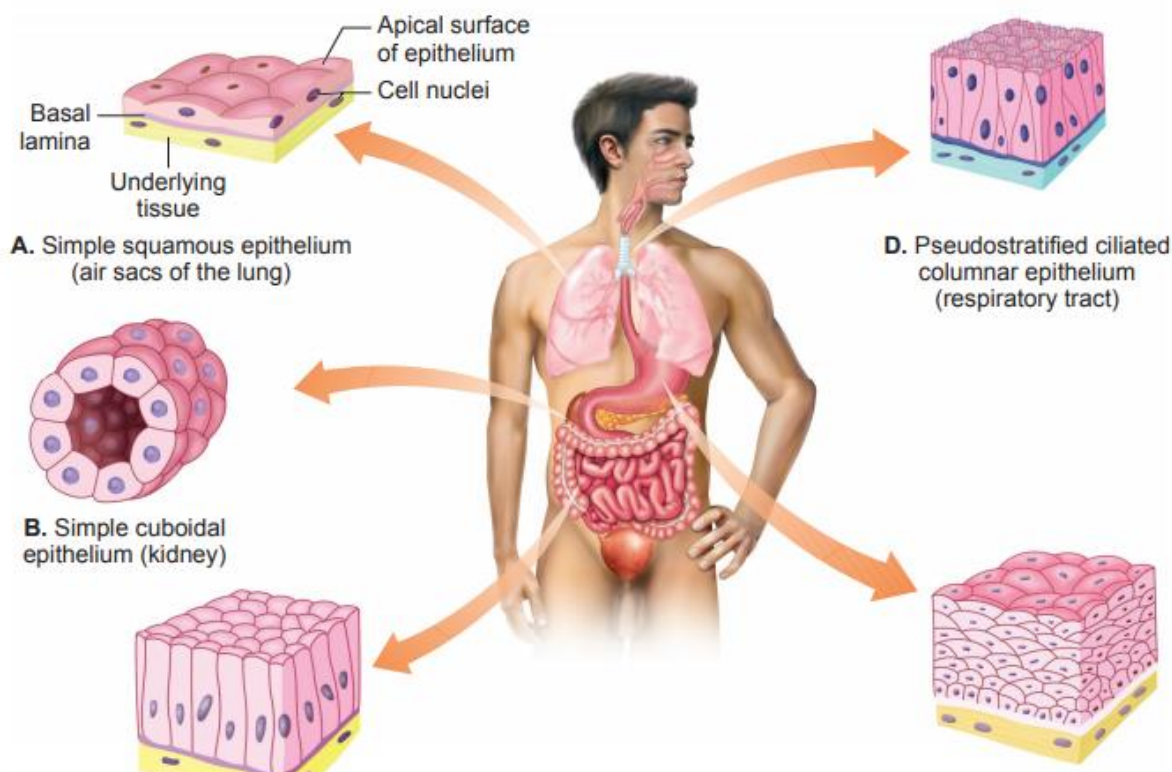
-Characteristic of epithelia

- 1- Cells are bound closely together **Cellularity**
- 2- A free (apical) surface exposed to external and internal environment.
- 3- Attachment to underlying connective tissue by a basement membrane.
- 4- The absence of blood vessels (avascular). nutrients for epithelial cells are obtained either directly across the apical surface or by diffusion across the basal surface from the underlying connective tissue(CT)
- 5- Epithelial surface cells continually replaced or regenerated, Epithelial cells survive for the short period (1-2 days) so it should replace by division of stem cells, or germinative cells.
- 6- innervation : some epithelia are richly innervated to detect changes in the environment at that body or organ surface , most nervous tissue is in the underlying CT.

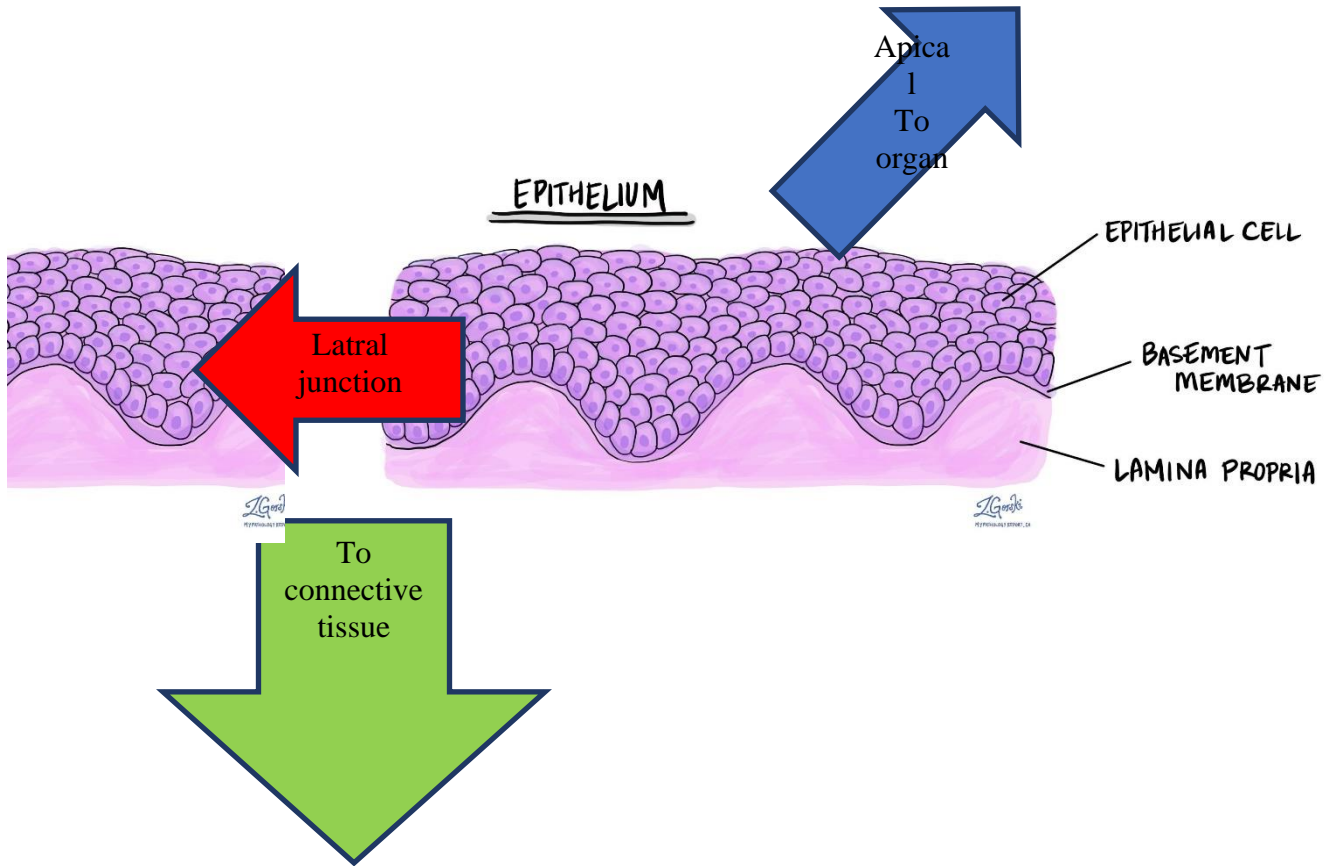


-Function of epithelial tissue

- Provide physical protection Covering, lining, and protecting surfaces (e.G., Epidermis) .protection from dehydration , abrasion and destruction by physical , chemical or biological agents.
- Absorption ,Control permeability (e.G. The intestinal lining).
- Provide sensation: Specific cells of certain epithelia may be contractile (myoepithelial cells) or specialized sensory cells, such as those of taste buds or the olfactory epithelium.
- Secretion ,Produce specialized secretion (e.G. Parenchymal cells of glands).
1- exocrine 2-endocrine



The apical surface is the free surface of the cell exposed to a body cavity , an organ lumen , or the exterior of the body. The basal surface (bottom) is where the epithelium is attached to the underlying connective tissue.
the lateral surfaces of all cell contain intercellular junctions.



Types of intercellular junction are :

1- tight junction

2- adhering junction

3- Desmosomes

4- gap junctions

(function of these junctions : some prevent corrosive enzymes from moving between epithelial cells, some afford a passage way for material. Holds cell together and provide to mechanical stress).

The epithelial surface • Contain:-

• Microvilli: - increase surface area by 20 time.

• Cilia: - beating in one way to move material across the epithelial surface (some cell contains 250 cilia)

types of epithelium

Epithelia can be divided into two main groups :

1- covering (or lining) epithelia.

2- secretory (glandular) epithelia.

1- covering (or lining) epithelia .

- Simple epithelia contain one cell layer.

- Stratified epithelia contain two or more layers. Based on cell shape, simple epithelia are classified as:

1- Squamous (thin cells). (=scaly)(flat,wide, irregular)

2- Cuboidal (cell width and thickness roughly similar).

3- Columnar (cells taller than they are wide)

4- Transitional (cells can readily change their shape or appearance depending upon how stretched the epithelium becomes (like the bladder (.

Most stratified epithelia are classified according to the cell shape of the superficial layer(s): squamous, cuboidal, or columnar.

2- Secretary epithelia and glands:

Types of secretory epithelial cells

Secretory epithelial cells may synthesize, store, and release :

- 1-** Proteins (e.G., In the pancreas) .
- 2-** Lipids (e.G., Adrenal, sebaceous glands).
- 3-** Complexes of carbohydrates and proteins (e.G., Salivary glands) .
- 4-** Epithelia of mammary glands secrete all three substances.
- 5-** The cells of some glands (e.G., Sweat glands) have little synthetic activity and secrete mostly water and electrolytes (ions) transferred from the blood.
- 6-** Scattered secretory cells, sometimes called unicellular glands, are common in epithelia of many organs. An example is the goblet cell abundant in the lining of the small intestine and respiratory tract, which secretes lubricating mucus that aids the function of these organs.

Exocrine glands

Secretion through a duct system.

The structure of the secretory portions and ducts allows exocrine glands to be classified as :

- 1-** Glands can be:
 - A)** simple (ducts not branch) .
 - B)** compound (ducts with two or more branches.)
- 2-** Secretory portions can be:
 - A)** tubular (either short or long and coiled).
 - B)** acinar (rounded and sac like).

Either type of secretory unit may be branched, even if the duct is not branched.

- 3-** Compound glands can have branching ducts and can have multiple tubular, acinar, or tubuloacinar secretory portions.

Secretion types:

Glands are classified by the nature of their secretions as:

- 1-** serous glands: nonviscous , watery fluid such as sweat , milk , tears and digestive juices
- 2-** mucous glands : secrete mucin , which form mucous when mixed with water (ex.Oral cavity)
- 3-** mixed glands : of the two types of secretion (like two pairs of salivary glands)

Secretion methods

- 1-** merocrine glands (eccrine) package their secretion into secretory vesicles then release it by exocytosis. Example : tear gland, salivary gland , some sweat glands , gastric glands and exocrine gland of pancreas.
- 2-** holocrine : cells that accumulate a product , then entire cell disintegrate (like sebaceous glands = oil producing glands)
- 3-** apocrine glands : include the mammary glands and some sweat glands in axillary region (armpit).

Endocrine glands

Lack ducts and secrete their products directly into interstitial fluid and blood stream. The secretion is called hormones.

Connective tissue (CT)

Is the most diverse , abundant, widely distributed and microscopically variable of the tissues. Is designed to support, protect and bind organs . it is the “glue” that binds body structure together.

Connective tissue includes :

fibrous tendons , ligaments , body fat , the cartilage , bones of skeleton and the blood.

All types of CT share three basic components:

Cells ,, Protein fibers ,, Ground substance

Function of CT:

- 1-** physical protection : bones
- 2-** support and structural framework : cartilage support like in trachea , bronchi , ear.
- 3-** binding of structures : ligaments (bind bone to bone)
- 4-** storage : fat (major energy reserver)
- 5-** transport :blood
- 6-** immune protection : many ct contained wbc .(white blood cells)
 - Have receptor for “pain, pressure, temperature

4-Muscle tissue

- It is specialized for contraction.
- Muscle cell contraction involves interaction between filaments of myosin and actin proteins.
- There are three types of muscle tissue:
 - skeletal , 2- cardiac, 3- smooth M.T.
- They have the same contraction mechanism, but differ by their actin & myosin organization.

-skeletal muscle tissue •

- Contain large , long and thin muscle cells called muscle fibers.
- Muscle fibers are multinucleated with peripheral location.
 - Muscle fibers have a striped appearance “striations”.
 - Muscle fibers contraction controlled by voluntary nervous system, so it considered striated voluntary muscle.
 - Attached to the bone skeleton.

Cardiac muscle cell

- Found only in the heart.
- Striated with single central nucleus , smaller than a skeletal muscle
- Cardiac muscle branch and interconnected by intercalated disc, its specialized attachment sites contain gap junction and desmosomes.
- Specialized cells, called pacemaker cells, establish a regular rate of contraction.
- Its involuntary muscle.

smooth muscle tissue

- Found in the wall of blood vessels and the hollow organs.
- The smooth muscle cell is small, spindle shape with single central nucleus
- Not striated.
- Involuntary contraction.
- Smooth muscle cell can divide

-Neural tissue(NT) —

98% of NT presents in brain and spinal cord, and the control centers for the nervous system.

— It is specialized for conduction of electrical impulses from one region of the body to another . — Consist from neurons “conduct electrical impulse”, and neuroglia.

Neuroglia serve for:-

- 1- physical protection.
- 2- maintain the chemical composition of the tissue fluids.
- 3- supply nutrient to neurons.
- 4- defend the tissue from infection.

Typical neuron has:-

cell body, containing large nucleus.

- **dendrites**, numerous projection from the body received information from other cells.

- **axon**, long and slender “nerve fiber” projection carry information to other cells,

and end with synaptic terminals by it communicate with other cells

الوحدة الثالثة - المحاضرة الثالثة - الزمن: 120 دقيقة

أهداف المحاضرة الثالثة:

يتوقع في نهاية الجلسة أن يكون الطالب قادراً على معرفة ماهو **the integumentary system** ووظائفه.

موضوعات المحاضرة الثالثة:

the integumentary system

الأساليب والأنشطة والوسائل التعليمية

الوسائل التدريبية	الأساليب والأنشطة التدريبية	م
• جهاز حاسوب • جهاز عرض • سبورة • اوراق واقلام	• محاضرة • مناقشة • سؤال وجواب	3

المادة العلمية:

The integumentary system is the **set of organs** that forms the **external covering of the body** and **protects it** from many threats such as infection, desiccation, abrasion, chemical assault and radiation damage.

This system is divided into:

- 1- skin
- 2- hair
- 3- glands
- 4- nails
- 5- nerve endings

The scientific study and treatment of the integumentary system is called **Dermatology**

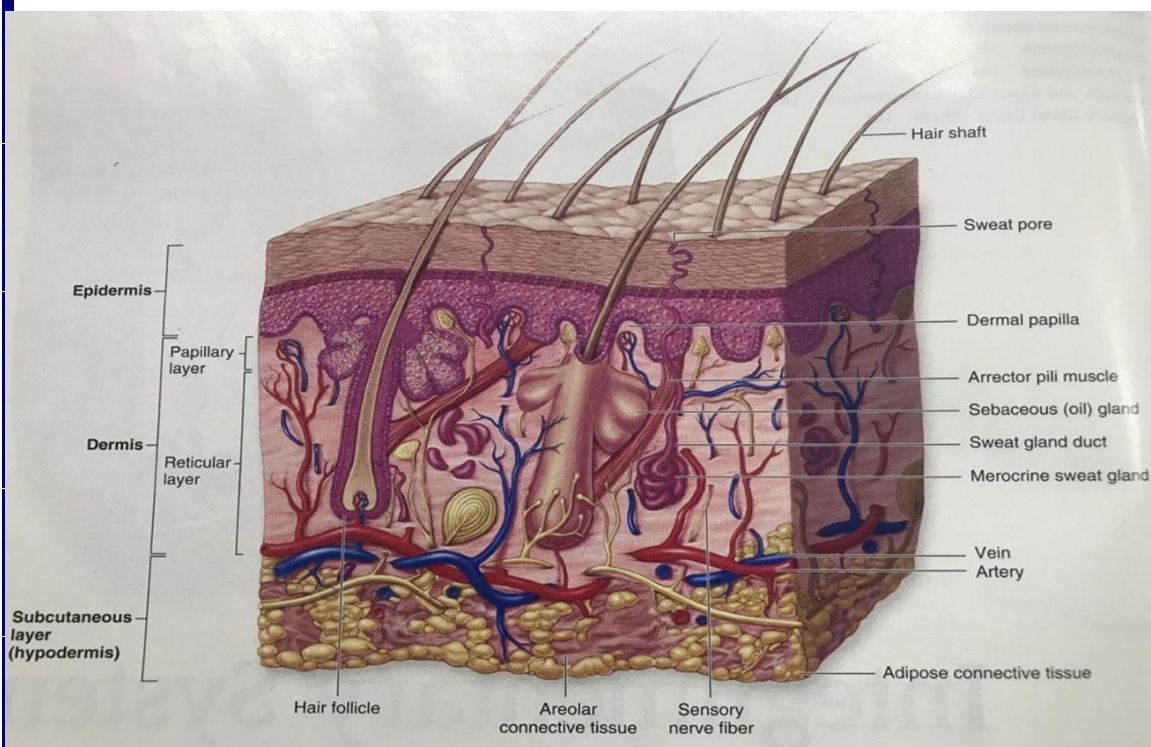
Skin is an organ because it **consists of different issues** that are joined to perform a specific function. & is the **largest organ** of the body in surface area and weight.

Anatomy (structure)

a- Epidermis (**thinner outer** layer of skin).

b- Dermis (**thicker** connective tissue layer).

c- Hypodermis (**subcutaneous** layer).



Physiology (function)

1- Protection: Is a **physical** barrier that protects underlying tissues from injury, UV light and bacterial invasion. Is a **mechanical barrier** being part nonspecific immunity (skin, tears and saliva) .

2- Regulation of body temperature: In case of high temperature or strenuous exercise; sweat is evaporated from the skin surface to cool the body down. The **vasodilation (increases blood flow)** and **vasoconstriction (decrease in blood flow)** actions regulates body temp.

3- Sensation: A vast number not equally distributed numbers of nerve endings and receptor cells that **detect stimuli to temp., pain, pressure and touch.**

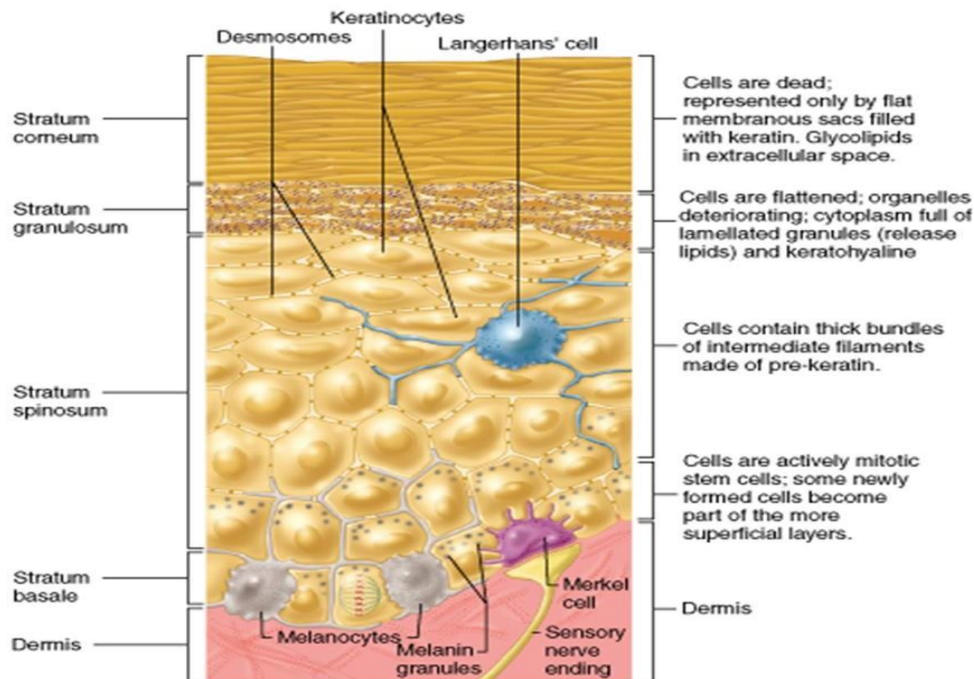
4- Excretion: The sweat removes water and small amounts of salt, uric acid and ammonia from the body surface

5- Blood reservoir: The dermis houses an extensive network of blood vessels carrying 8-10% of total blood flow in a resting adult. **Synthesis of Vitamin D** (cholecalciferol) UV rays in sunlight stimulate the production of Vitamin D. Enzymes in the kidney and liver modify it and convert to final form; calcitriol (most active form of Vitamin D.) Calcitriol aids in absorption of calcium from foods and is considered a hormone.

Epidermis

Is a **keratinized stratified squamous epithelium** with **four** distinct cell types and **five** distinct layers. It is a **vascular**, and it acquires its nutrient through diffusion from underlying dermis. **Cells in the epidermis:**

- 1- Keratinocytes.
- 2- Melanocytes.
- 3- Merkel cells.
- 4- Langerhans' cells.



1- Keratinocytes:(most abundant)

A keratinocyte is the **predominant cell type in the epidermis**, the outermost layer of the skin, constituting **90%** of the cells found there. Those keratinocytes found in the basal layer (**stratum basale**) of the skin are sometimes referred to as "**basal cells**" or "basal keratinocytes".

The fully cornified keratinocytes that form the outermost layer are constantly shed off and replaced by new cells.

keratin (fibrous protein): A tough, non-water-soluble protein found in the nails, hair, and the outermost layer of skin. Human hair is made up largely of keratin.

2- Melanocytes:

Are **melanin-producing cells** located in the bottom layer (the stratum basale) of the skin's epidermis, the middle layer of the **eye (the uvea)**, the **inner ear, meninges, bones,** and heart. it produce **melanin** (the primary determinant of **skin color**).

3- Merkel cells: (tactile cell) A cell that occurs in the basal part of the epidermis, and probably functions in **tactile sensory perception** providing information about **objects touching the skin**.

4- Langerhans' cells: (epidermal dendritic cells)

These are star-shaped cells arising from bone marrow that migrate to epidermis. They are epidermal dendritic cells (macrophages).

(immune cells help fight infection in epidermis). The epidermis is formed of **5 layers** which are:

1- Stratum corneum (horny layer)

Is the **outermost layer** of the epidermis, consisting of **dead cells (corneocytes)**. This layer is composed of 15-20 layers of flattened cells with no nuclei and cell organelles.

2- Stratum lucidum

Is a **thin,** clear layer of **dead skin cells** in the epidermis named for its **translucent** appearance under a microscope.

3- stratum granulosum

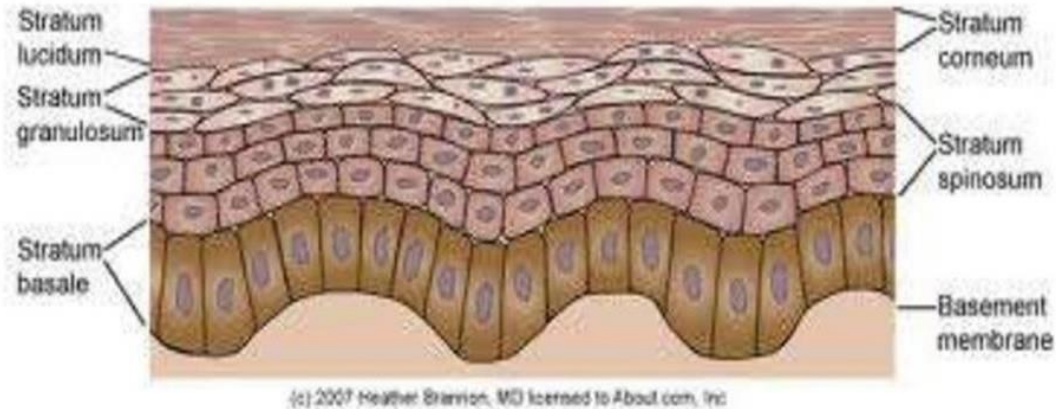
Is a 3-5 rows of flattened cells. Within this stratum begins a process called **keratinization**, by which keratinocytes filled with protein keratin.

4- Stratum spinosum: “spiny layer”

Is a layer of the epidermis found between the stratum granulosum and stratum basale.

is a 8-10 rows of polyhedral (many sided) cells. Stratum spinosum

The melanin granules and Langerhans’ cell predominate



5- Stratum basale: (stratum germinativum) Deepest epidermal layer

The stratum basale is a continuous layer of cells. It is often described as one cell thick, It is attached to dermis.

The stratum basale is primarily made up of basal keratinocyte cells (columnar keratinocytes) , which can be considered the stem cells of the epidermis it has a rapid mitotic division.

DERMIS

The dermis is the layer of **connective tissue** that **supports the epidermis and binds it to the subcutaneous tissue (hypodermis)**. The thickness of the dermis varies with the region of the body and reaches its maximum of 4 mm on the back.

It is composed of highly flexible and strong connective tissue made up of elastic, reticular and **collagen fibers**. other components of the dermis are **blood vessels, sweat glands, sebaceous glands, hair follicles, nail roots, sensory nerve ending and muscular tissue.**

The cells that are found are **fibroblasts, macrophages & mast cells.**

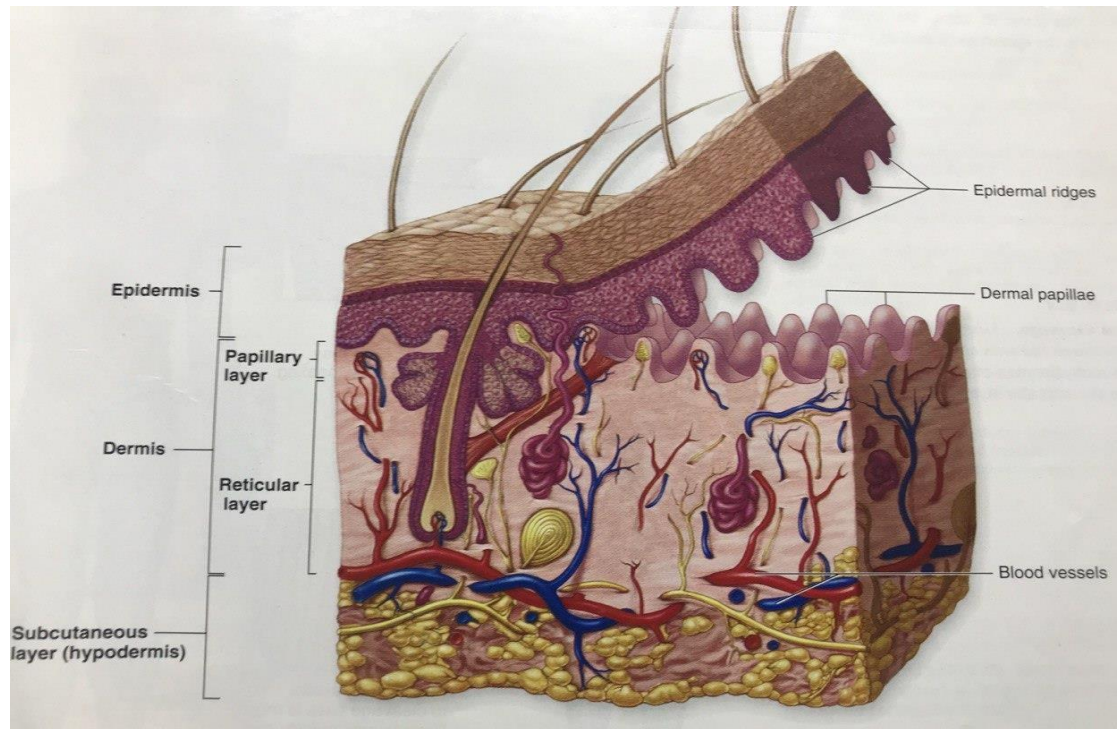
In the dermis there is nerves, blood and lymphatic vessels also oil and sweat glands originate.

The dermis is made up of two layers: **papillary** and

reticular

1- Papillary layer (superficial): contain capillaries and sensory receptors

2- Reticular layer (deep): consist of CT and collagen fibers ; contains hair follicles, sebaceous glands , sweat gland , nerves , blood vessels.



Function:

1- nutritive function

2- thermoregulatory function

The subcutaneous layer (hypodermis)

It consists of loose connective tissue that binds the skin loosely to the subjacent organs, making it possible for the skin to slide over them. This layer, also called the hypodermis or superficial fascia, contains adipocytes that vary in number in different body regions and vary in size according to nutritional state. The extensive vascular supply at the subcutaneous layer promotes rapid uptake of insulin or drugs injected into this tissue.

Skin color :

a from results color of skin Normal combination

hemoglobin , melanin and carotene. Hemoglobin present in RBC

(blood vessel is reddish)

Melanin (from melanocytes) affect the color of entire epidermis , darker skin have melanocytes produce more melanin than do those of lighter skin and the amount of melanin is determined by both hereditary and light exposure . **So expose to UV light both darkens melanin** and stimulate melanocytes to make more melanin.

Hair (pili)

The **main function is protection**, also in the hair root nerve plexuses for **touch**.

The normal hair loss in adult 10-100 hairs/day

Hair anatomy:

It is composed of dead columns of keratinized cells. **The shaft:** is the superficial portion of hair.

The root: below the surface in the dermis

Hair bulb : a swelling at base where the hair originates

- The hair **follicle** is an oblique tube that surrounds the hair.
- The **arrector pili muscle** (smooth muscle) is usually stimulated in response to an emotional state, such as fear or rage, exposure to cold temperatures .upon stimulation, the arrector pili contracts ,pulling on the follicles and elevating the hairs, producing “ goose bumps ‘

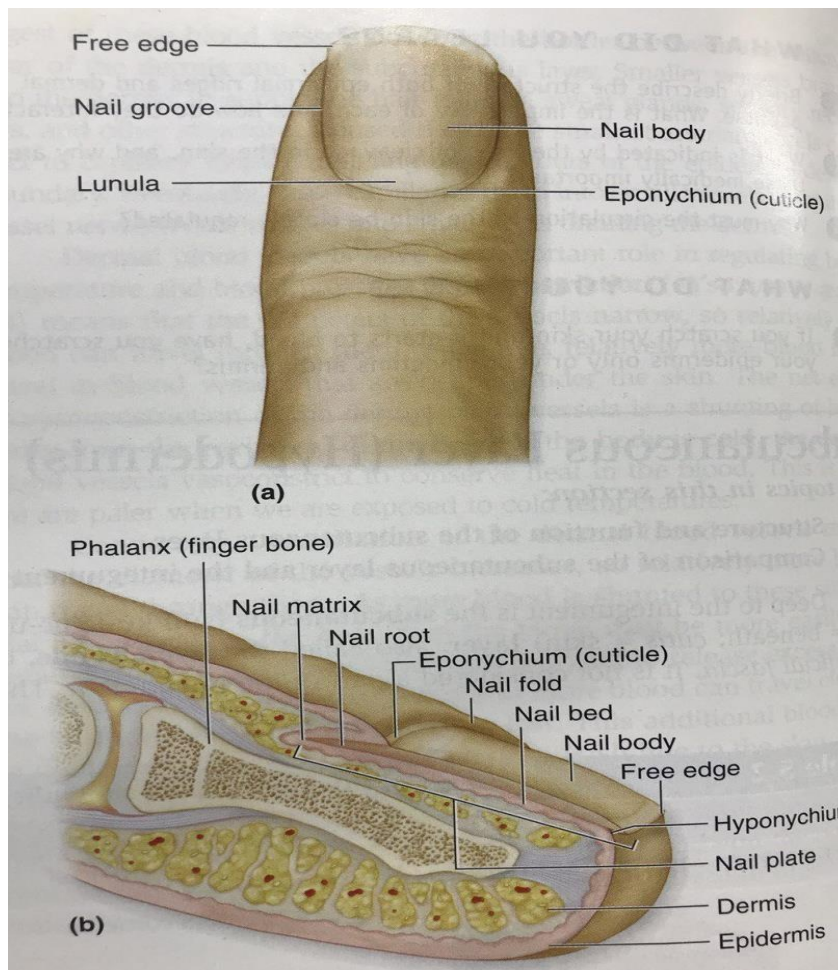
Nails :

Each nail has **a distal free edge** , the **whitish layer of the nail** ; a **nail body** , the **pinkish part of the nail** ; and a **nail root**, the **proximal part embedded in the skin**. Together these parts compose the nail plate.

The nail rests on a layer of epidermis called the nail bed, which contains only the deeper , living cell layers of epidermis. The body of nail covers the nail bed.

The nail matrix is a bed thickening , which is the actively growing part of the nail.

Eponychium (Cuticle) is a narrow band of epidermis that extends from margin of the nail wall onto the nail body.



Glands

Two types of glands exist in the integument.

- **Sebaceous glands** (oil glands)

- **Sudoriferous glands** (sweat glands)

Sebaceous glands: (holocrine)

It is connected to hair follicle & it secretes sebum (fats, cholesterol and proteins to keep hair from drying out, keeps skin moist. These glands are not found on palms and soles of feet.

Sudoriferous glands: exocrine glands

There are two types of sweat glands, eccrine and apocrine, with distinct functions, distributions, and structural details.

1) Eccrine sweat glands

Are widely distributed in the skin and are most numerous on the foot soles.

Sweating is a physiologic response to increased body temperature during physical exercise or thermal stress and is the most effective means of temperature regulation of humans. Sweat is watery (99% H₂O). Sweating regulated by sympathetic nervous system.

2) Apocrine sweat glands

Are largely confined to skin of the axillary and perineal regions. Their development depends on sex hormones and is not complete and functional until after puberty. The secretory components of apocrine glands have much larger lumens than those of the eccrine glands

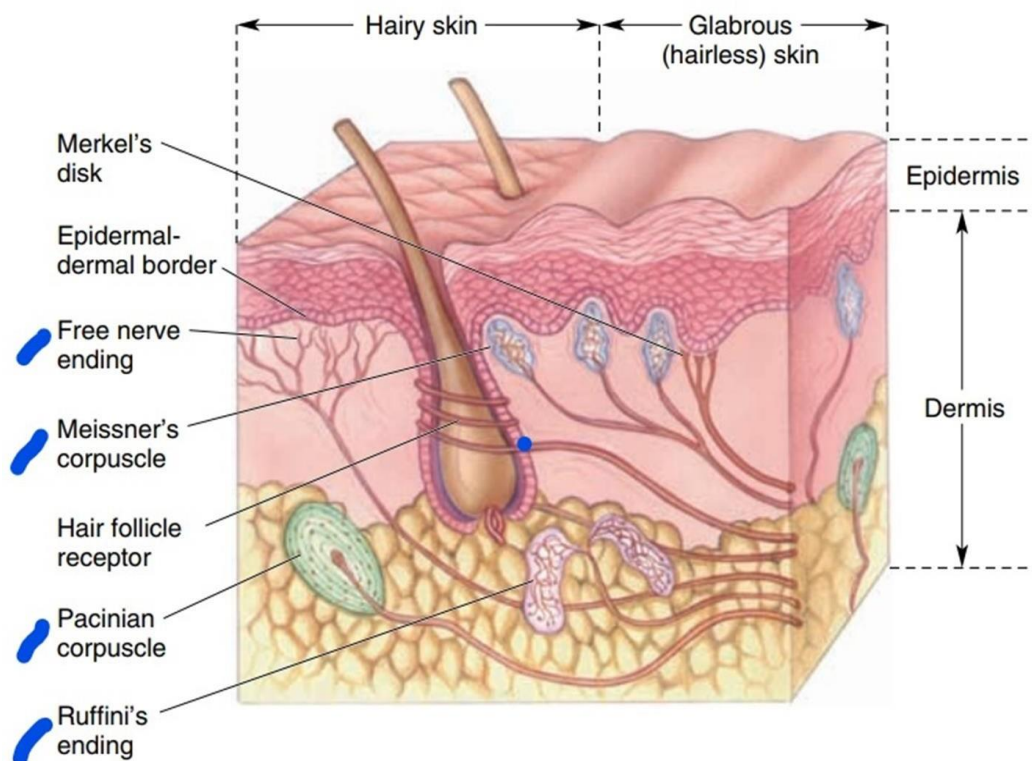


FIGURE 5.12. Anatomic Structure of Certain Cutaneous Receptors

الوحدة الرابعة - المحاضرة الرابعة - الزمن: 120 دقيقة

أهداف المحاضرة الرابعة:

يتوقع في نهاية الجلسة أن يكون الطالب قادراً على معرفة ماهو skeleton و اجزاءه.

موضوعات المحاضرة الرابعة:

skeleton

الأساليب والأنشطة والوسائل التعليمية

الوسائل التدريبية	الأساليب والأنشطة التدريبية	م
• جهاز حاسوب • جهاز عرض • سبورة • اوراق واقلام	• محاضرة • مناقشة • سؤال وجواب	4

المادة العلمية:

The skeletal system

The framework of the body consist of **bones and other connective tissues** , which **protect and supports the body** tissues and internal organs .

The human skeleton contains **206 bones** , six of which are **tiny bones of the middle ear (three in each ear)** that function in hearing.

Parts of skeletal system : 1- Bones

(skeleton)

2- Joints

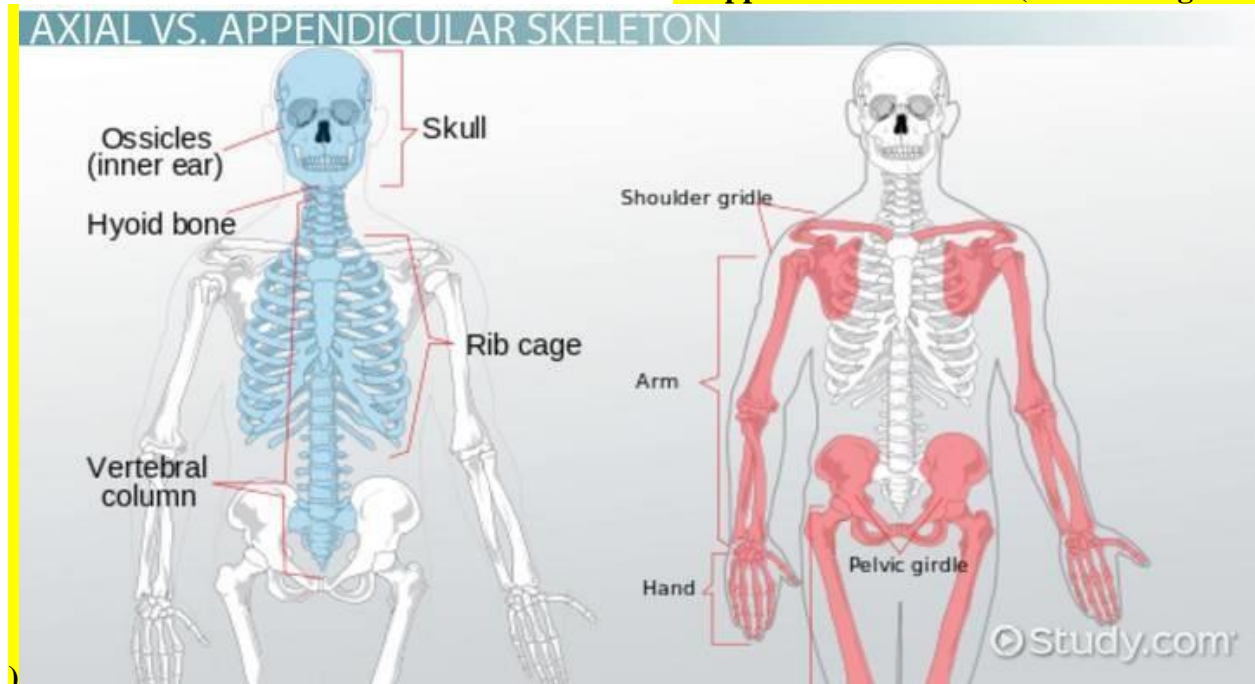
3- Cartilages

4- Ligaments (bone to bone) , tendons (muscle to bone)

Divided into two divisions 1- Axial

skeleton

2- Appendicular skeleton (limbs and girdle)



Function of bones :

- 1- Support the body
- 2- Protection of soft organs
- 3- Movement due to attached skeletal muscles
- 4- Storage of minerals and fats (like calcium , phosphate)
- 5- Blood cell formation

Bones of the human body

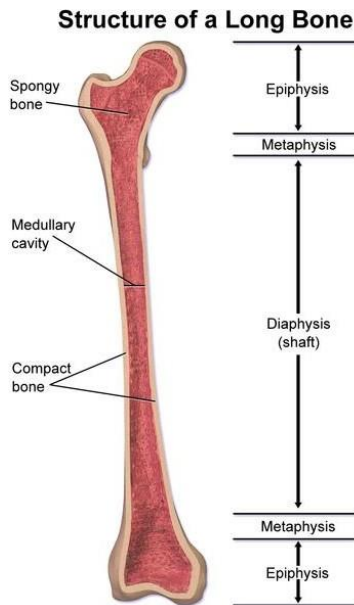
There are two basic types of bone tissue

- 1- Compact bone (cortical bone)

Hard exterior of bone , outer layer , heavy in nature , forms the diaphysis of long bones

2- Spongy bone (cancellous bone)

The interior cavity of bone (trabecular bone) , inner layer , spongy , light and soft in nature , forms the epiphysis (ends)of long bones.



Bone cells

1- Osteoblasts :

These are responsible for **making new bone** and repairing older bone .

2- Osteoclasts :

These are large cell which release enzymes and acids to dissolve minerals in bone and **digest them** ; this process called **resorption**.

Classification of bones : 1- Long

bones :

Longer than wider , they have a shaft with heads at both ends and include mostly compact bone , ex : femur bone , humerusbone

2- Short bones :

Generally cube shaped , they contain mostly spongy bone . ex : carpal and tarsal bones .

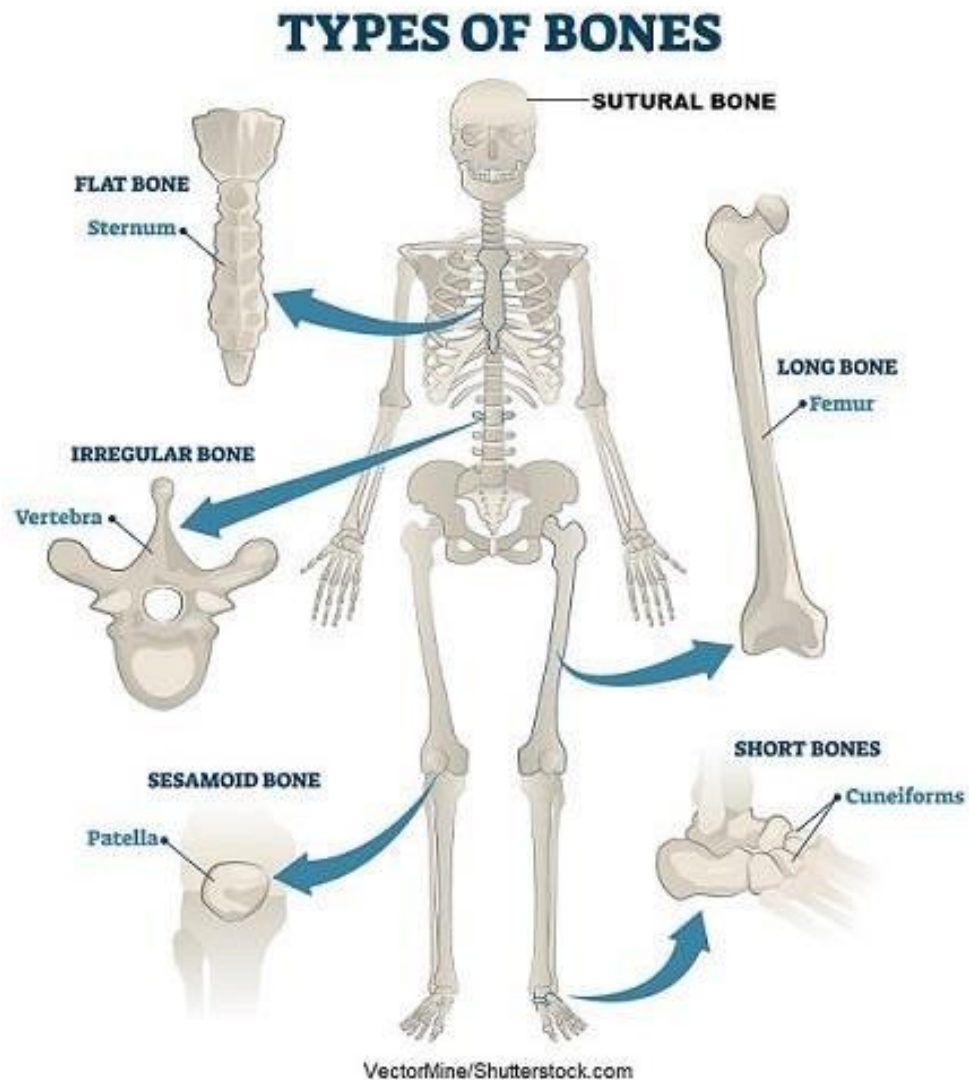
3- Flat bones :

Thin and flattened , they are usually curved , thin layers of compact bone around a layer of spongy bone , ex : skull (cranial) bones , ribs , sternum .

4- Irregular bones :

Irregular shape , do not fit into other bone classification categories , ex : vertebrae , sacrum

Another type of bone called : Sesamoid bone (bones embedded in tendons - ex: patella).



The axial skeleton

Forms the longitudinal part of the body and its divided into 3 parts :

1- Skull (cranial)and its associated bones

2- Vertebral column

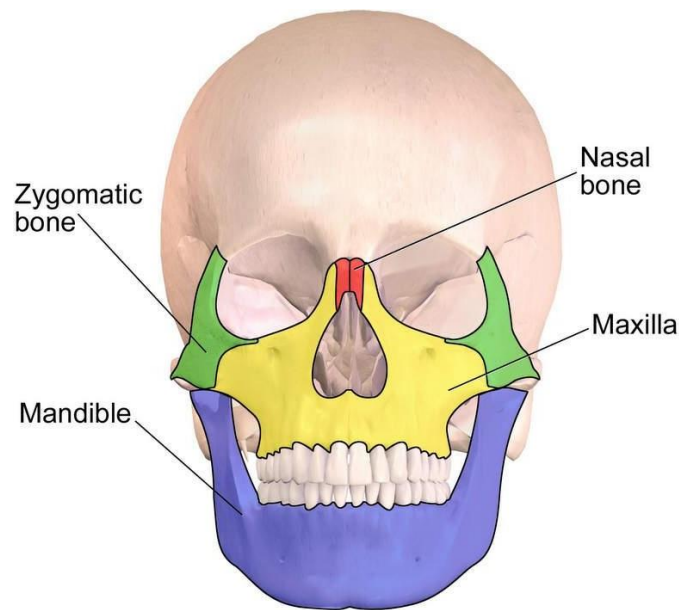
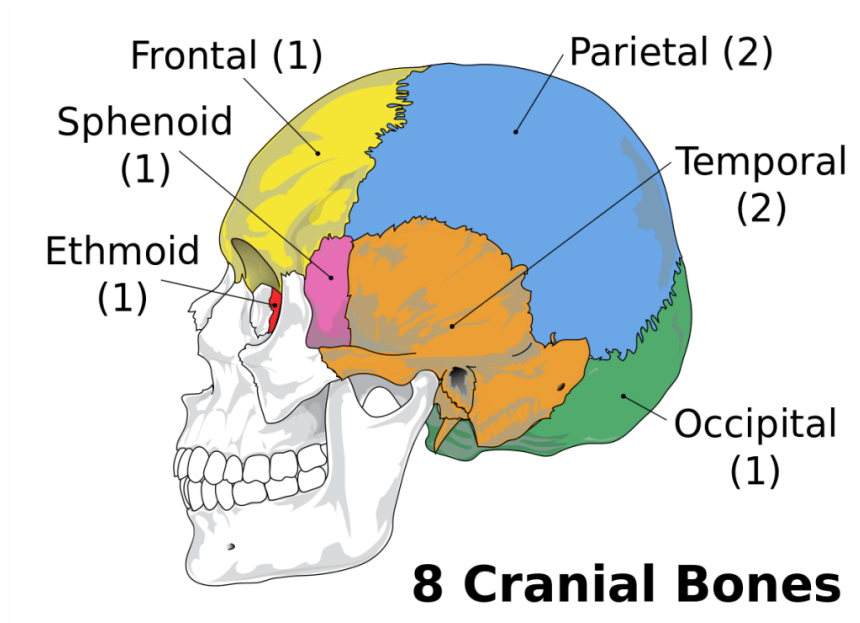
3- Thoracic cage

The skull : A-

Composed of two sets of bones

1- Cranium (cranial bones)

2- Facial bones



Bones of the Face

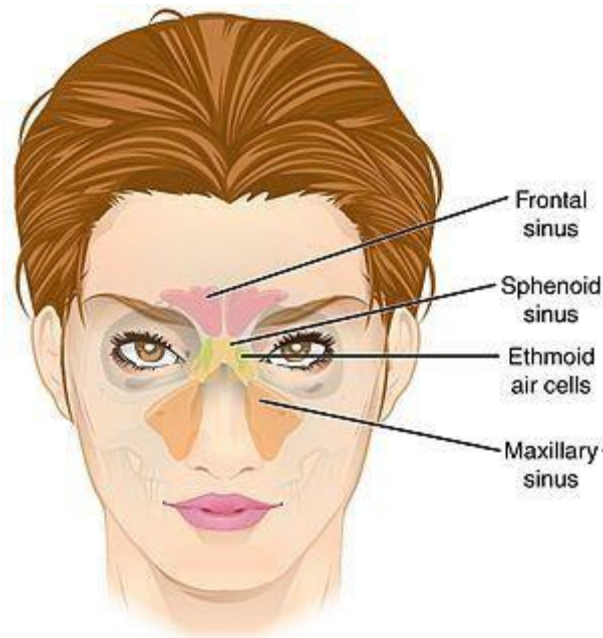
These bones are joined by **suture** making them **immobile** ,and only the **mandible** is a movable bone .

The paranasal sinuses

Hollow portions of bones surrounding the nasal cavity. We have **4 pairs of sinuses** :

- 1- Frontal**
- 2- Ethmoid**
- 3- Sphenoid**
- 4- Maxillary**

The paranasal sinuses are joined to the nasal cavity via small orifices ; so allergic inflammation or cold ----→block orifices ----
→ sinusitis ----- →block normal drainage of mucus

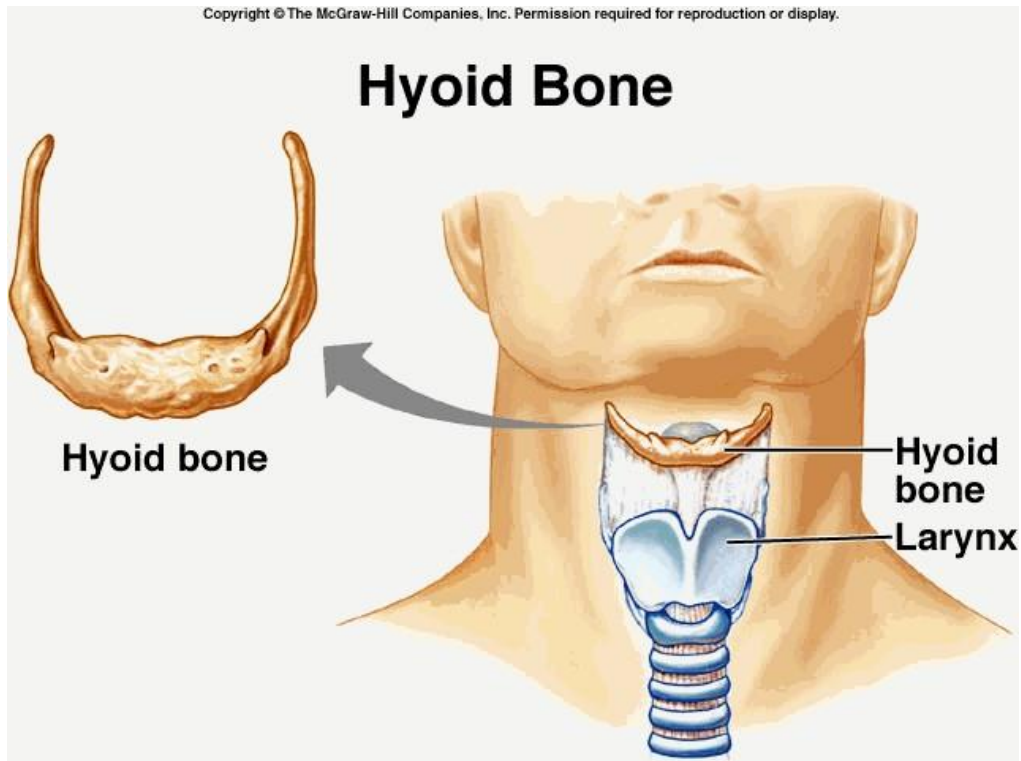


Function of paranasal sinuses :

- 1- Lighten the skull (reduce weight)**
- 2- Give resonance and amplification to voice**
- 3- May contribute to humidifying of inspired air.**

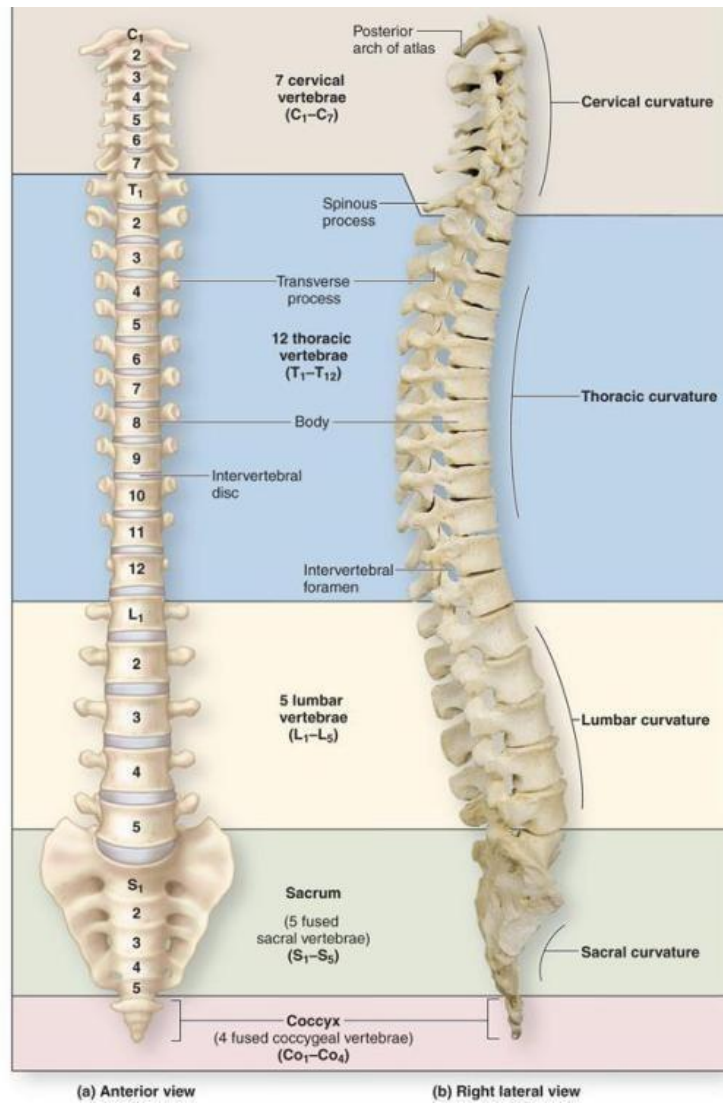
The hyoid bone (lingual bone – tongue bone) The only bone that does not articulate with another bone. Aid in the movement of tongue and swelling ..

Location : between the chin & thyroid cartilage .



The vertebral column B-

Vertebra are **irregular bones separated by intervertebral discs and delivers the weight of the body to the pelvis** .The spine has a normal curvature . Each vertebrae is given a name according to its location . The major function of the vertebral column is protection of the spinal cord ; it also provides stiffening for the body and attachment for the pectoral and pelvic girdles and many muscles . **in humans an additional function is to transmit body weight in walking and standing .**



We have :

- 7 cervical vertebrae
- 12 thoracic vertebrae
- 5 lumbar vertebrae
- 5 fused sacral vertebrae (sacrum)
- 4 fused coccygeal vertebrae (coccyx)

The bony thorax (thoracic cage): C-

Forms a cage to **protect major organs of the chest** (lungs, heart, major vessels, and esophagus)

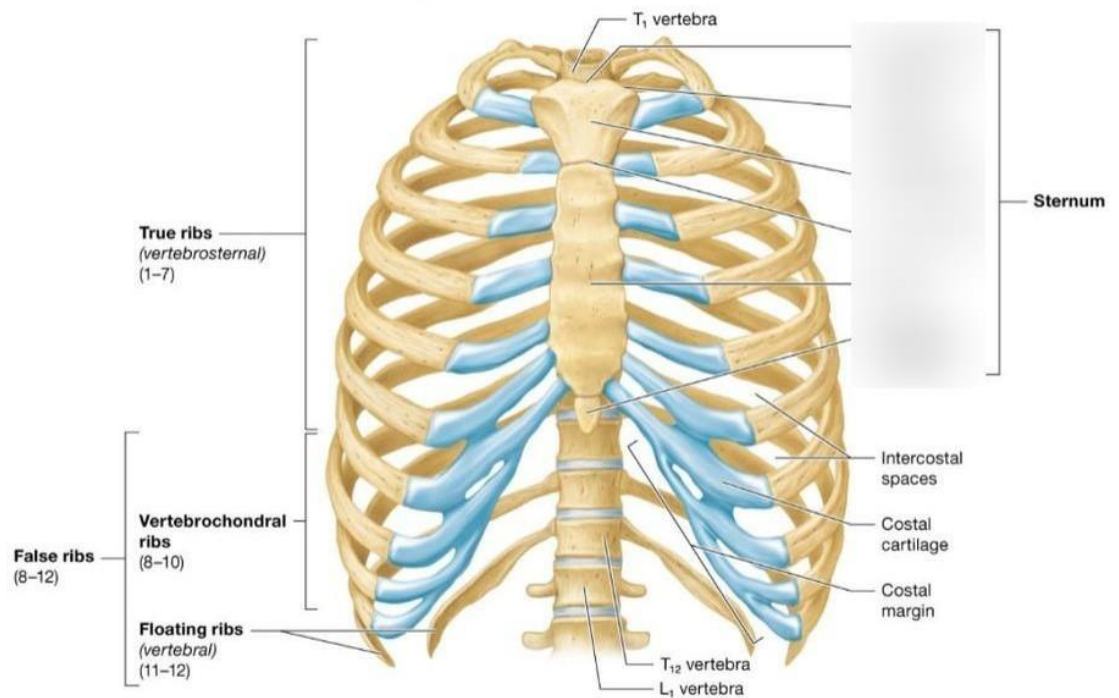
The thoracic cage made up of 3 parts :

1- The sternum

2- The ribs

3- The thoracic vertebrae

The Thoracic Cage



Ribs :

True (1-7) -

False (8-10) -

Floating (11-12) -

The appendicular skeleton

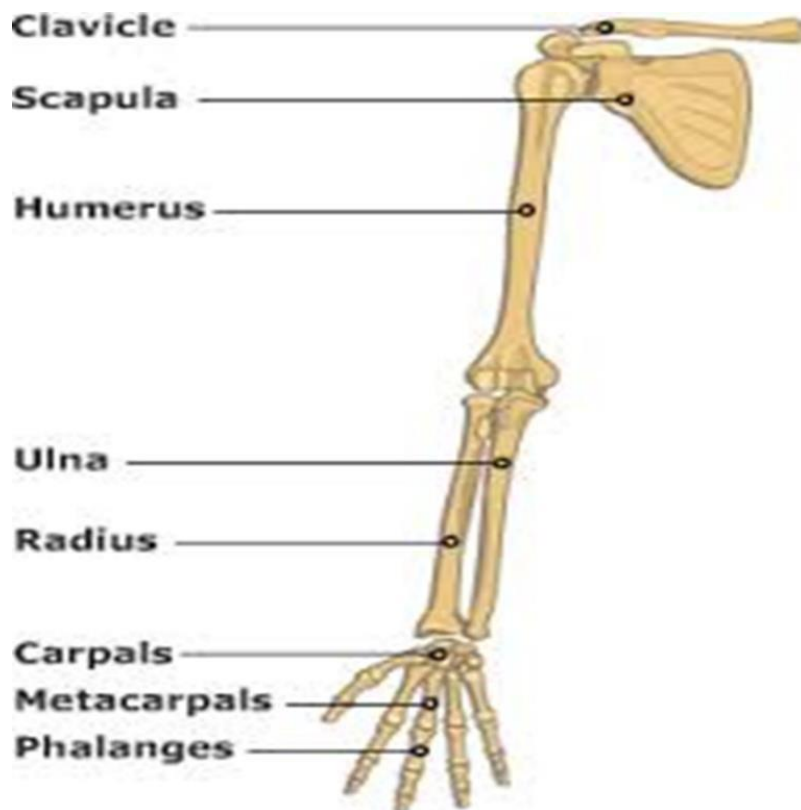
Includes :

1- The pectoral (shoulder) girdle and upper limbs

- Clavicle bone
- Scapula
- Upper limb bones :
 - > Humerus
 - > Forearm : has 2 bones :

- radius - Ulna

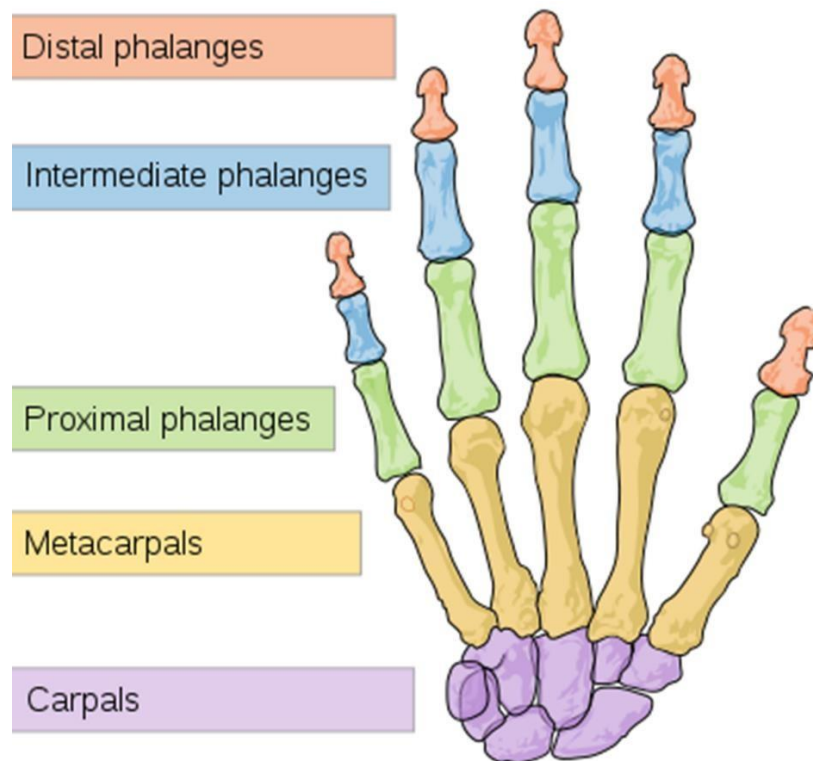
(these two bones enables the wrist joint to rotate)



- **The hand**

Is composed of :

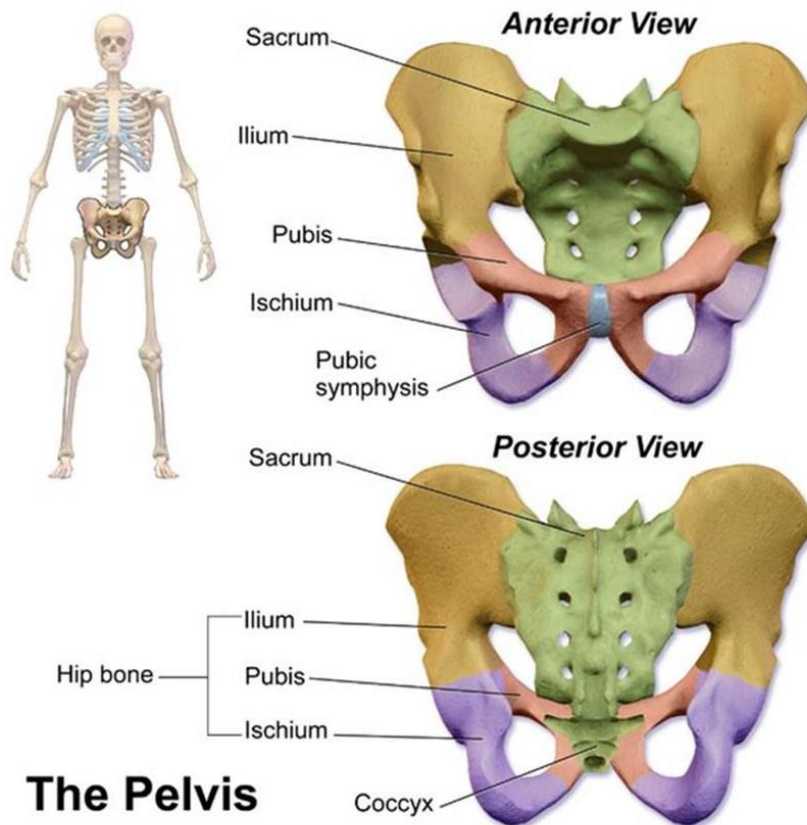
- Carpal bones (wrist bone)
- Metacarpal bones (palm)
- Phalanges (fingers)



2- The pelvic girdle and lower limbs

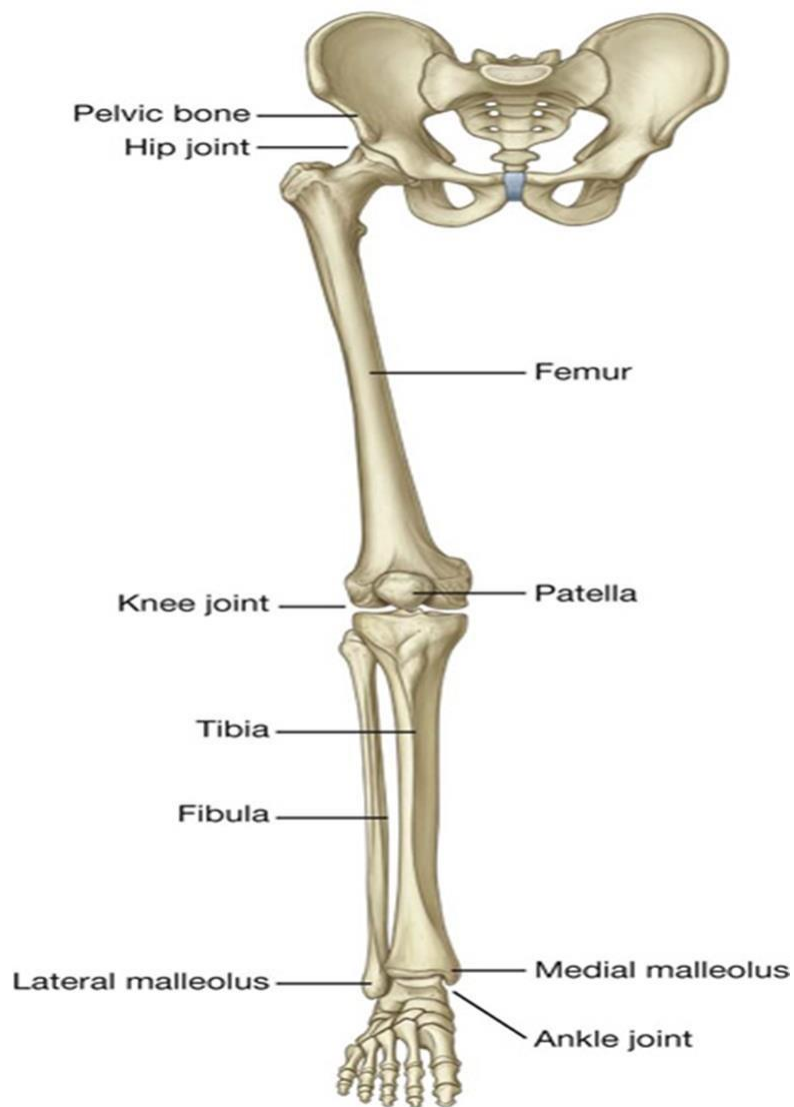
- Hip bone : composed of 3 fused bones
 - Ilium : the largest and upper most bone of the pelvis and accounts for the width of your pelvis
 - Ischium
 - Pubic bone

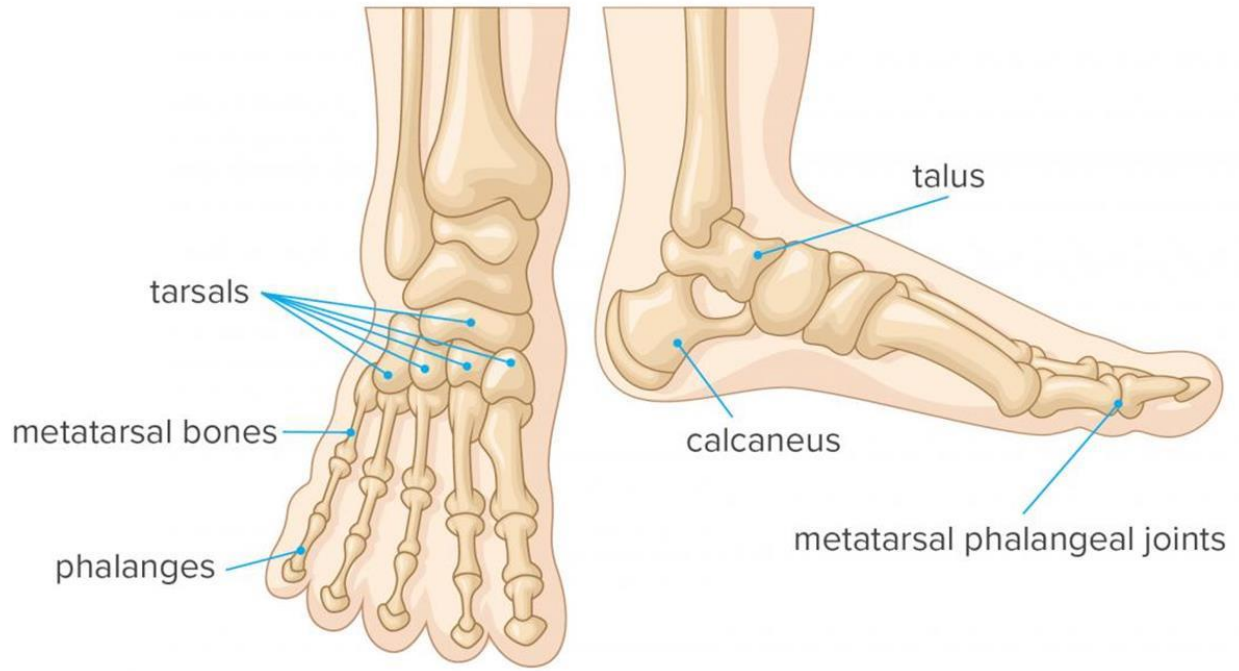
The total weight of the upper body rests on the pelvis , the pelvis supports and balances the trunk and protect several organs (reproductive organs , urinary bladder , part of large intestine).



The Pelvis

- Femur bone (thigh bone)
- Leg bones :
 - Tibia
 - Fibula
- Foot bones :
 - Tarsus : (ankle bones)
 - Helps in walk , jump , run and contributes to lower limb stability**
 - Metatarsal : (give the foot its arch)
 - Phalanges (toes)





الوحدة الخامسة, والسادسة - المحاضرة الخامسة /السادسة- الزمن: 120دقيقة

أهداف المحاضرة:

يتوقع في نهاية الجلسة أن يكون الطالب قادراً على معرفة ماهو Articulation واجزاءه.

موضوعات المحاضرة الخامسة/السادسة:

Articulation

الأساليب والأنشطة والوسائل التعليمية

الوسائل التدريبية	الأساليب والأنشطة التدريبية	م
<ul style="list-style-type: none"> • جهاز حاسوب • جهاز عرض 	<ul style="list-style-type: none"> • محاضرة • مناقشة 	5

المادة العلمية:

Articulations

- ▶ *An area where two bones are attached for the purpose of motion of body parts.*

The range of movements is from: Freely movable to limited to no apparent movement.

- ▶ Types of joints:
- ▶ **Structural:** Based on major connective tissue type that binds bones.
 - ▶ Fibrous.
 - ▶ Cartilaginous.
 - ▶ Synovial.
- ▶ **Functional:** Based on degree of motion.
 - ▶ Non movable.
 - ▶ Slightly movable.
 - ▶ Freely movable.

Articulations

Classification of Joints – Structure

(1) Fibrous joints

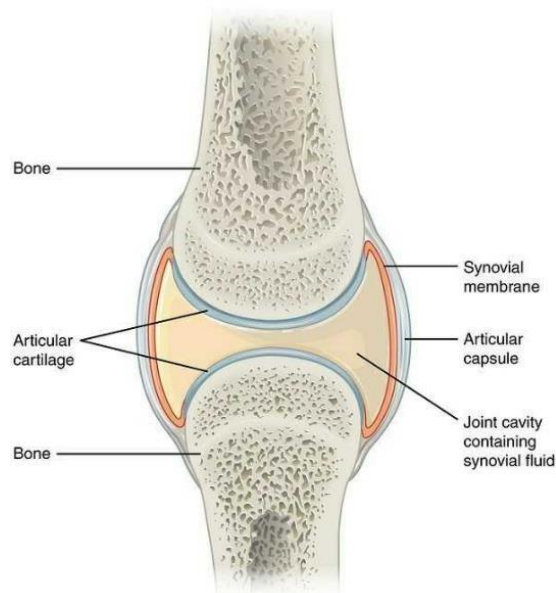
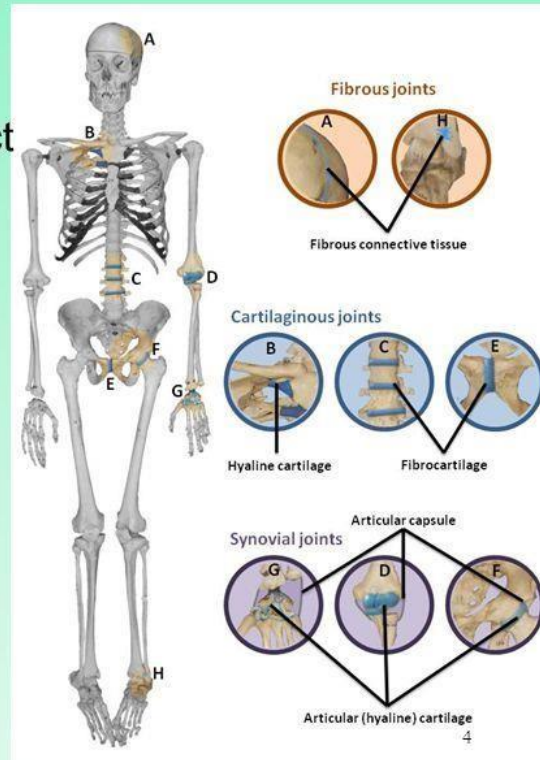
- Dense connective tissues
- Between bones in close contact

(2) Cartilaginous joints

- Hyaline or fibrocartilage

(3) Synovial joints

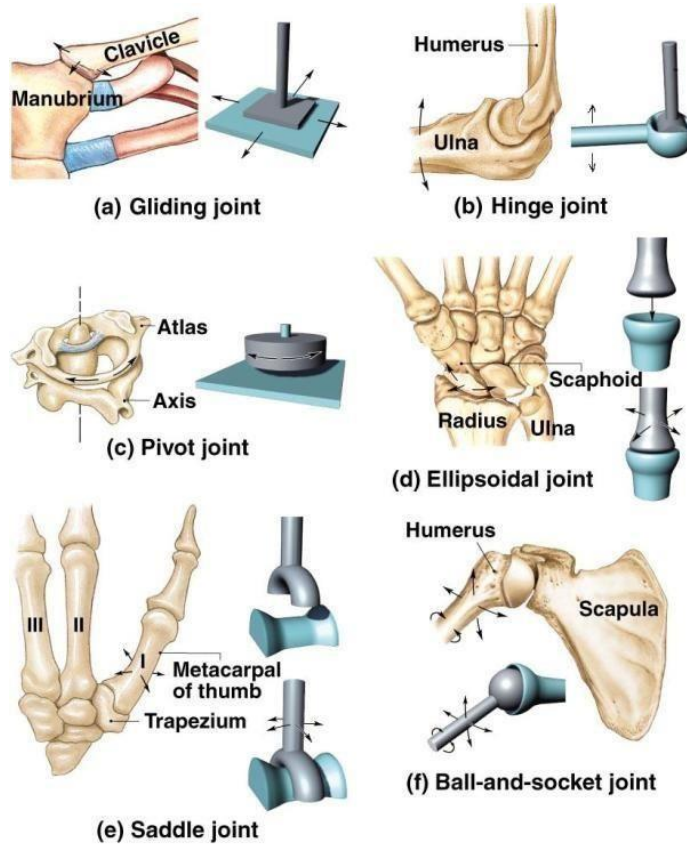
- Most complex
- Allow free movement



Synovial Joint Shape Types

- ▶ **Plane joints:** A **plane joint** (**gliding joint, plane articulation**) is a **synovial joint** which allows only **gliding** movement.(example : intercarpal and intertarsal joint).
- ▶ **Hinge joints:** are formed **between two or more bones where the bones can only move along one axis to flex or extend (one plane)**
. example : (**elbow , Knee joints**)
- ▶ **Pivot joints:** an anatomical articulation that consists of a **bony pivot in a ring of bone and ligament (as that of 1st and 2nd cervical vertebra)** and that permits **rotatory movement only.** (**another example : radio-ulnar joint = forearm rotation**)
- ▶ **Condylloid joints** ((also called **condylar, ellipsoidal, or bicondylar**) is an **ovoid articular surface, or condyle that is received into an elliptical cavity. This permits movement in two planes, allowing flexion, extension, adduction, abduction, and circumduction .**
example : metacarpo-phalangeal)
- **Saddle joints:** **saddle-shaped** articular surfaces that are **convex in one direction and concave in another** and that permit movements in all directions except axial rotation .
example: (carpo-metacarpal joint of thumb)
- **Ball and socket:** a joint in which a **ball** moves within a **socket** so as to allow rotary motion in every direction within certain limits. An articulation (such as the hip joint) in which the rounded head of one bone fits into a cuplike cavity of the other and admits movement in any direction.

Example: (hip, shoulder joints)

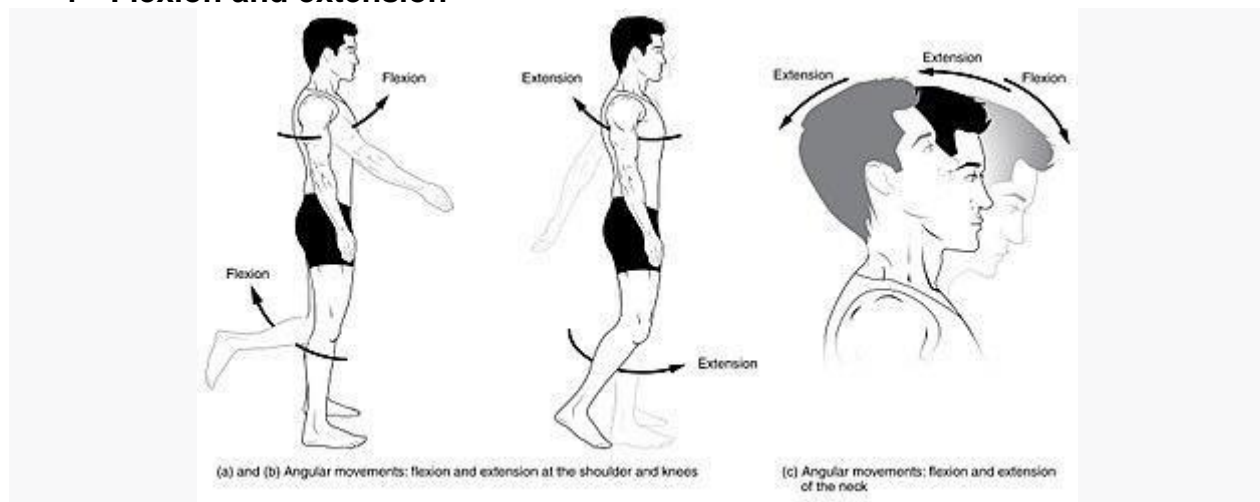


Copyright © 2007 Pearson Education, Inc., publishing as Benjamin Cummings

General motion :

These are general terms that can be used to describe most movements the body makes. Most terms have a clear opposite, and so are treated in pairs.

1- Flexion and extension

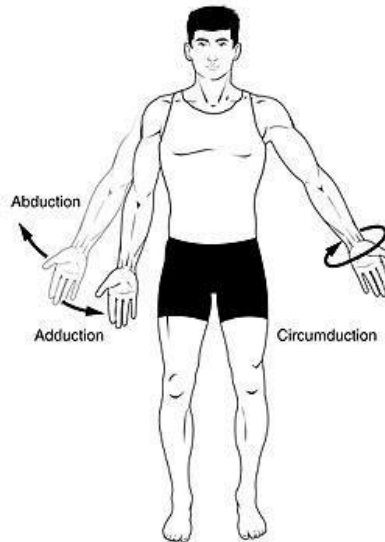


Flexion describes a bending movement that *decreases* the angle between a segment and its proximal segment. For example, bending the **elbow** . When sitting down, the knees are flexed.

Extension is the opposite of flexion, describing a straightening movement that *increases* the angle between body parts. For example, when standing up, the knees are extended.

2- Abduction and adduction

Abduction is the motion of a structure away from the midline while adduction refer to motion towards the center of the body.



(e) Angular movements: abduction, adduction, and circumduction of the upper limb at the shoulder

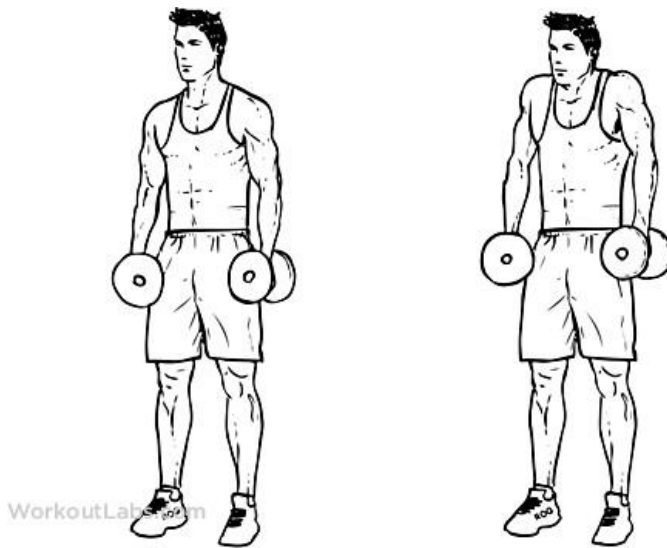
(f)

3- Elevation and depression

The terms elevation and depression refer to movement above and below the horizontal.

For example, **shrugging** is an example of elevation of the scapula. **direction. superior a movement in Elevation is**

Depression is movement in an inferior direction, the opposite of elevation.



4- Rotation

Rotation of body parts is referred to as internal or external, referring to rotation towards or away from the center of the body.

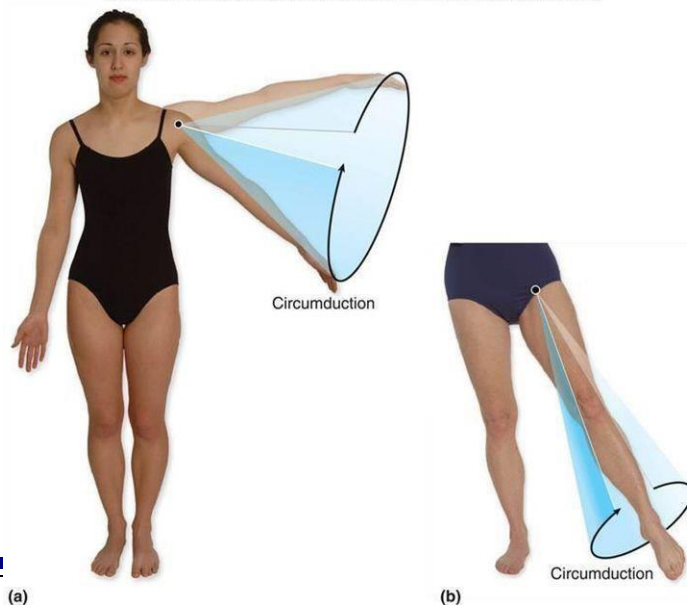
Internal rotation (or medial rotation) is rotation towards the axis of the body.

External rotation (or lateral rotation) is rotation away from the center of the body.

5- Circumduction

is a conical movement of a body part, such as a ball and socket joint or the eye. Circumduction is a combination of flexion, extension, adduction and abduction. Circumduction can be best performed at ball and socket joints, such as the hip and shoulder, but may also be performed by other parts of the body such as fingers, hands, feet, and head. For example, circumduction occurs when spinning the arm when performing a serve in tennis or bowling a cricket ball.

Copyright © The McGraw-Hill Companies, Inc. Permission required for reproduction or display.

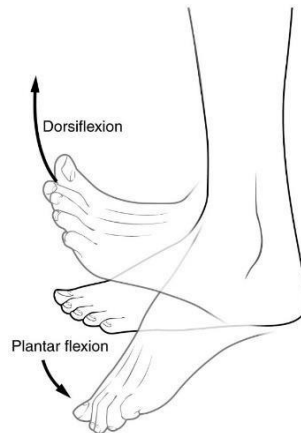

Special motion Feet and

Hand:

Dorsiflexion : This decreases the angle between the dorsum of the foot and the leg. For example, when walking on the heels the ankle is described as being in dorsiflexion.

Plantar flexion or plantarflexion is the movement which decreases the angle between the sole of the foot and the back of the leg; for example, the movement when depressing a car pedal or standing on tiptoes.



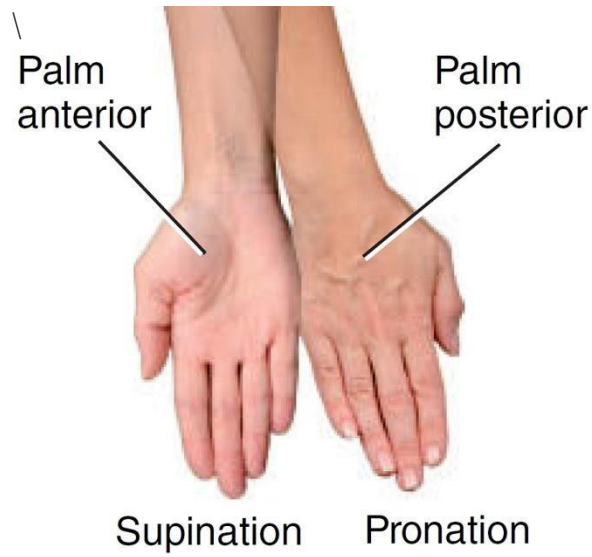
Palmarflexion is decreasing the angle between the palm and the anterior forearm.

Dorsiflexion is extension at the ankle or wrist joint. This brings the hand closer to the dorsum of the body.

Others :

Pronation at the forearm is a rotational movement where the hand and upper arm are turned inwards.

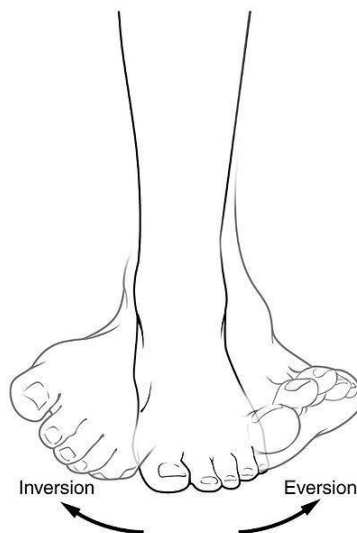Supination of the forearm occurs when the forearm or palm are rotated outwards.



Inversion and eversion:

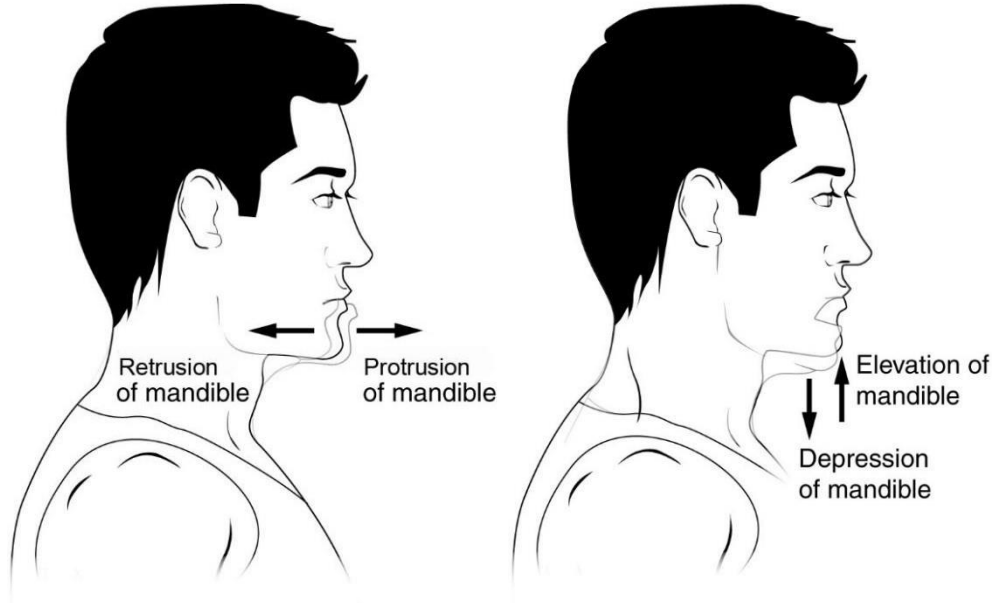
Inversion and eversion refer to movements that tilt the sole of the foot away from (eversion) or towards (inversion) the midline of the body.

***Eversion* is the movement of the sole of the foot away from the median plane. *Inversion* is the movement of the sole towards the median plane. For example, inversion describes the motion when an ankle is twisted.**



Jaw and teeth

- Occlusion is motion of the mandibula towards the maxilla making contact between the teeth.
- Protrusion and retrusion are sometimes used to describe the anterior (protrusion) and posterior (retrusion) movement of the jaw.



الوحدة السابعة - المحاضرة السابعة - الزمن: 120 دقيقة

أهداف المحاضرة السابعة:

يتوقع في نهاية الجلسة أن يكون الطالب قادراً على معرفة ماهو muscular system و اجزاءه.

موضوعات المحاضرة السابعة:

Muscular system

الأساليب والأنشطة والوسائل التعليمية

الوسائل التدريبيه	الأساليب والأنشطة التدريبيه	م
<ul style="list-style-type: none">• جهاز حاسوب• جهاز عرض• سبورة• اوراق واقلام	<ul style="list-style-type: none">• محاضرة• مناقشة• سؤال وجواب	7

The *muscular system* is made up of *three* types of tissue:

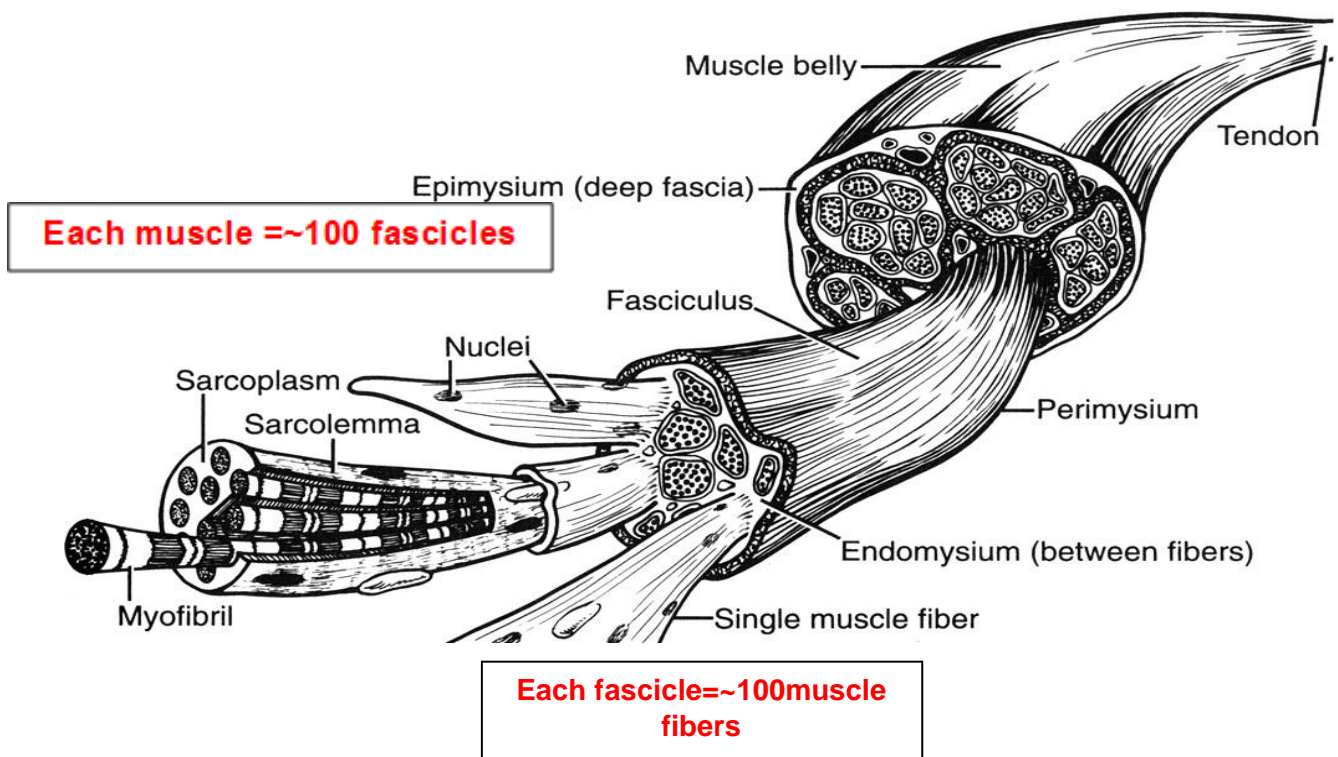
1. Skeletal muscles.
2. Smooth muscles.
3. Cardiac muscles.

They differ in terms of:

1. Location.
2. Cell structure.
3. Innervations.

Characteristics of all muscle tissues:

1. **Specialized cells:** elongated, high density of myofilaments "*cytoplasmic filaments of actin and myosin*".
2. **Excitability/irritability:** receive and respond to stimulus.
3. **Contractility:** shorten and produce force upon stimulation.
4. **Extensibility:** can be stretched.
5. **Elasticity:** can be recoil after stretch.

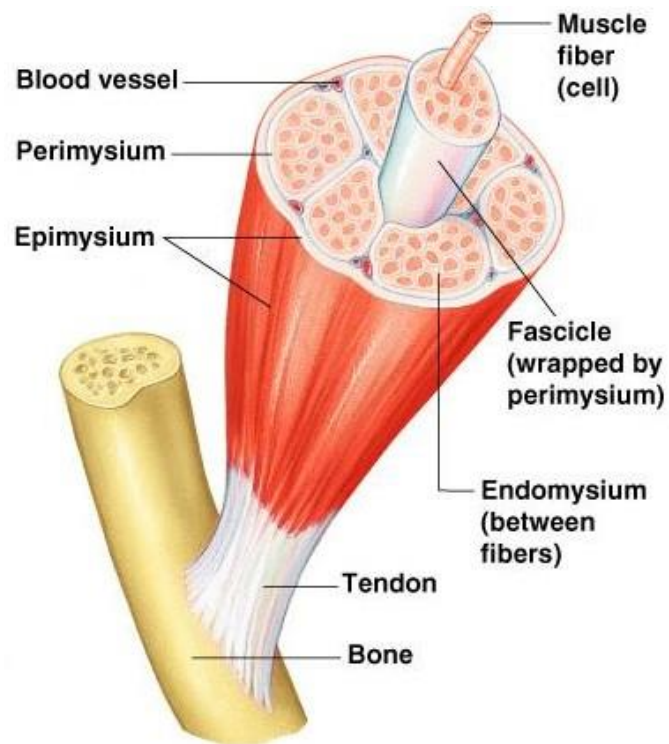


- **Skeletal muscles** vary considerably in *size, shape, and arrangement* of fibers. They range from extremely tiny strands such as the stapedius muscle of the middle ear to large masses such as the muscles of the thigh. Some skeletal muscles are broad in shape and some narrow.
- A whole skeletal muscle is considered an organ of the [muscular system](#). Each skeletal muscle is an organ consists of **4 types** of tissues: epithelial tissue, [connective tissue](#), nerve tissue, and muscular tissue.
- Skeletal muscle tissue is surrounded by connective tissue. It is separated from the skin by the **superficial fascia**, also known as the subcutaneous layer, which is composed of connective tissue and adipose (fat) tissue.
- Skeletal muscles either attach to bones or to the skin, like facial muscles. All are consciously controlled, some are subconsciously controlled such as the **diaphragm** which is consciously controlled when we take a deep breath but otherwise it contracts and relaxes subconsciously, as in sleeping or thinking about other things.
- Skeletal muscles help maintain the posture and stabilize the joints. They are the sores of the body temperature.

- The muscle belly is a bundle of bundles: the bigger bundles are called **fascicles** and each fascicle is a bundle of **muscle fibers**. The coverings of each bundle also have names with the *epimysium* covering the muscle itself, the *perimysium* covering the fascicle and the *endomysium* covering the fibers. The remaining outer cell membrane is called the sarcolemma and the contents are called sarcoplasm. Within the fiber individual contractile units are called **myofibrils**.

Skeletal muscle Characteristics :

- Most are attached by tendons to bones
 - Cells are multinucleate
 - Striated – have visible banding
- Voluntary – subject to conscious control
- Cells are surrounded and bundled by connective tissue



- **Endomysium** – around single muscle fiber
- **Perimysium** – around a fascicle (bundle) of fibers
- **Epimysium** – covers the entire skeletal muscle
 - **Fascia** – on the outside of the epimysium

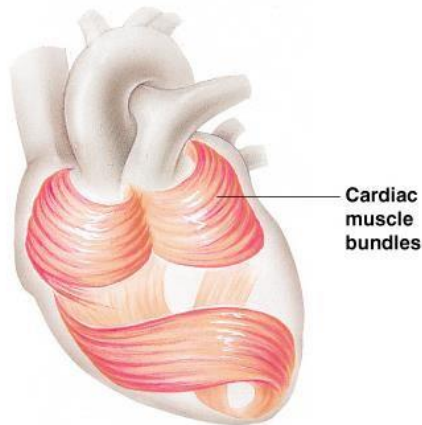
- **Epimysium** blends into a connective tissue attachment
 - **Tendon** – cord-like structure
 - **Aponeuroses** – sheet-like structure
 - **Sites of muscle attachment**
 - Bones
 - Cartilages
 - Connective tissue coverings

Smooth muscle Characteristics:

- Has no striations
- Single nucleus
- Involuntary – no conscious control
- Found mainly in the walls of hollow organs
(**uterus , urinary bladder , digestive and respiratory system**)

Cardiac muscle Characteristic :

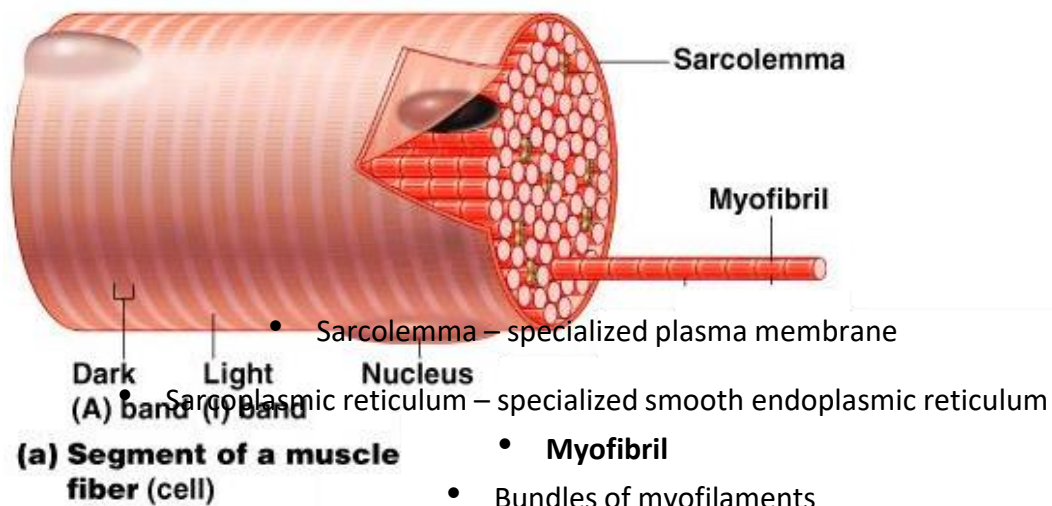
- Has striations
- Usually has a single nucleus
- Joined to another muscle cell at an intercalated disc
 - Involuntary
- Found **only** in the **heart**



(b)

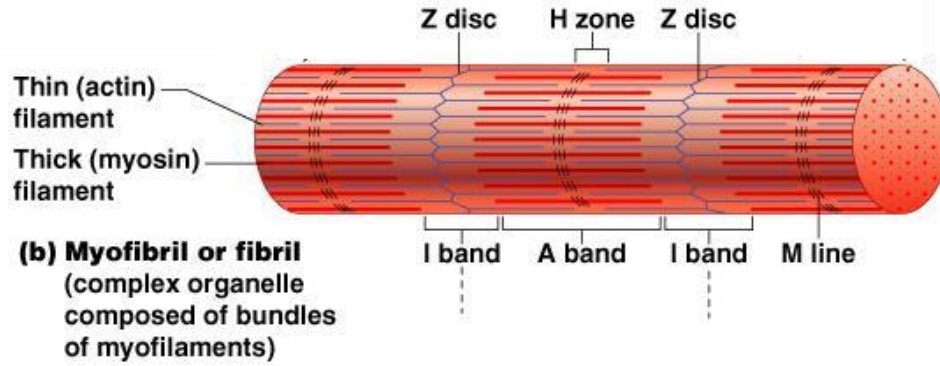
Anatomy of Skeletal Muscles :

- Cells are multinucleate
- Nuclei are just beneath the sarcolemma

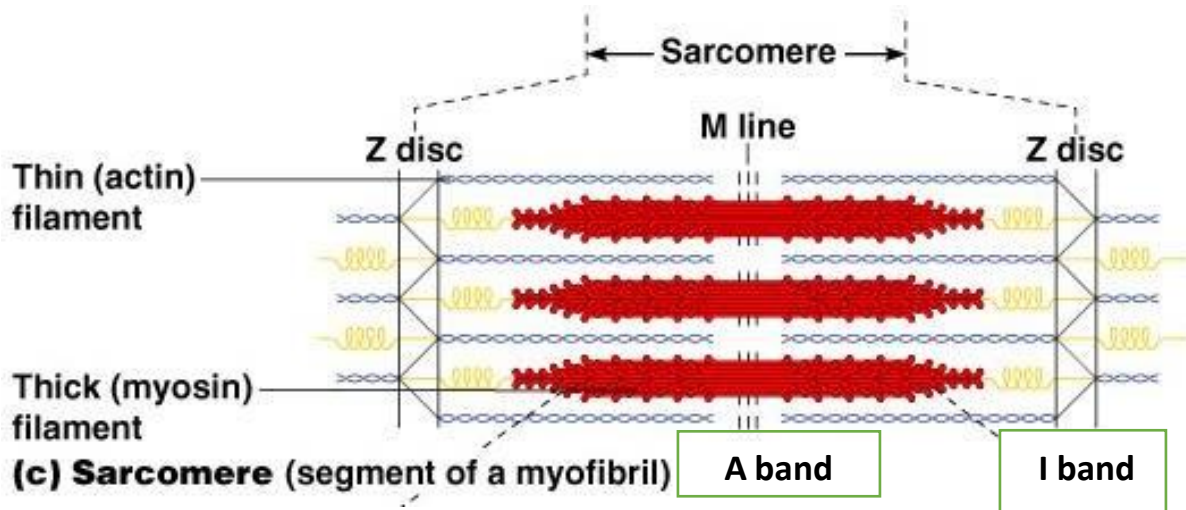


(a) Segment of a muscle fiber (cell)

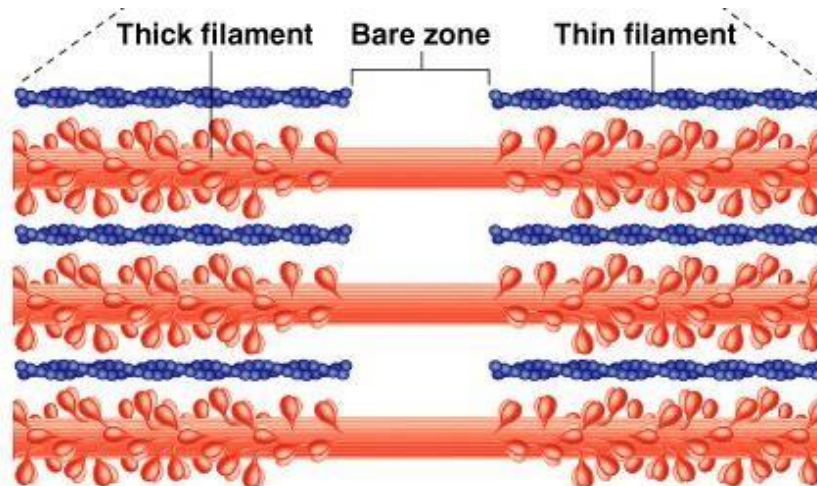
- Sarcolemma – specialized plasma membrane
- Sarcolemmal reticulum – specialized smooth endoplasmic reticulum
- Myofibril
 - Bundles of myofilaments
- Myofibrils are aligned to give distinct bands
 - I band = light band
 - A band = dark band



- **Sarcomere** : Contractile unit of a muscle fiber
 - **Organization of the sarcomere**
- Thick filaments = myosin filaments (protein myosin)
- Thin filaments = actin filaments (protein actin)



- Myosin filaments have heads (extensions, or cross bridges)
 - Myosin and actin overlap somewhat



(d) Myofilament structure (within one sarcomere)

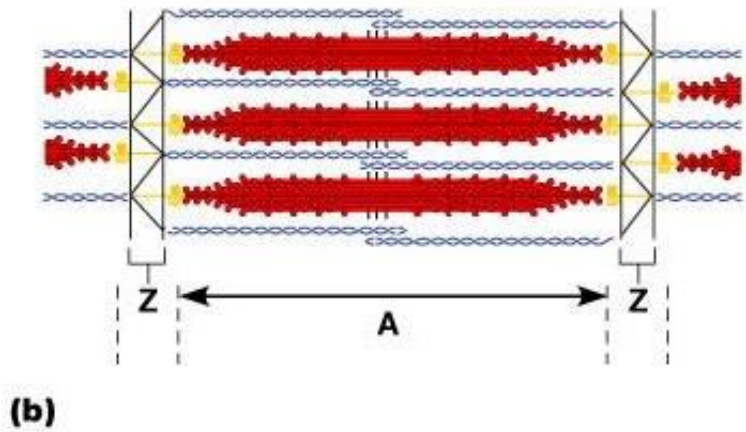
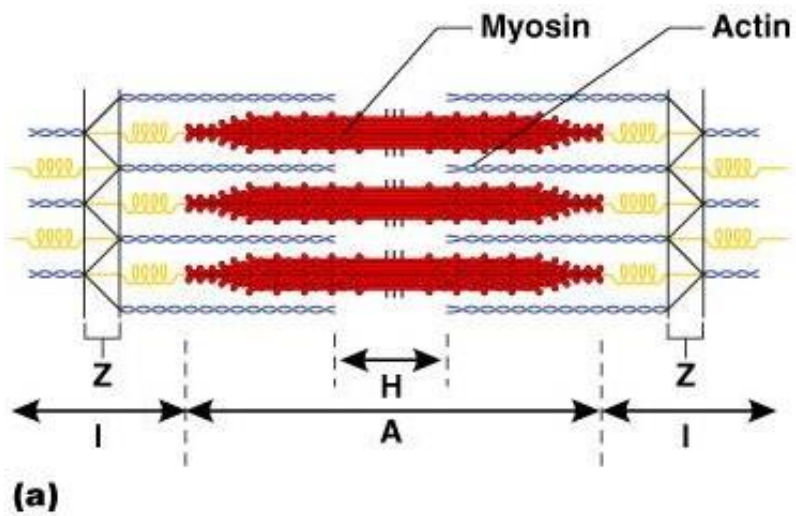
- At rest, there is a bare zone that lacks actin filaments
- Sarcoplasmic reticulum (SR) – for storage of **calcium**

Transmission of nerve impulse to Muscles :

- Neurotransmitter – chemical released by nerve upon arrival of nerve impulse
 - The neurotransmitter for skeletal muscle is acetylcholine
- Neurotransmitter attaches to receptors on the sarcolemma
 - Sarcolemma becomes permeable to sodium (Na^+)

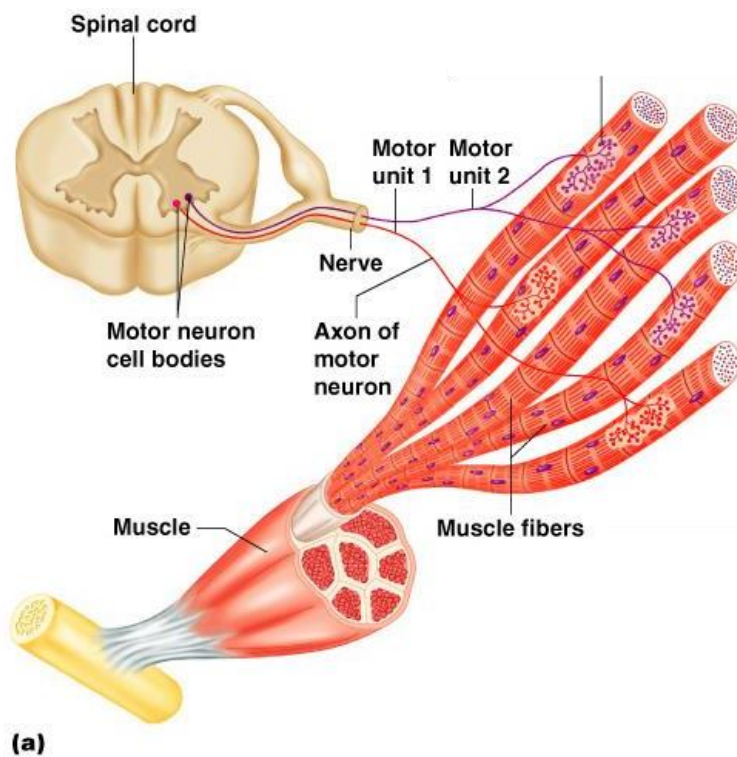
The Sliding Filament Theory of Muscle Contraction

- Activation by nerve causes myosin heads (crossbridge) to attach to binding sites on the thin filament.
 - Myosin heads then bind to the next site of the thin filament.
- This continued action causes a sliding of the myosin along the actin. The result is that the muscle is shortened (contracted).



Nerve Stimulus to Muscles

- Skeletal muscles must be stimulated by a nerve to contract
 - Motor unit :
 - One neuron
- Muscle cells stimulated by that neuron



- Synaptic cleft – gap between nerve and muscle

Muscle atrophy :

Is a reduction in muscle size , tone , and power .

Ex: if stimulation reduced , (nerves : leading to loses both mass and tone)Even temporary reduction in muscle use --- (like casting)

Muscular hypertrophy :

Increase in muscle fiber size .

(hyperplasia : means increase in number)

Muscle size may be increased by exercising : repetition --- exhaustive stimulation -----→ more mitochondria , larger glycogen reserve , increase ability to produce ATP -→ Each muscle fiber develop more myofibrils --→ more myofilament --→ hypertrophy

Types of skeletal muscle fiber :

ATP use quickly

A- Fast fibers :

fast contraction

low resistance to fatigue

**fiber function: short duration , intense movement(sprinting –
lifting weight)**

B- intermediate fibers :

ATP use quickly

high resistance to fatigue

**fiber function : medium duration , moderate movement(walking –
biking)**

C- slow fibers :

**ATP use slowly Slow
contraction**

endurance : (marathon running , maintaining posture)

The naming of skeletal muscle :

A- muscle action : - Adductor , abductor, flexor, extensor

B- special body region :

- oris : mouth .

- Brachial : arm

- carpi : wrist

- gluteal : buttocks

- femoris : thigh

- - posterior

- superior – inferior

-relation : - anterior

- superficialis
- profundus (deep)

C- Muscle attachments :

- sternum and clavicle (cleido) : sternocleidomastoid m
- between ribs : intercostal

D- orientation of muscle :

- rectus : straight
- oblique : angled
- orbicularis : circular

E- muscle shape and size :

- deltoid : triangular
- quadratus : rectangular
- trapezius : trapezoidal
- longus : long
- major : large of two muscle
- maximus : largest
- medius : medium
- minimus : smallest
- brevis : short
- minor ; smaller

F- muscle heads ;

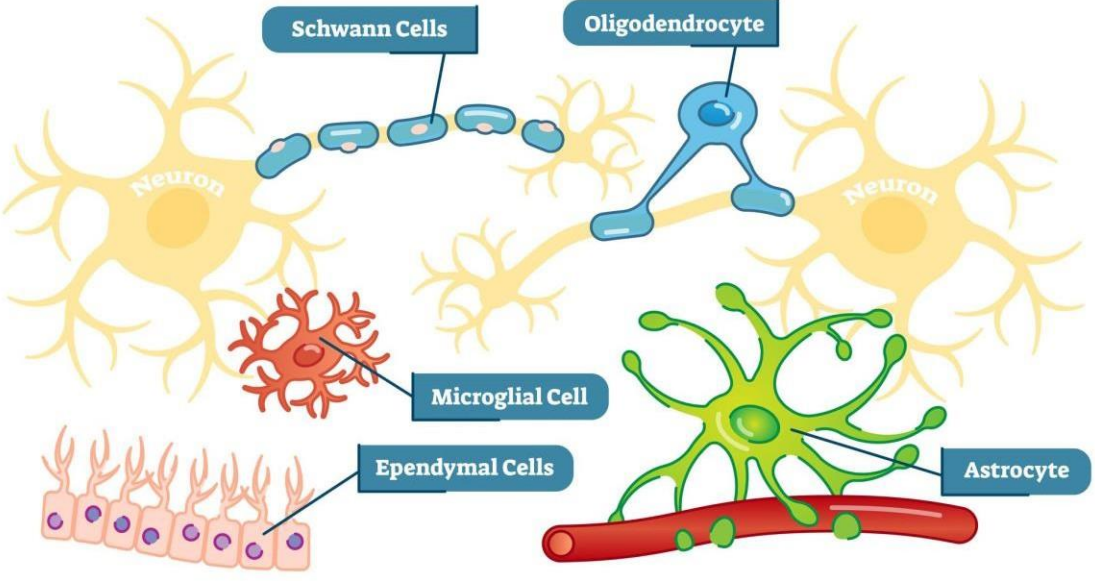
- Biceps (two heads)
- Triceps (3 heads)
- Quadriceps (4 heads)

Origin : is the less movable attachment of muscle

Insertion : the more movable attachment of muscle

(usually the insertion is pulled toward the origin)

Glial Cells



Nerve Impulses

A nerve is a cable like bundle of parallel axons . When axons are resting, they are not conducting nerve impulses. When they are active, axons are conducting nerve impulses, also called action potentials.

Resting Potential

When an axon is resting, its membrane is polarized; that is, the outside is positive compared to the inside, which is negative. A protein carrier in the membrane, called the sodium potassium pump, pumps sodium (Na) out of the axon and potassium (K) into the axon.

The polarity across an axon that is not conducting nerve impulses is called the *resting potential*.

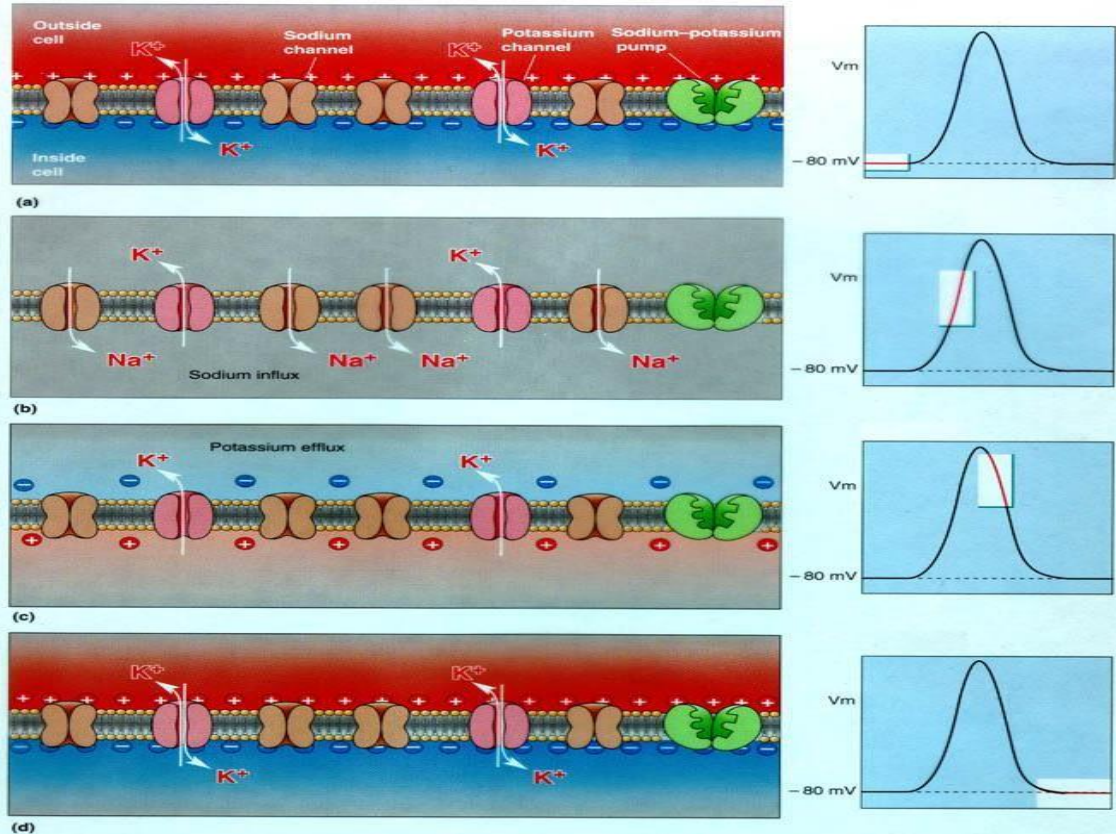
Action Potential

When the nerve fiber is conducting a nerve impulse (action potential), a change in polarity occurs across the axon's membrane.

First, the inside of an axon becomes positive compared to the outside (this is called depolarization), and then the inside becomes negative again (this is called repolarization).

An action potential requires two types of channels in the membrane: One channel can allow Na ions to pass through the membrane, and the other can allow K ions to pass through the membrane.

During depolarization, Na ions move to the inside of the axon, and during repolarization, K ions move to the outside.



Synapses :

Axons terminate as the contact other neurons , muscle cells or other gland cells at specialized junction , called synapses.

Two types of synapses :

1- Electrical synapses :

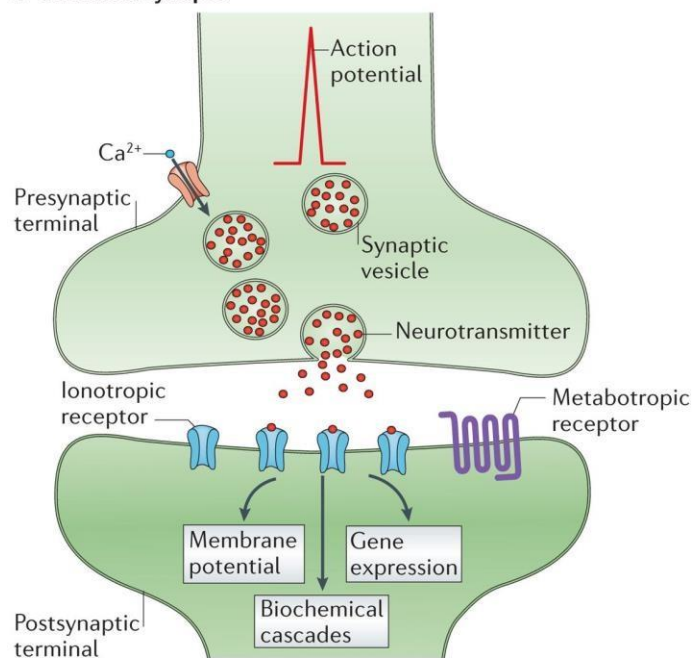
gap junction is formed between plasma membrane facilitate the flow of ions , such as Na^+ between the cells (voltage change results in nerve impuls). There is no delay in the passage of nerve impulse between them (like smooth m of intestine, cardiac m).

2- Chemical synapses :

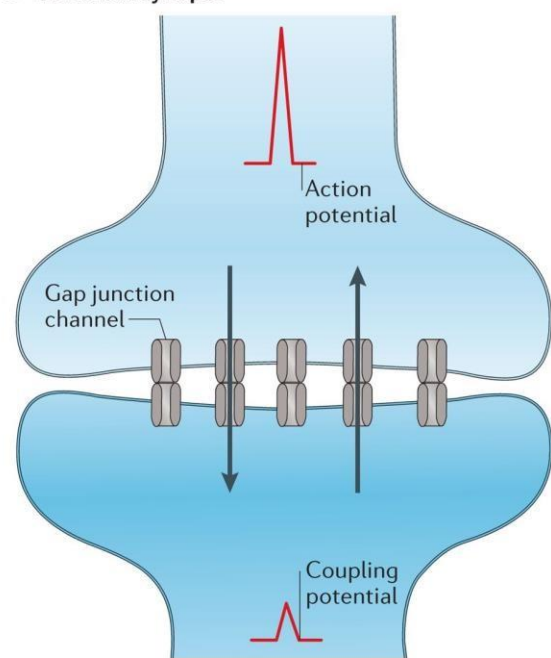
The most numerous type . Neurons will release a signaling molecule called a neurotransmitter , such as Ach.(acetylcholine)

It then binds to receptors proteins found on plasma membrane , and this will cause brief voltage change across the membrane.

a Chemical synapse



b Electrical synapse



Nature Reviews | Neuroscience

Neural Integration :

There is four different neuronal circuits (neuronal pools) : based upon function :

1- Converging circuit :

**Several inputs leads to single output . Ex :
production of saliva**

2- Diverging circuit :

**single or few inputs -> multiple outputs Ex :
movement of skeletal muscles in
Legs during walking , also stimulate muscles In the back (maintain posture).**

3- Reverberating circuit :

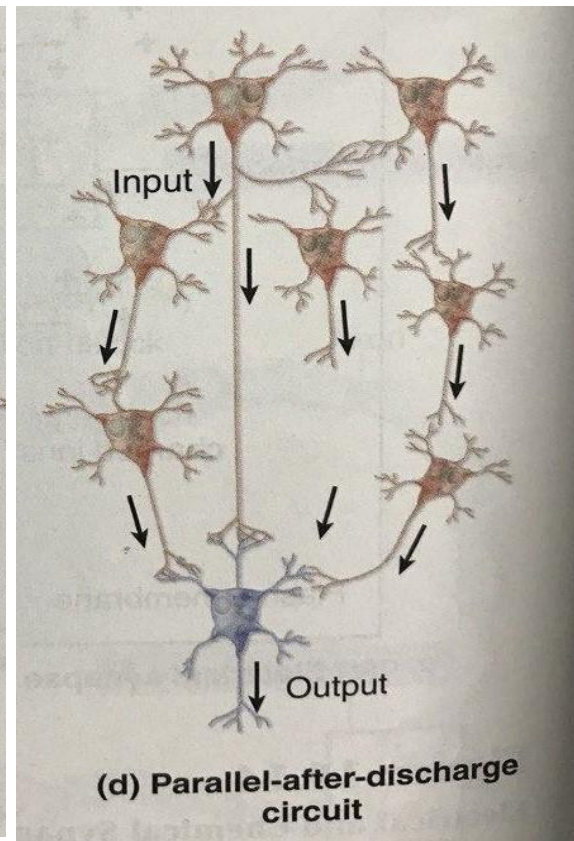
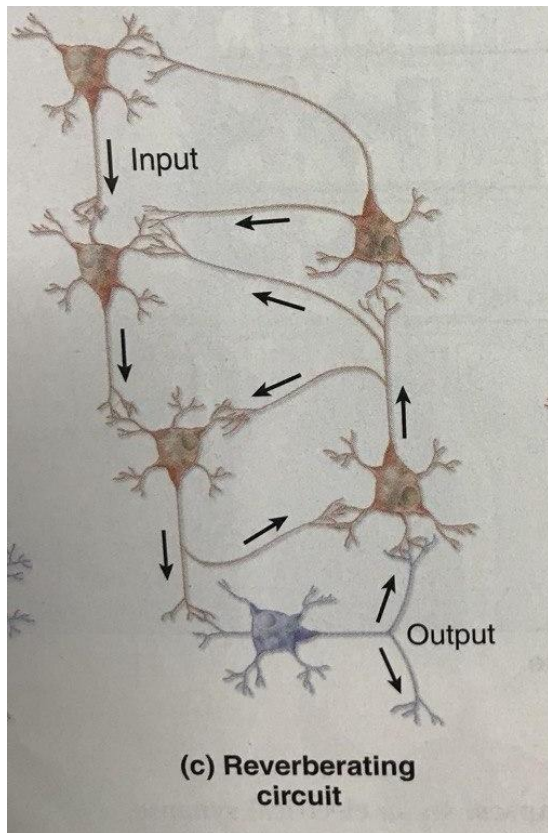
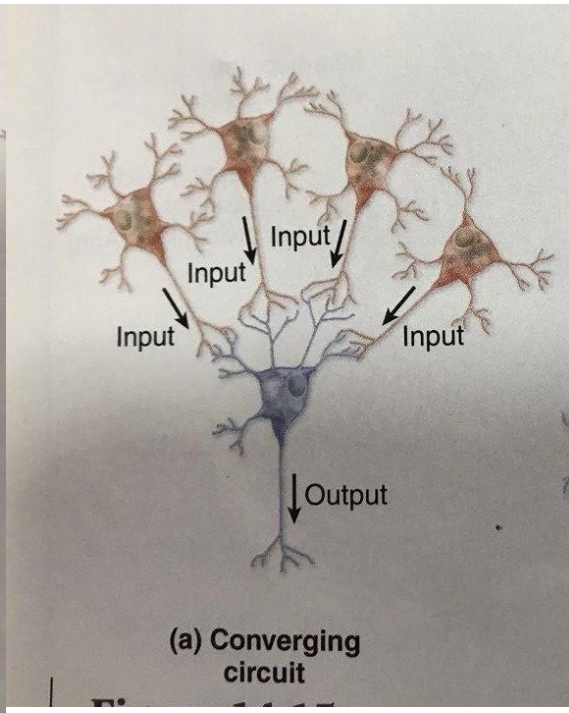
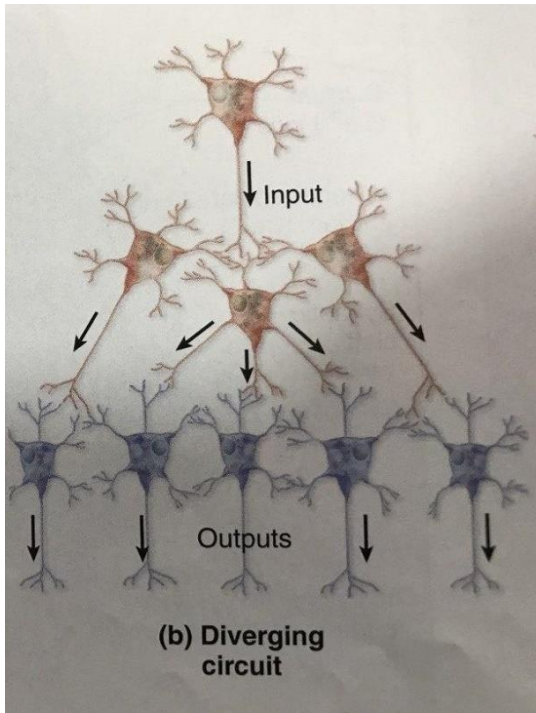
Utilize feedback to produce a

**repeated cyclical stimulation of the circuit. Ex :
breathing**

4- Parallel – after – discharge circuit :

several neurons process the same information

**at one time , This type of circuit is believed to be involved In higher –
order thinking , as needed for performing Precise mathematical
calculations for example.**



- المحاضرة التاسعة - الزمن: 120 دقيقة

أهداف المحاضرة التاسعة:

يتوقع في نهاية الجلسة أن يكون الطالب قادراً على معرفة ماهو Central nervous system.

موضوعات المحاضرة التاسعة:

Central nervous system الأساليب والأنشطة والوسائل التعليمية

الوسائل التدريبية	الأساليب والأنشطة التدريبية	م
<ul style="list-style-type: none">• جهاز حاسوب• جهاز عرض• سبورة• اوراق واقلام	<ul style="list-style-type: none">• محاضرة• مناقشة• سؤال وجواب	9

المادة العلمية:

nervous system has three specific functions:

- 1. Sensory input.** Sensory receptors present in skin and organs respond to external and internal stimuli by generating nerve impulses that travel to the brain and spinal cord.
- 2. Integration.** The brain and spinal cord sum up the data received from all over the body and send out nerve impulses. These functions include memory, thinking, learning, language, speech, emotions and general behavior.
- 3. Motor output.** The nerve impulses from the brain and spinal cord go to the effectors, which are muscles and glands. Muscle contractions and gland secretions are responses to stimuli received by sensory receptors.

Nervous system division :

A- structural division :

Central nervous system (CNS) :

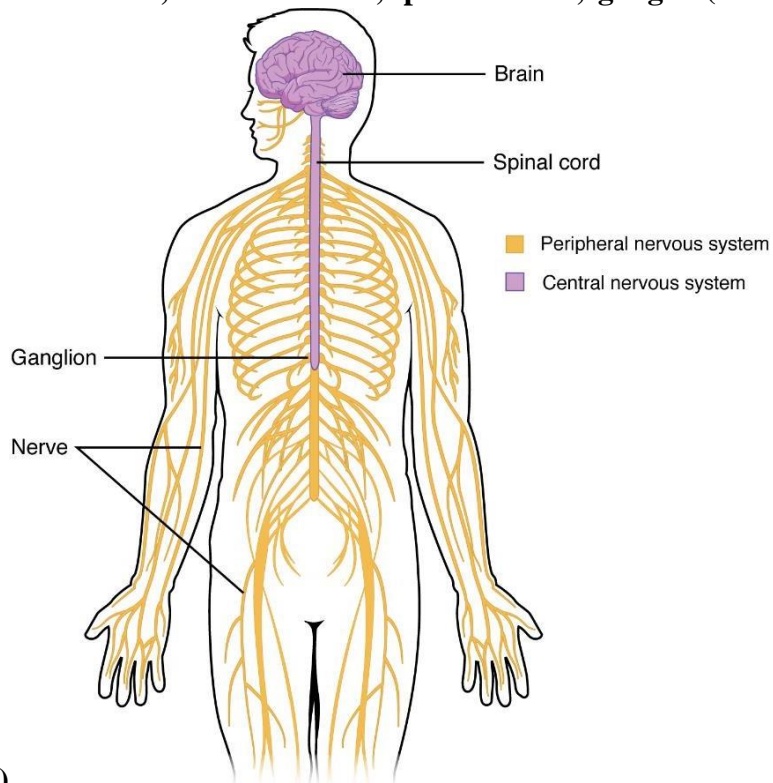
- brain

- spinal cord

Peripheral nervous system (PNS) :

(project information to and receive information from the CNS)

Includes : nerves , cranial nerves , spinal nerves , ganglia (cluster of neuron cell



bodies)

B- Functional division :

1- sensory (afferent division) : (Input)

(transmits information from periphery to CNS , contain receptors)

≥ somatic sensory :

receives sensory information from skin ,fascia , joints , skeletal muscles .

(touch , pain , temperature , pressure , vibration , position or movement of joints and limbs)

≥ visceral sensory :

receives sensory information from viscera

(organs of urinary , reproductive , digestive , respiratory and others)(visceral senses include primarily : *temperature , stretch*) ex: stomach bloating

2- Motor (efferent) division : (output)

transmit information from CNS to the rest of the body , sends motor information to effectors .

> somatic motor :

voluntary nervous system : innervate skeletal muscle

> Autonomic motor :

Involuntary nervous system (Autonomic nervous system) innervate internal organs and called visceral motor system (cardiac muscle , smooth muscle , glands)

includes : sympathetic nervous system & parasympathetic nervous system

CNS and PNS perform three general functions :

1- collecting information (receptors of PNS)

that detect changes in the internal or external environment and pass them on to CNS as sensory input .

2- Processing and Evaluating information :

after processing sensory input , the CNS determines what , if any response is required .Responding to information :

After selecting an appropriate response , the CNS initiates specific nerve impulse (rapid movements of an electrical charge along the neurons plasma membrane) called motor output , which travels through structures of PNS to effectors (Muscle and glands

Neuron structure :

basic structural features :

- a typical neuron has a **cell body** .
- Projecting from the cell body are processes called ***Dendrites and Axons*** .
- The cell body serves as neuron's control center and is responsible for receiving , integrating and sending nerve impulse .

- The cell body enclosed by plasma membrane contains cytoplasm , surrounding a nucleus , a nucleus contain a nucleolus .

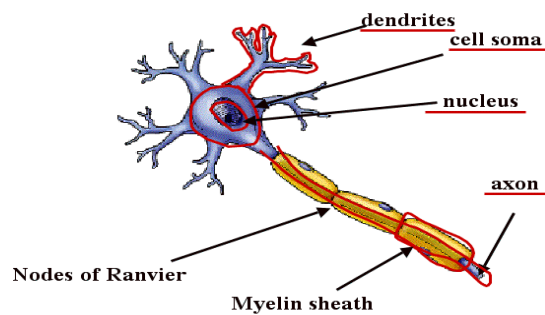
Dendrites :

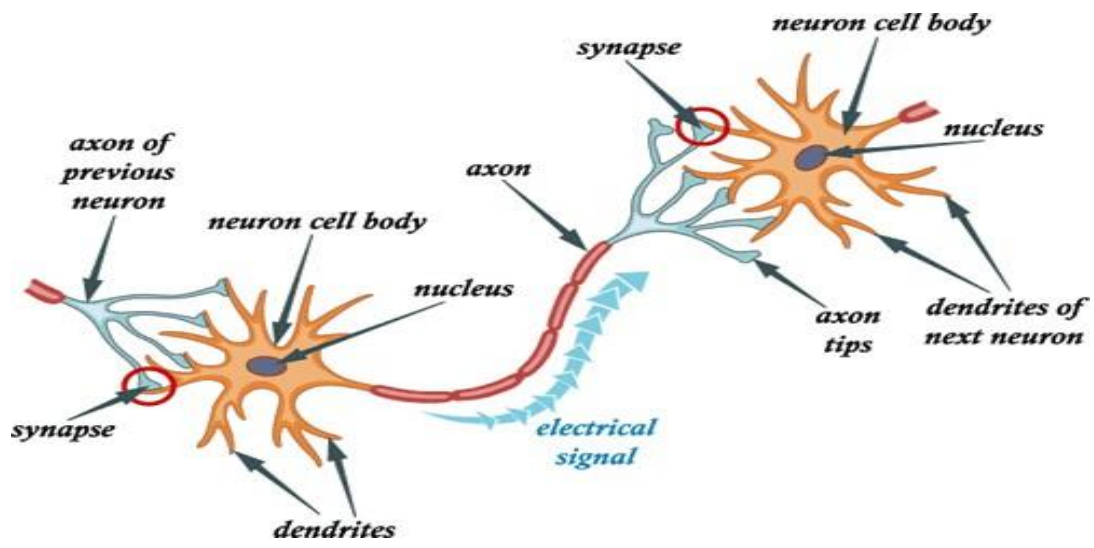
- Processes that branch off the cell body
- Conduct nerve impulses toward the cell body
- The more dendrites a neuron has , the more nerve impulses that neuron can receive from other cells.

axons :

- Larger , longer nerve cell process projecting from the cell body , sometimes called **nerve fiber**.
 - All neurons have only one axon .
- it transmits a nerve impulse away from the cell body toward another cell (transmits output information to other cells)
- The ends of axon called **axon terminals** , and their extreme tips are called **Synaptic Knobs** (bulbs).

Neuron general structure





الوحدة العاشرة - المحاضرة العاشرة - الزمن: 120 دقيقة

أهداف المحاضرة العاشرة:

Autonomic nervous system يتوقع في نهاية الجلسة أن يكون الطالب قادراً على معرفة ماهو

الأساليب والأنشطة والوسائل التعليمية

الوسائل التدريبية	الأساليب والأنشطة التدريبية	م
<ul style="list-style-type: none">• جهاز حاسوب• جهاز عرض• سبورة• اوراق واقلام	<ul style="list-style-type: none">• محاضرة• مناقشة• سؤال وجواب	10

المادة العلمية:

○ sense and sensory system

○ The sensory system serves to protect the individual by detecting changes in the environment. The sensory system consist of general and special sense organs.

A- **The special sensory system**: are localized in special sense organs those for light, sound, and chemicals; where from this organs stimuli travels for specific area for each stimuli.

B- **The general sensory system**: The receptors of this sensory system are widely distributed throughout the body, as those receptors for pain, touch, and temperature, from these receptors the stimuli travel by sensory afferent nerves to the CNS to the sensory area at parietal lobe where interpreted as sensation.

○ A- The specific senses:

1- the vision and the eye:

○ The eye is a delicate organ which exist in eye cavities in the front of the skull protected by “eye protection”:-

○ 1- the skull bones form the eye orbit “cavity”. ○ 2-

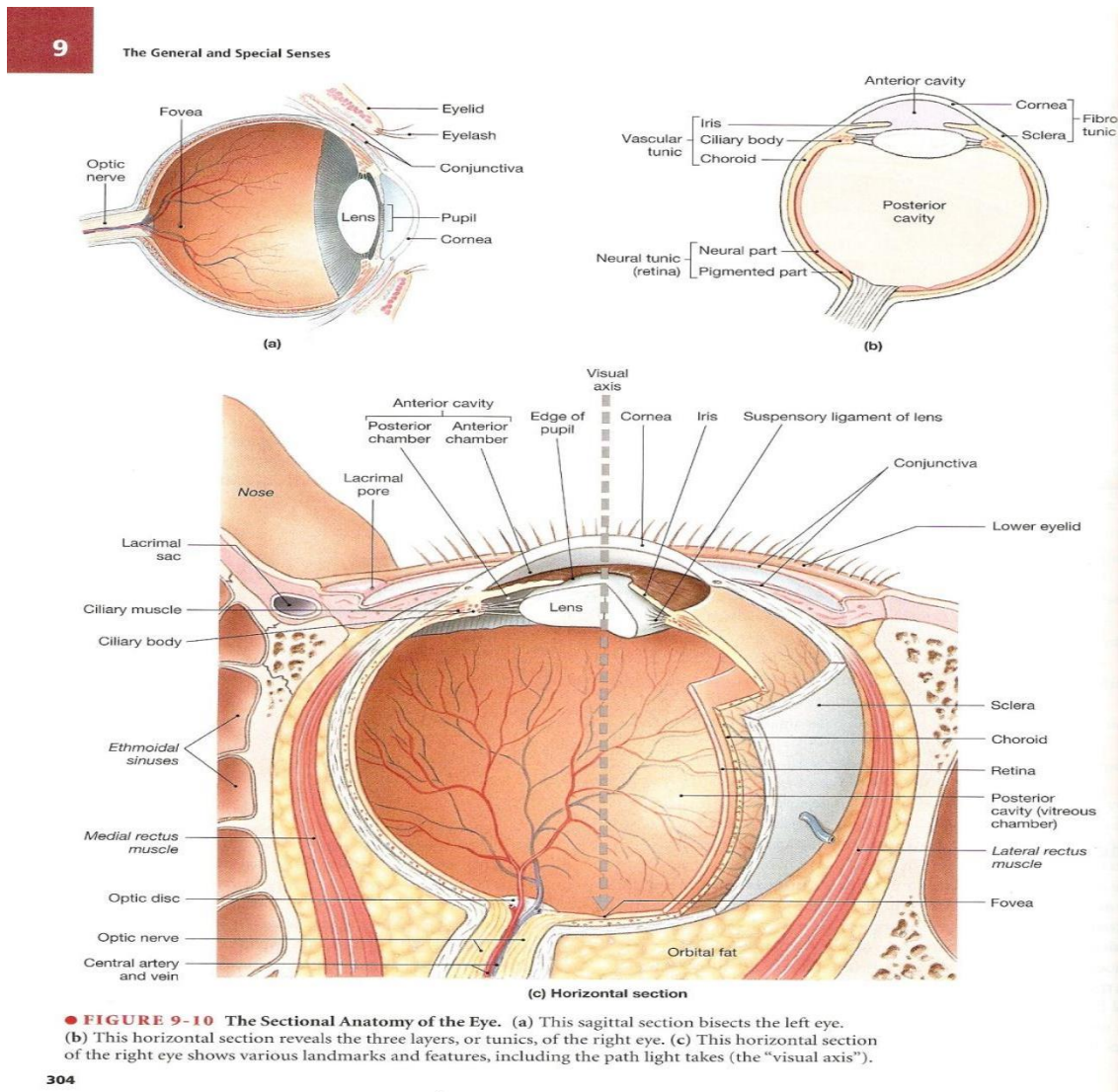
the led and eyelashes protected eye anteriorly;

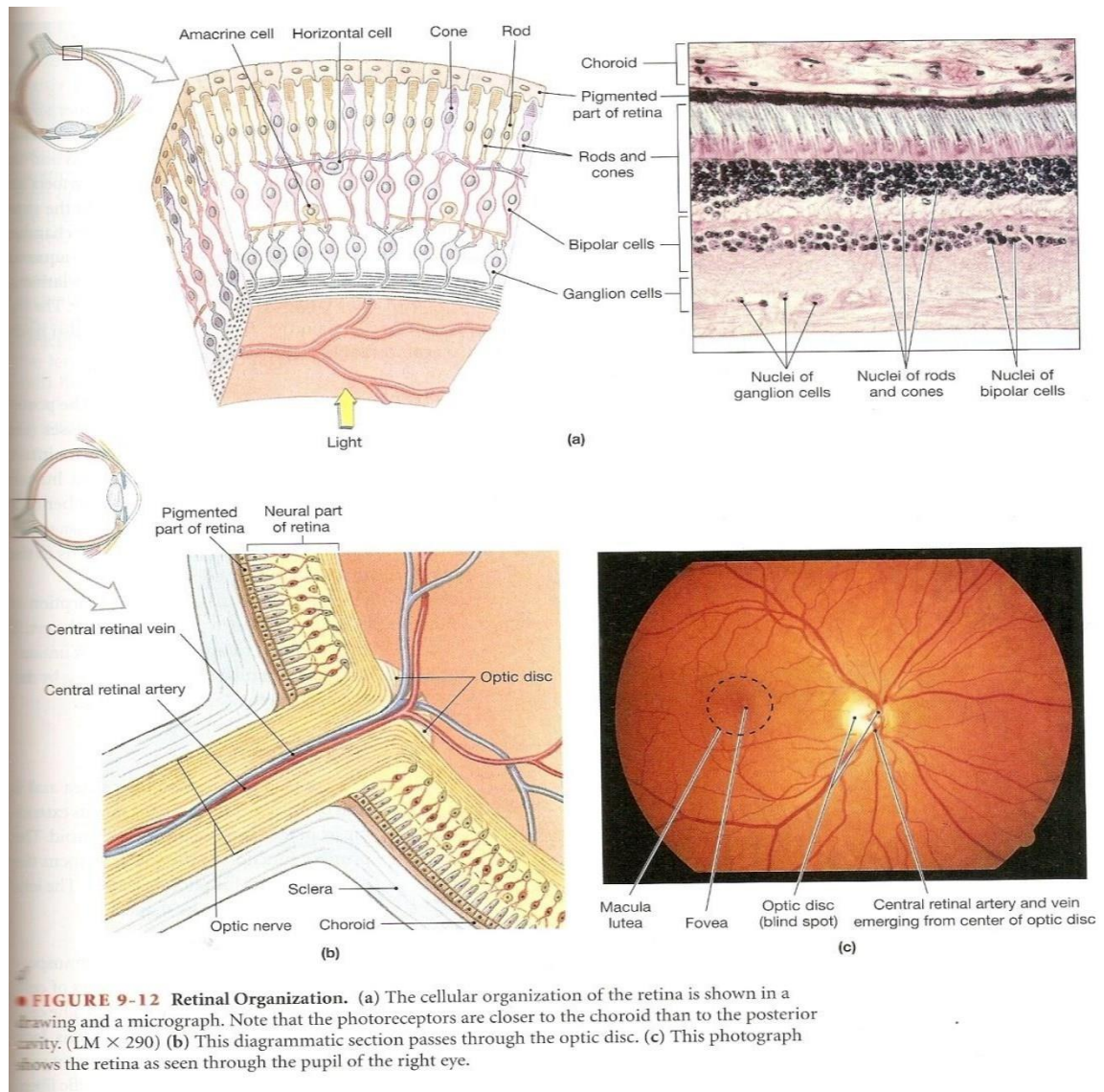
○ 3- tears wash away small foreign object that enter the eye.

- 4- a sac lined with an epithelial membrane, aids in the destruction of some pathogenic bacteria.
- **1-1- coats of the eye**
- The eyeball has three separate coats, or tunics:-
- **1- sclera**: is the outermost layer, is made of tough connective tissue to protect inner layers of the eye and also called the white of the eye.
- **2- choroid**: is the second layer composed of delicate network of connective tissue with many blood vessels, this layer contain much dark pigment serve as the dull black lining of a camera to prevent incoming light rays from scattering and reflecting of the inner surface of the eye.
- **3- retina**: is the innermost layer, is made of ten layers of nerve cells sensitive to light “photoreceptor”.
- One of these cells are called Rods (زئلق, يصرع), are very light-sensitive enable us to see in dimly lit rooms.

○ And the others are Cons (طير اخم) provide us with color vision “sensitive for red, green, and blue light”. So person who completely lack of Cones are totally color blind(In males only).

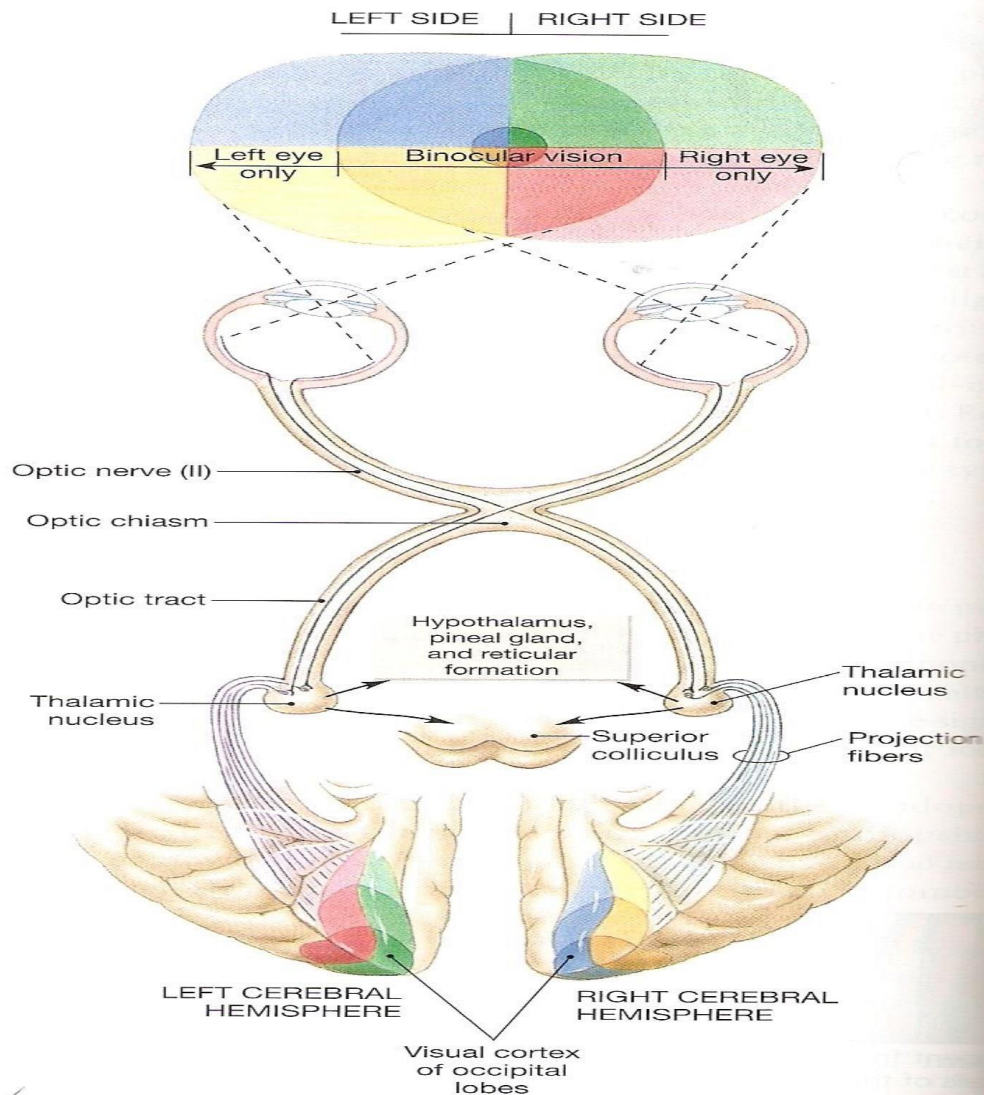
○ Rods and Cons functions by means of pigments that are sensitive to light, manufacturing of this pigment requires vitamin A, in case of lack of vitamin A, person developed night blindness.





○ **1-1-1- vision pathway**

○ The light rays come through cornea and lens stimulate the Rods and Cons to produce nerve signals that conducted by optic nerve(N II) to be interpreted by the cortex of occipital lobe at visual area.



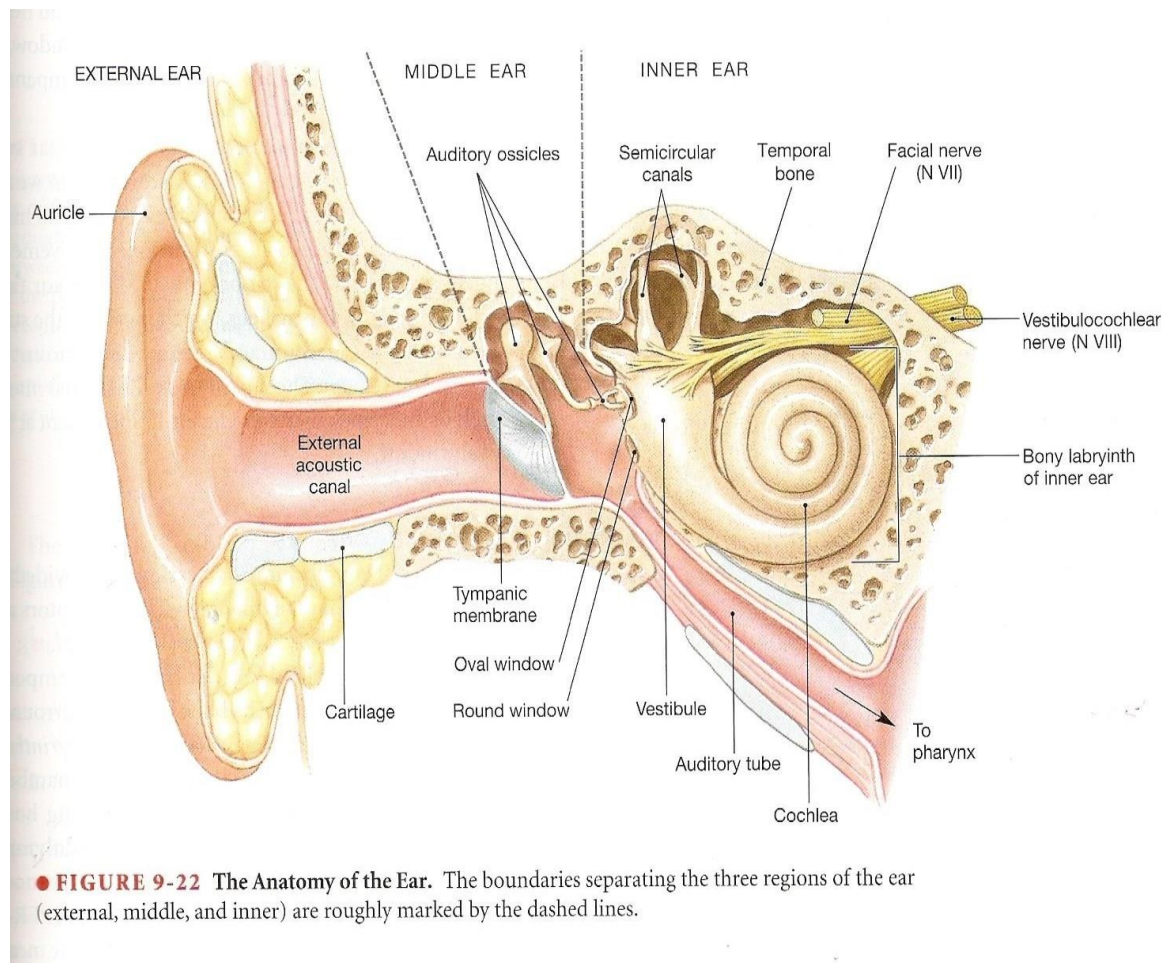
✓
● FIGURE 9-21 The Visual Pathway. At the optic chiasm, a partial crossover of nerve fibers occurs. As a result, each hemisphere receives visual information from the lateral half of the retina on that side and from the medial half of the retina on the opposite side. Visual association areas in the cerebrum integrate this information to develop a composite picture of the entire visual field.

○ **2- the hearing and the ear**

○ The ear is the sense organ related to both hearing and equilibrium “balance”. It may be divided into three main sections:

○ **2-1-The external ear:** it contain the auricle, the external auditory canal “meatus”, and the tympanic membrane (

○ Their function is to collect sound wave and directed them to middle ear.



○ **2-2- the middle ear:**

- It is a small, flattened space that contains air (air enters the cavity there connection as follow:-

 - Tympanic membrane malleus
 - incus stapes the membrane of the oval window.

- Middle ear function:- to amplify the sound waves that received by tympanic membrane and then transmit the sound to the fluid in the internal ear.

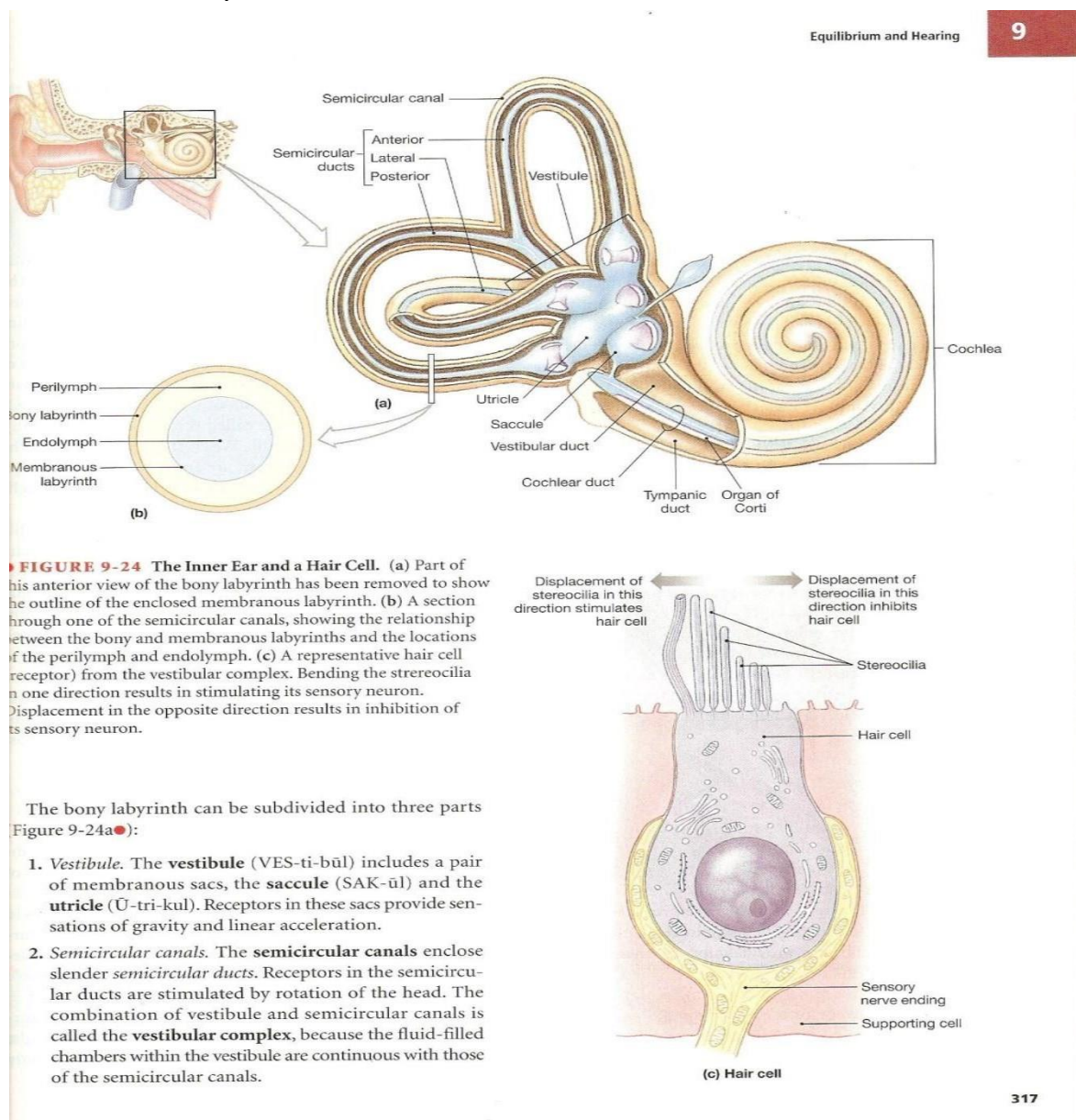
○ **2-3- the inner ear:**

○ It's the most complicated and important part of the ear. Its consist of :-

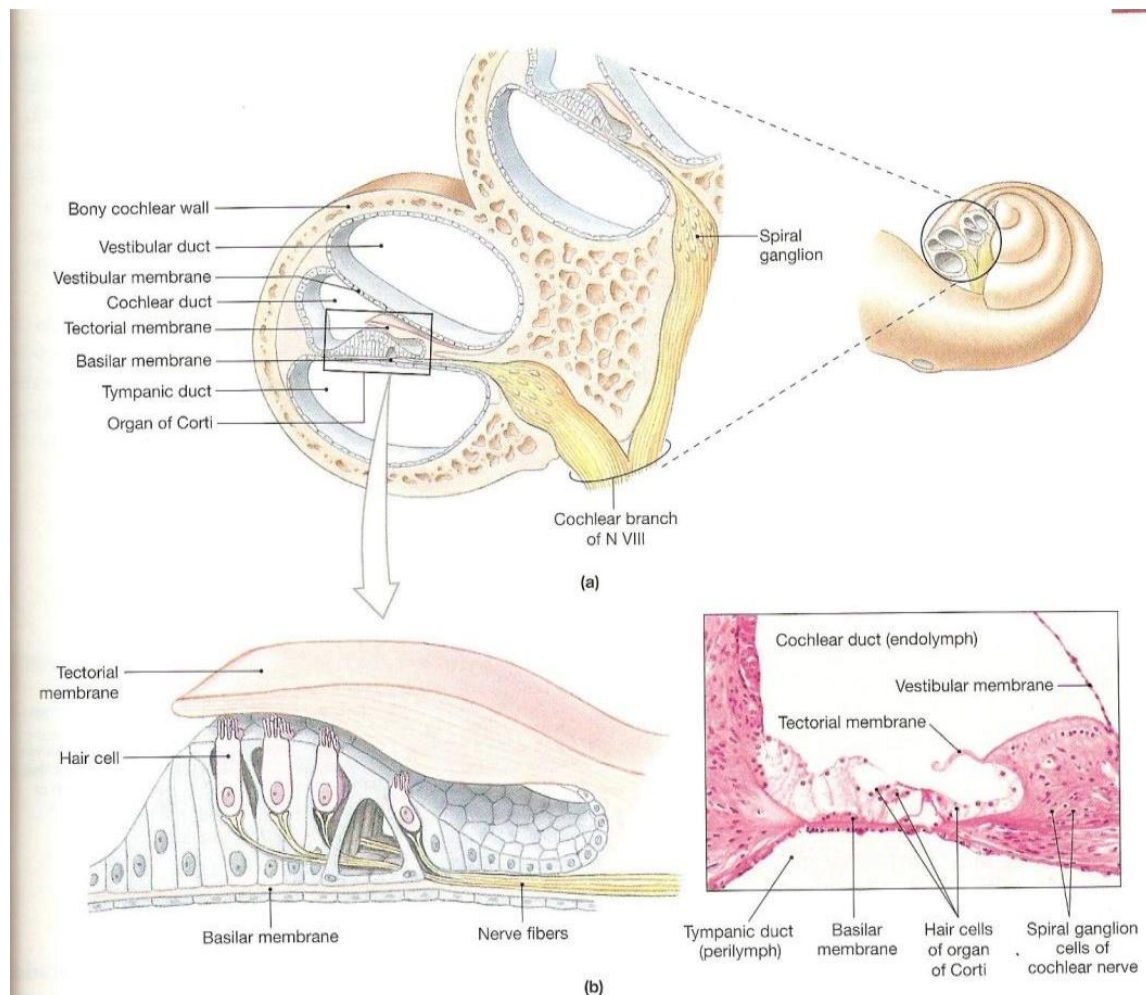
○ 1- Bony labyrinth which divided in three parts " vestibule, cochlea, and the semicircular canals(Its filled with fluid, called perilymph.

○ 2- Membranous labyrinth(are localized inside the Bony labyrinth(Bony labyrinth surrounds and protects it), its filled with a fluid called endolymph.

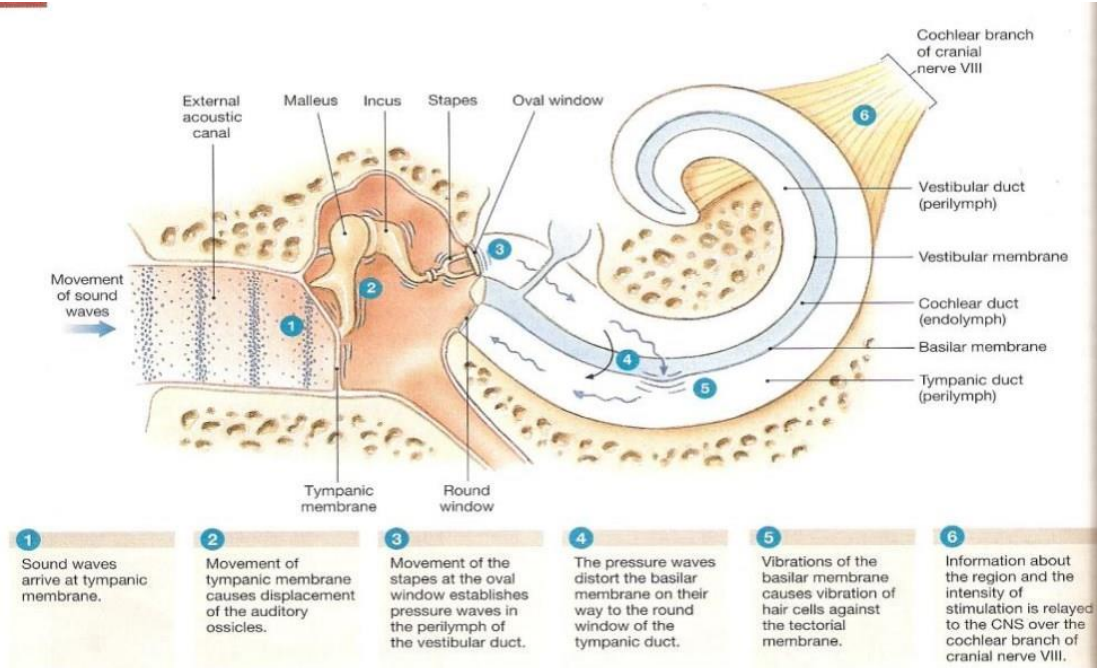
○ Both vestibule and semicircular canals have receptors which provide sensation of gravity, linear acceleration, and equilibrium. They are stimulated by rotation of head.



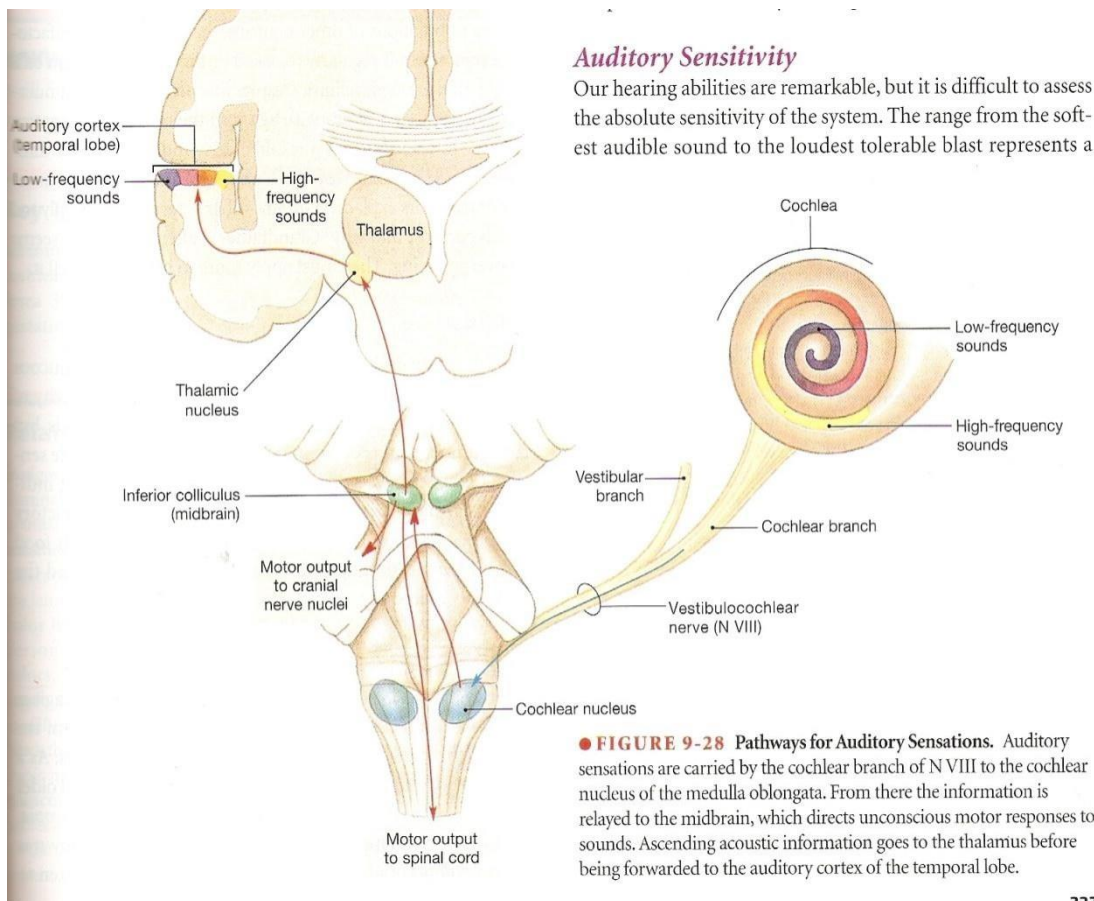
- The cochlea contain receptors for hearing by organ of Corti which stimulated by sound wave that conduct by ossicles of middle ear to the internal ear, which creates pressure waves within perilymph; this pressure waves will stimulates receptors of hearing to send electrical signal through the fibers of sensory neuron of the internal ear, these fibers form the vestibulocochlear nerve.
- vestibulocochlear nerve conduct sensation of equilibrium to the vestibular nuclei in the brain stem, and hearing sensation to the cortex of temporal lobe “auditory cortex” where these sound signal interpreted as hearing sensation .



● **FIGURE 9-26** The Cochlea and Organ of Corti. (a) A section of the cochlea reveals its internal structures, including the organ of Corti. (b) The drawing shows the three-dimensional structure of the tectorial membrane and hair cell complex of the organ of Corti; the photomicrograph shows the actual structures. (LM \times 1233)



● **FIGURE 9-27 Sound and Hearing.** This drawing presents the steps in the reception of sound and the process of hearing.



○ **3- sense of taste:**

○ The sense of taste involves receptors in the tongue, by two different nerves carry impulses to the brain, “ anterior 2/3 of the tongue by facial nerve, and the posterior 1/3 of the tongue by glossopharyngeal nerve.

○ The taste receptors, known as taste buds (تذوقية مع راب), are located along the edges of small depressed area called fissures (قو قش). Taste buds are stimulated only if the substance to be tasted is in solution.

Taste can be divided into four kinds:-

○ 1- sweet tastes: present at the tip of the tongue.

○ 2- sour tastes: present at the side of the tongue.

○ 3- salty tastes: present at the tip of the tongue.

○ 4- bitter tastes: present at the back part of the tongue.

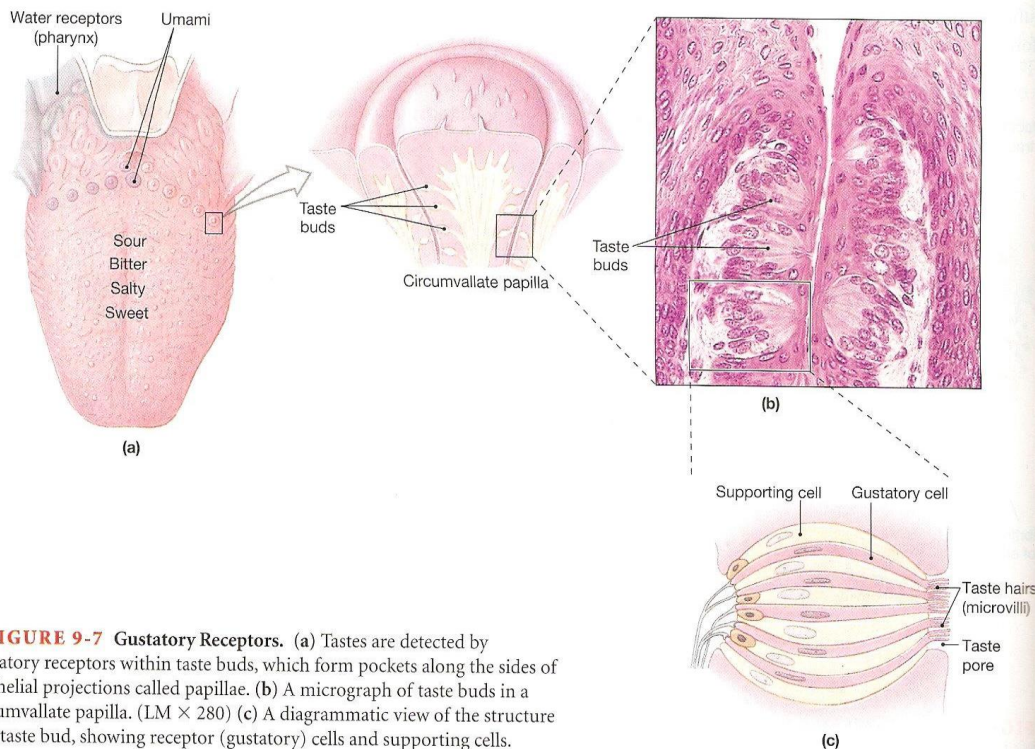
○ The impulses of the taste are interpreted by the front portion of the brain.

■ **Taste**

Taste receptors, or *gustatory* (GUS-ta-tor-ē) receptors, are distributed over the surface of the tongue and adjacent portions of the pharynx and larynx (Figure 9-7). The most important taste receptors are on the tongue; by the time we

rounding fluids through a narrow opening, the **taste pore**. The mechanism behind gustatory reception seems to parallel that of olfaction. Dissolved chemicals contacting the taste hairs stimulate a change in the membrane potential of the taste cell, which leads to action potentials in the sensory neuron.

You are probably already familiar with the four **primary taste sensations**: sweet, salty, sour, and bitter. There is some

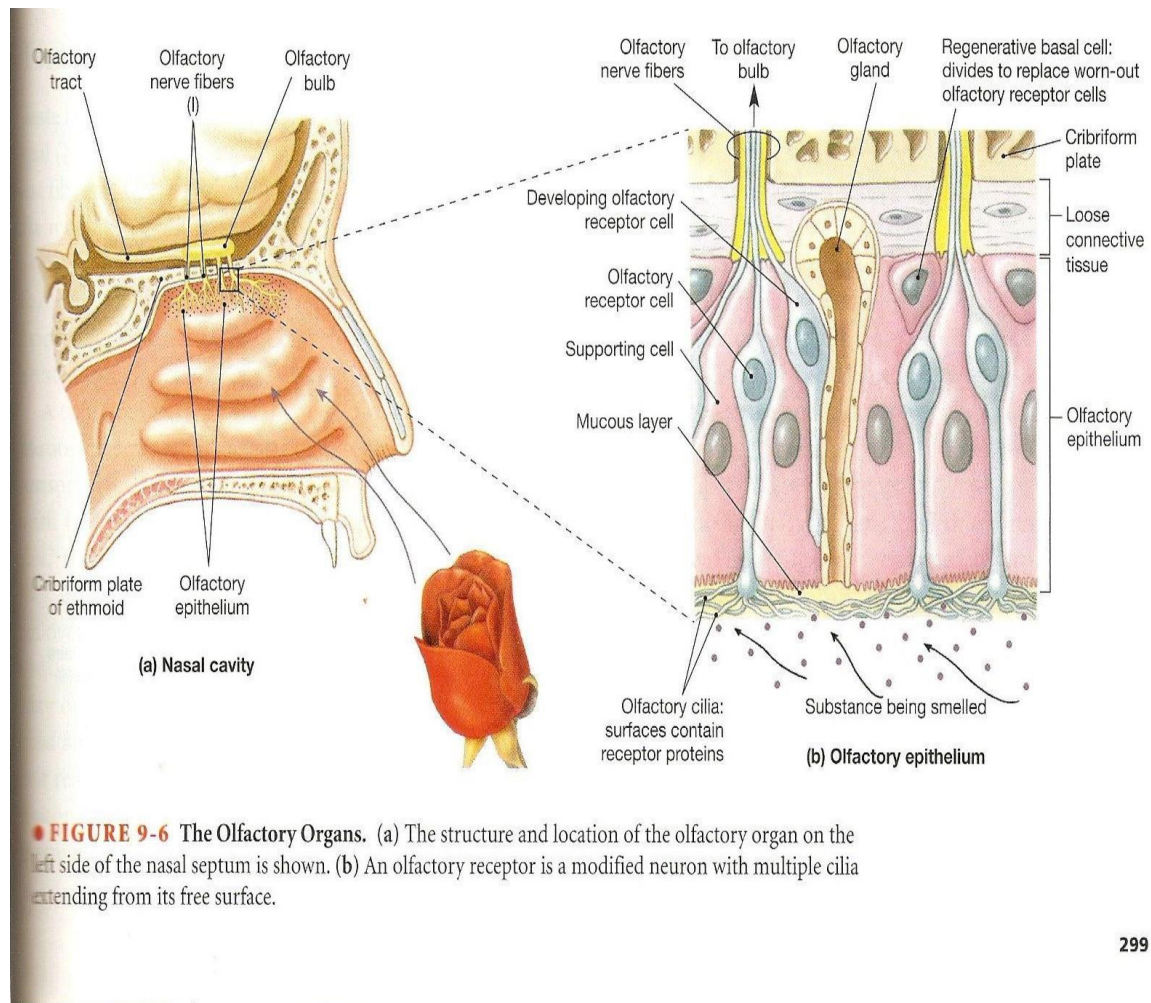


● **FIGURE 9-7** Gustatory Receptors. (a) Tastes are detected by gustatory receptors within taste buds, which form pockets along the sides of epithelial projections called papillae. (b) A micrograph of taste buds in a circumvallate papilla. (LM × 280) (c) A diagrammatic view of the structure of a taste bud, showing receptor (gustatory) cells and supporting cells.

○ 4- sense of smell:

○ The receptors of smell are located in the olfactory epithelium containing olfactory receptor cells, neurons are sensitive to chemicals dissolved in the overlying mucosa.

○ Approximately 10-20 million olfactory receptors cells are packed into an area of roughly 5 cm² . The information from these receptors are interpreted by the brain as sensation of smell at olfactory cortex in the temporal lobe.



299

○ The general sense:

○ Receptors for general senses are scattered throughout of the body and are relatively simple in structure. These receptors are classified according to the nature of the stimulus that excites them, these are:

○ 1- receptors sensitive to pain “nociceptors”.

○ 2- receptors sensitive to temperature “ thermoreceptors”.

الوحدة الحادية عشر/الثانية عشر - الزمن: 120 دقيقة

أهداف المحاضرة الحادية عشر:

sensory and motor يتوقع في نهاية الجلسة أن يكون الطالب قادراً على معرفة integrative function

الأساليب والأنشطة والوسائل التعليمية

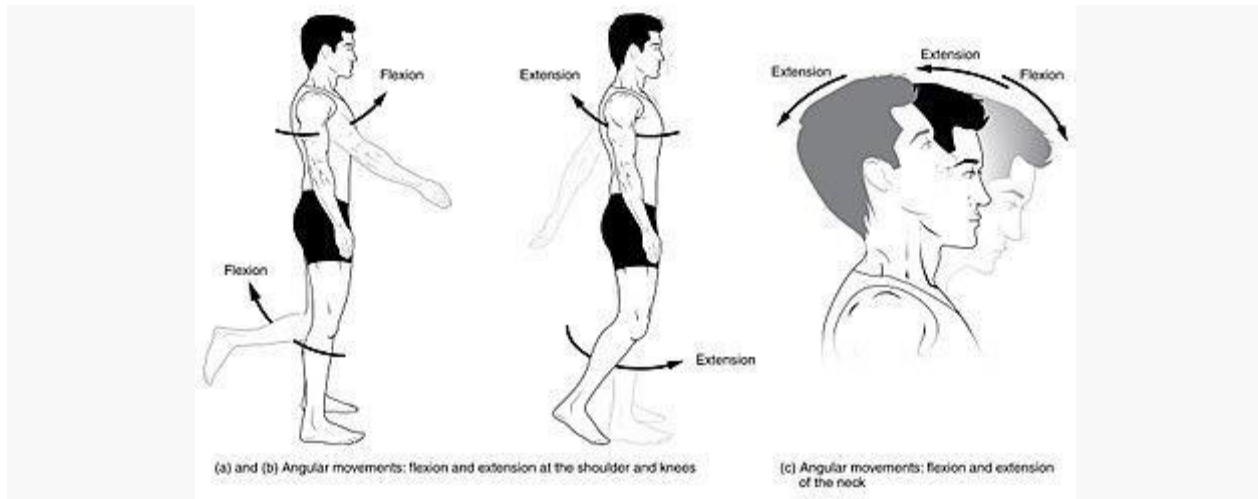
الوسائل التدريسية	الأساليب والأنشطة التدريسية	م
<ul style="list-style-type: none">• جهاز حاسوب• جهاز عرض• سبورة• اوراق واقلام	<ul style="list-style-type: none">• محاضرة• مناقشة• سؤال وجواب	11

المادة العلمية:

General motion :

These are general terms that can be used to describe most movements the body makes.
Most terms have a clear opposite, and so are treated in pairs.

1- Flexion and extension

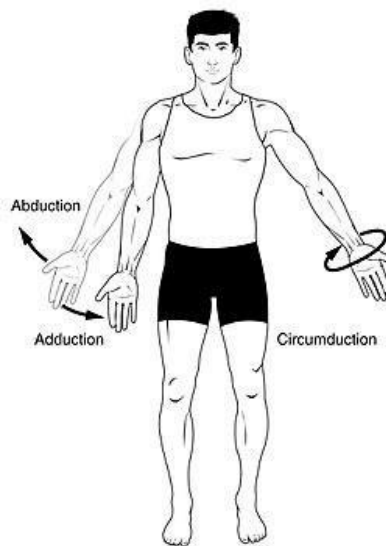


Flexion describes a bending movement that *decreases* the angle between a segment and its proximal segment. For example, bending the **elbow** . When sitting down, the knees are **flexed**.

Extension is the opposite of flexion, describing a straightening movement that *increases* the angle between body parts. For example, when standing up, the knees are extended.

2- Abduction and adduction

Abduction is the motion of a structure away from the midline while adduction refer to motion towards the center of the body.



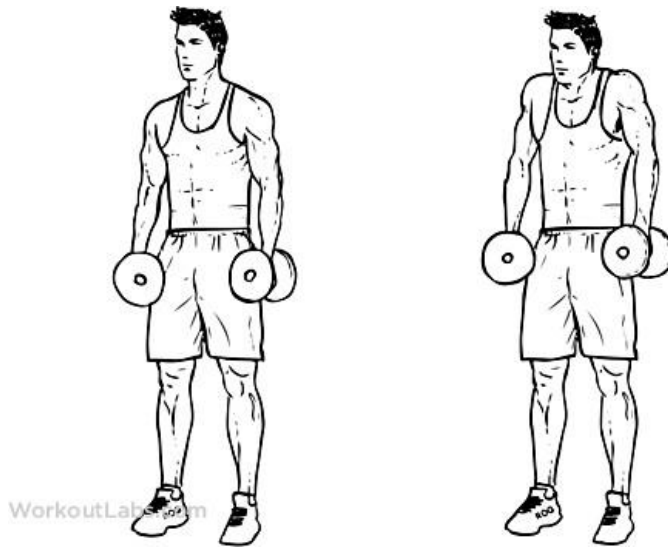
(e) Angular movements: abduction, adduction, and circumduction of the upper limb at the shoulder (f)

3- Elevation and depression

The terms elevation and depression refer to movement above and below the horizontal.

For example, **shrugging** is an example of elevation of the scapula. **direction. superior** a movement in **Elevation** is

Depression is movement in an inferior direction, the opposite of elevation.



4- Rotation

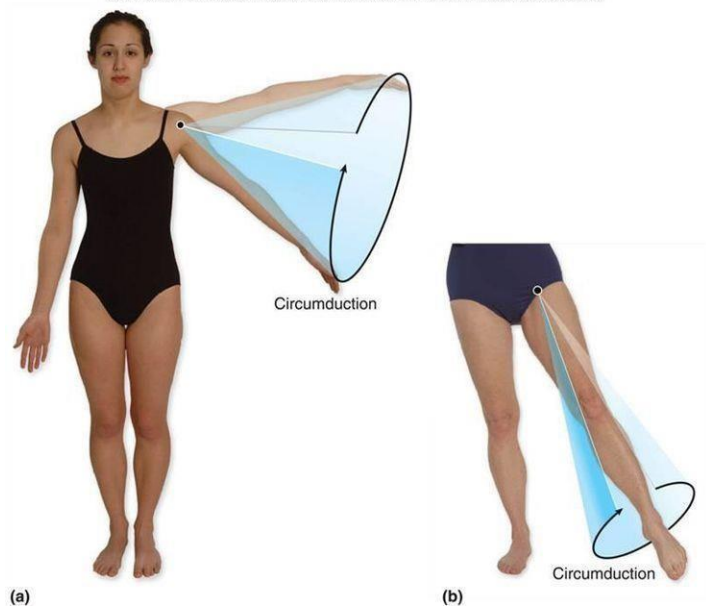Rotation of body parts is referred to as internal or external, referring to rotation towards or away from the center of the body.

Internal rotation (or medial rotation) is rotation towards the axis of the body.

External rotation (or lateral rotation) is rotation away from the center of the body.

5- Circumduction

is a conical movement of a body part, such as a ball and socket joint or the eye. Circumduction is a combination of flexion, extension, adduction and abduction. Circumduction can be best performed at ball and socket joints, such as the hip and shoulder, but may also be performed by other parts of the body such as fingers, hands, feet, and head. For example, circumduction occurs when spinning the arm when performing a serve in tennis or bowling a cricket ball.

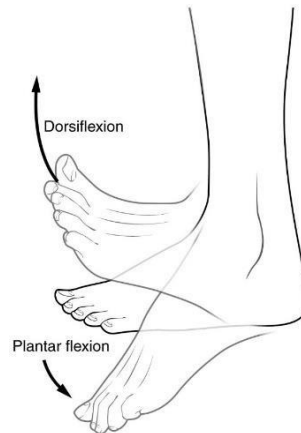

Special motion Feet and

Hand:

Dorsiflexion : This decreases the angle between the dorsum of the foot and the leg. For example, when walking on the heels the ankle is described as being in dorsiflexion.

Plantar flexion or plantarflexion is the movement which decreases the angle between the sole of the foot and the back of the leg; for example, the movement when depressing a car pedal or standing on tiptoes.



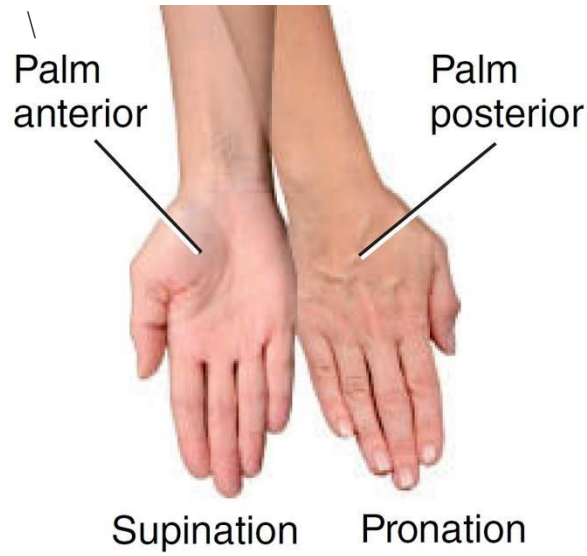
Palmarflexion is decreasing the angle between the palm and the anterior forearm.

Dorsiflexion is extension at the ankle or wrist joint. This brings the hand closer to the dorsum of the body.

Others :

Pronation at the forearm is a rotational movement where the hand and upper arm are turned inwards.

Supination of the forearm occurs when the forearm or palm are rotated outwards.

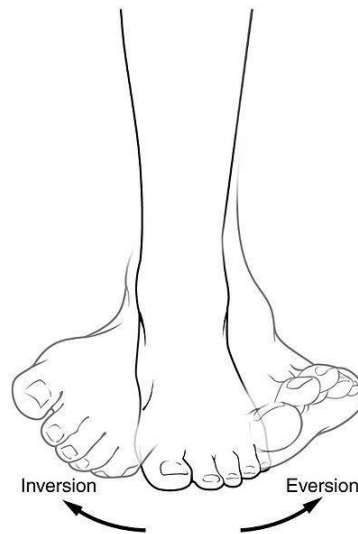

Inversion and eversion:

Inversion and eversion refer to movements that tilt the sole of the foot away from (eversion) or towards (inversion) the midline of the body.

***Eversion* is the movement of the sole of the foot away from the median plane.**

***Inversion* is the movement of the sole towards the median plane. For example, inversion describes the motion when an ankle is twisted.**



أهداف المحاضرة الثالثة عشر:

يتوقع في نهاية الجلسة أن يكون الطالب قادراً على معرفة ماهو endocrine
الأساليب والأنشطة والوسائل التعليمية

الوسائل التدريبية	الأساليب والأنشطة التدريبية	م
<ul style="list-style-type: none">• جهاز حاسوب• جهاز عرض• سبورة• اوراق واقلام	<ul style="list-style-type: none">• محاضرة• مناقشة• سؤال وجواب	13

المادة العلمية: endocrine system

— The nervous system and the endocrine system are the two main coordinating and controlling systems of the body. There are several differences between these two systems.

Nervous system	Endocrine system
1- Acts by mean of electric impulses and chemical stimuli.	1-Acts by mean of chemical stimuli only.
2- Has an immediate and short-term effect on muscles and glands.	2- Has more widespread, slower and longer lasting effect.
3- Has relatively localized effects.	3- Has more generalized effects on such activities as (growth, metabolism, reproduction)

— 1- Hormones:

— They are chemicals messengers released by glands of endocrine system directly into the blood stream. Every hormone has specific cell receptor and target tissue:-

-Receptor:- it's the site at which the hormones attach on the affected cells.

-Target tissue:- it's the tissue that responding to the effect of hormones.

— 1-1- hormones chemistry:-

— Hormones fall chemically into two categories:-

A- protein hormones:- its composed of amino acids, all hormones are protein except those of adrenal cortex and sex glands.

B- steroid hormones:- its derived from lipids and produced by the adrenal cortex and sex glands.

— **-2-1- Hormones action:**

— **A- most protein hormones** do not enter the target cell, instead, they attach to the surface and activate another substance “second messenger” that alter the cell activity.

— **B- steroid hormones**:- can pass through the cell membrane and enter the target cell, then they combine with receptors and enter

the nucleus; here they have direct effect on the DNA, thus altering the activity of the cell.

— **In general**, the effect of hormones is to change the rate of protein manufacture in the cytoplasm.

— **-3-1- Hormones regulation:**

— The release of hormones is controlled by:-

— **1- negative feedback system**:- a stimulus triggers the production of a hormone whose direct or indirect effects reduce the intensity of the stimulus. The endocrine activity may be controlled by changes in the composition of the extracellular fluid, for example, the control of blood calcium levels by two hormones, parathyroid hormone and calcitonin. When calcium levels in the blood decline, parathyroid hormone is released, and the responses of target cells elevate blood calcium levels. When calcium levels in the blood rise, calcitonin is released, and the responses of the target cells lower blood calcium levels.

— **2- hormonal stimuli**:- by changes in the levels of circulating hormones. Such control may involve one or more intermediary steps and two or more hormones, e.g. by releasing hormones from hypothalamus it control the activity of endocrine organs.

— **3- neural stimulation**:- resulting from the arrival of neurotransmitter at a neuroglandular junction as the activity of the hypothalamus on the adrenal medullae causes the release of epinephrine.

— **-2- The endocrine system:**

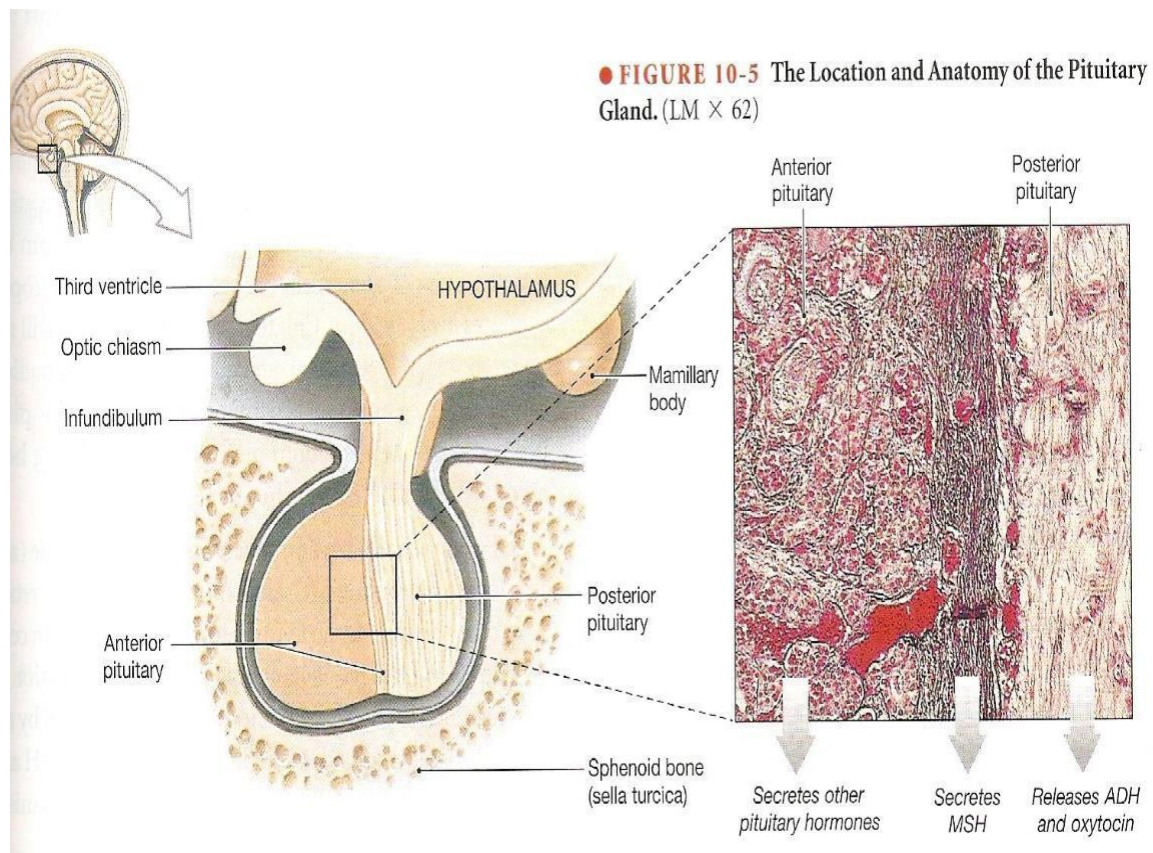
— It consist of ductless glands which secrete hormones directly in the bloodstream. These glands are made of epithelial tissue with

extensive blood vessels network.

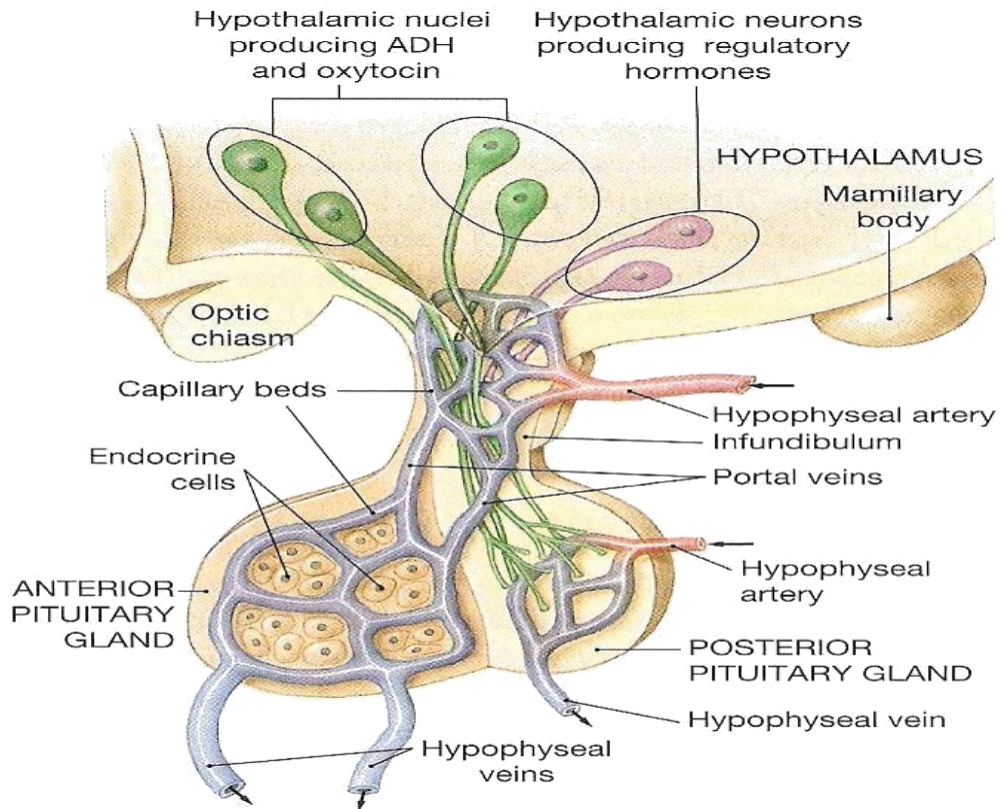
— **-3- The endocrine glands and their hormone:**

-3-1- The pituitary gland" hypophysis— Is a small gland about the size of a cherry located in a saddle-like depression of the sphenoid bone (بينيفسلا مطعلا) just behind the point at which the optic nerves cross.

— The pituitary gland is often called the master gland because it releases hormones that affect the working of other glands, such as “thyroid, adrenal, gonads glands”.



— Their secretion is controlled by hypothalamus which secrete “releasing factors or hormones”, through portal system to control secretion of anterior pituitary gland, while posterior pituitary gland control by direct nerve impulse from hypothalamus.



● **FIGURE 10-6** The Hypophyseal Portal System and the Blood Supply to the Pituitary Gland.

— **1-1-3- Hormones of the anterior lobe:**

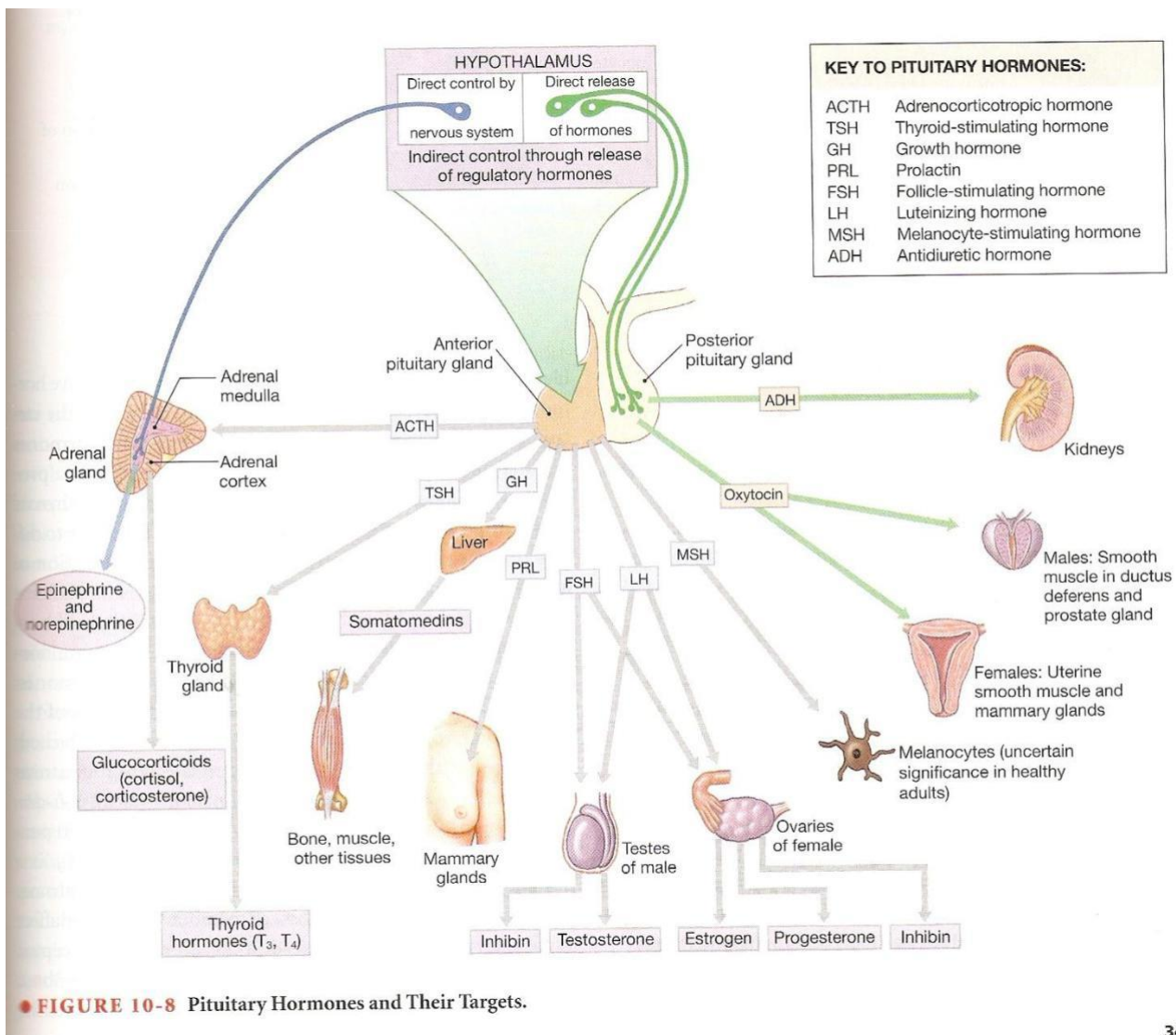
- 1- growth hormone(GH) or somatotropic hormone which promotes growth of all body tissues.
- 2- thyroid-stimulating hormone(TSH), or thyrotropic hormone which stimulates thyroid gland to produce thyroid hormones.
- 3- adrenocorticotrophic hormones(ACTH), which stimulates adrenal cortex to produce cortical hormones; aids in protecting body in stress situations (injury, pain).
- 4- Gonadotropic hormones: exist two hormones;
 - A- follicle-stimulating hormone (FSH), which stimulates growth and hormone activity of ovarian follicles in female; stimulates growth of testes. Promotes development of sperm cells.
 - B- luteinizing hormone (LH), called in male interstitial cell-stimulating hormone(ICSH), which causes development of corpus luteum at site of ruptured ovarian follicle in female; stimulates secretion of testosterone in male.

— 5- Prolactin (PRL), which stimulates secretion of milk by mammary gland

— **3-1-2 hormones of the posterior lobe:**

— 1- antidiuretic hormone; vasopresin(ADH), which promotes reabsorption of water in kidney tubules; stimulates smooth muscle tissue of blood vessels to constrict.

— 2- oxytocin, which causes contraction of muscle of uterus; causes ejection of milk from mammary glands.



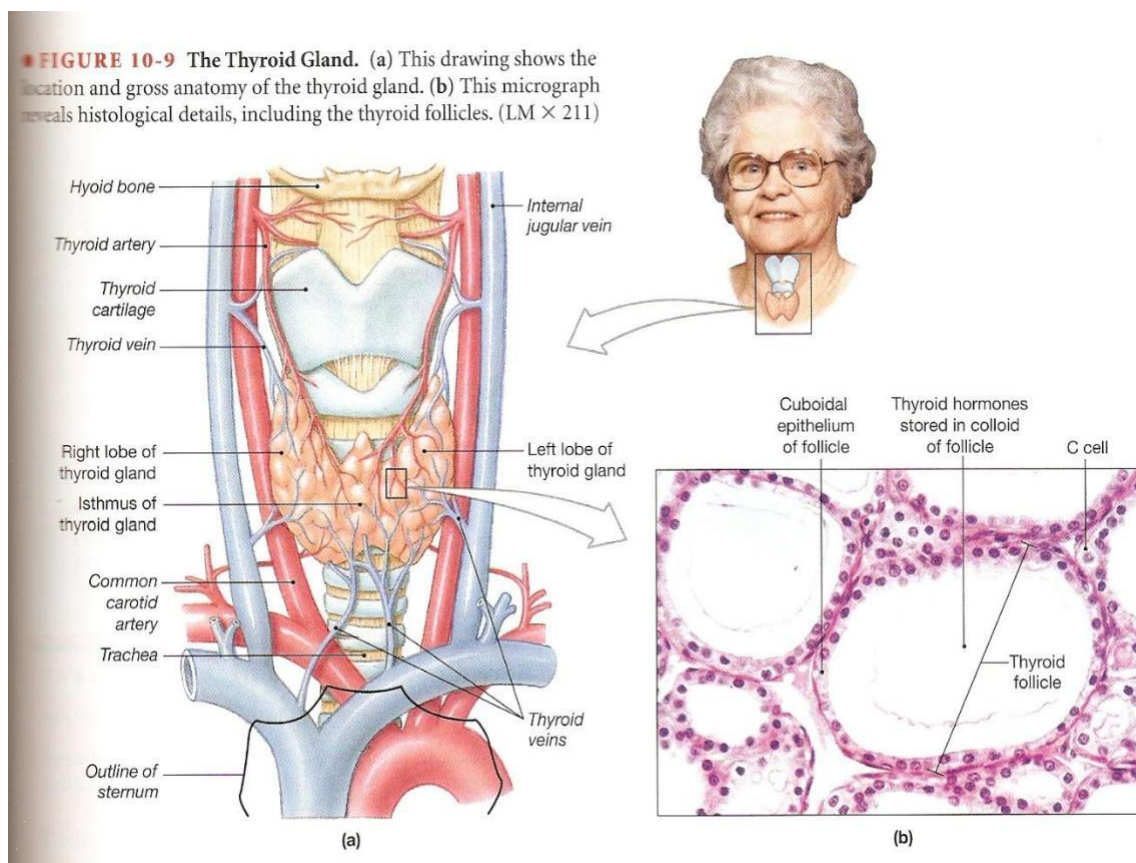
3-2- The thyroid gland:

- The largest gland in the body located in the front of the neck; have to lateral lobes connected by narrow band called isthmus.

Thyroid

gland secretes two hormones:-1

- 1- thyroxine (T4) and tri-iodothyronine(T3)hormone; which increases metabolic rate, influencing both physical and mental activities; required for normal growth.
- 2- Calcitonin: decreases calcium level in blood.



3-3- Parathyroid glands:

- parathyroid glands are two tiny pairs embedded in the posterior surfaces of the thyroid gland. The chief cells secrete parathyroid hormones, which regulate the exchange of calcium between blood and bones; increase calcium level in the blood.

الوحدة الرابعة عشر /الخامسة عشر- - الزمن: 120دقيقة

أهداف المحاضرة الرابعة عشر/خامسة عشر :

يتوقع في نهاية الجلسة أن يكون الطالب قادراً على معرفة ماهو/ blood-cardiovascular system

الأساليب والأنشطة والوسائل التعليمية

م	الأساليب والأنشطة التدريسية	الوسائل التدريسية
14	• محاضرة • مناقشة • سؤال وجواب	• جهاز حاسوب • جهاز عرض • سبورة • اوراق واقلام

المادة العلمية:

Blood vessels:

- The blood vessels, together with for heart chambers form a closed system for the flow of blood. On the basis of function; the blood vessels may be divided into three groups;
- **Arteries**: carry blood from the ventricles of the heart out to the capillaries in organs and tissues. The smallest arteries are called arterioles.
- **Veins**: drain capillaries in the tissues and organs and return the blood on the heart. The smallest veins are the venules.
- **Capillaries**: allow for exchanges between the blood and body cells, or between the blood and air in the lung tissues. The capillaries connect the arterioles and venules.
- All vessels together may be subdivided into two groups of circuits: pulmonary and systemic circuits.
- **1- Pulmonary circuit**: these vessels carry blood to and from the lungs. This circuit functions to eliminate carbon dioxide from the blood and replenish its supply of oxygen.

- 2- systemic circuit: transports blood to and from the rest of the body.

2-1- The structure of blood vessels:

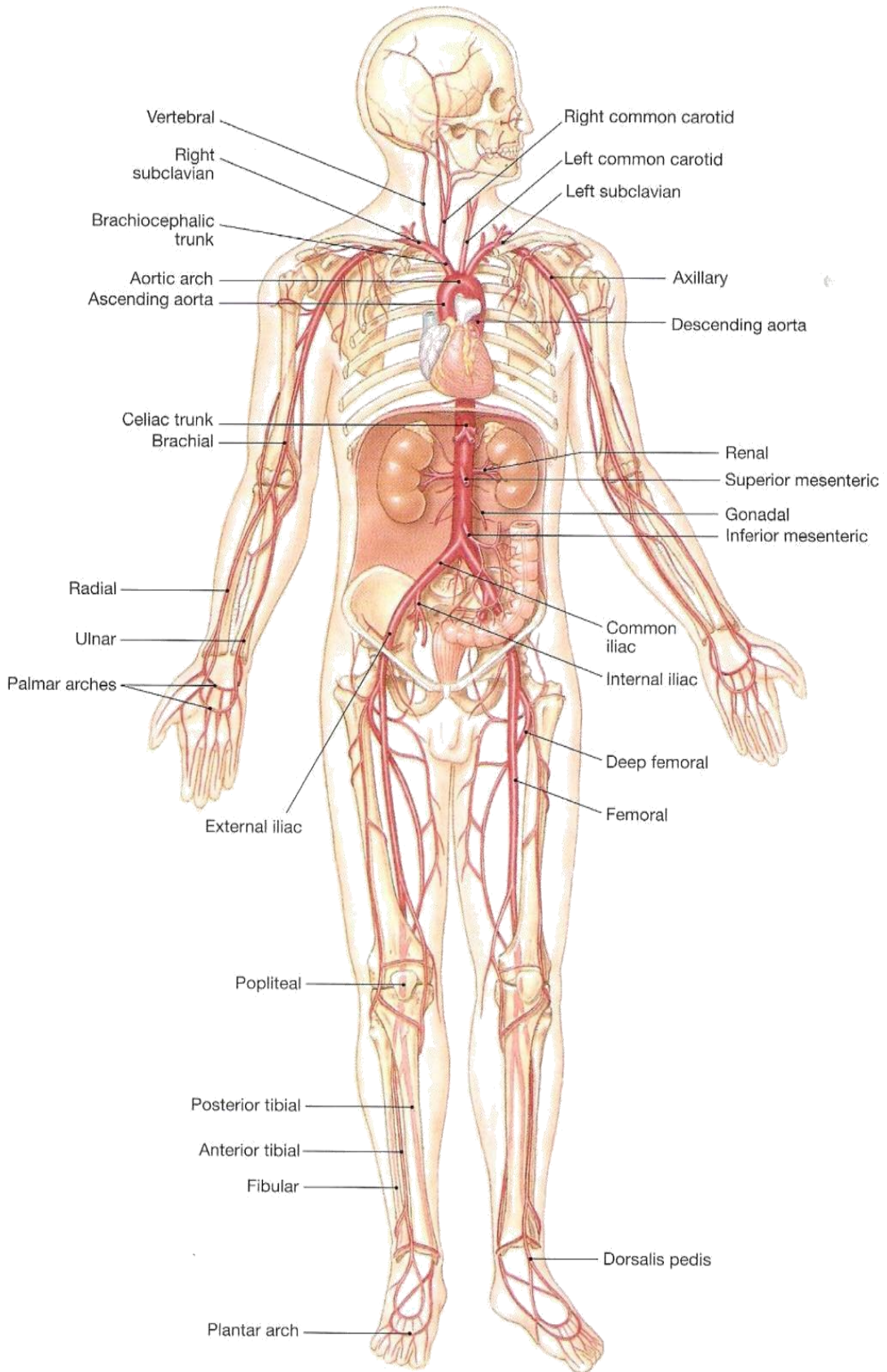
- A- The arteries and veins: have three coats(tunics) but arteries have thicker wall than veins because they must receive blood pumped under high pressure from the ventricles of the heart. The coats are:
 - 1- endothelium: is a flat epithelial cells making up the internal smooth surface over which the blood may easily move.

- 2- middle layer: more bulky layer is made of smooth involuntary muscle combined elastic connective tissue. In veins this layer is relatively thin, therefore, veins are easily collapsed. In addition to this, most veins have one-way valves that permit blood to flow in only one direction; toward the heart.
- 3- An outer tunic: is made of a supporting connective tissue.
- B- capillary walls: have the thinnest walls of any vessels; have only one cell layer “endothelium.

2-2- Names of the systemic arteries:

- The aorta and its parts: aorta is the largest artery, is about 2.5cm in diameter. It extends from the left ventricle. Aorta is one continuous artery, but it may be divided into sections:

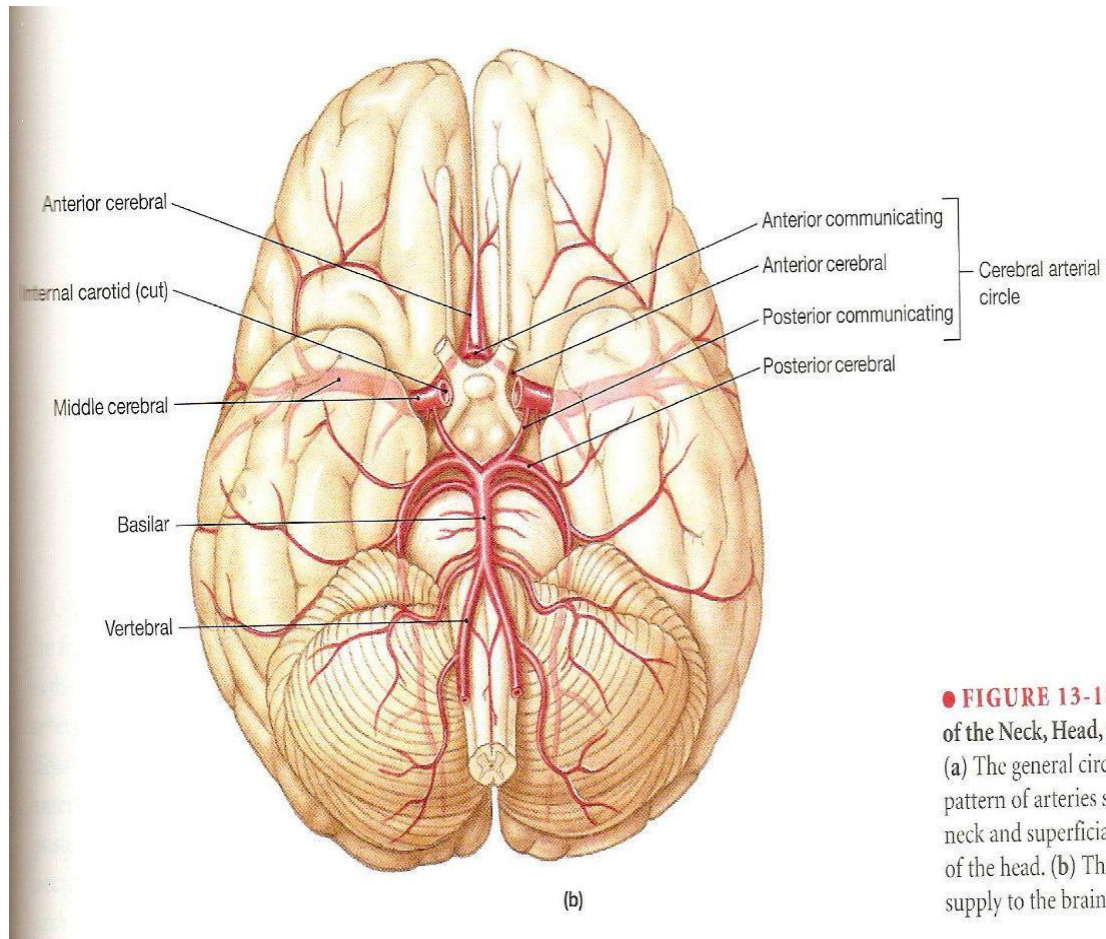
- 1- The ascending aorta(دعاصلا), is near the heart and give left and right coronary arteries to the heart muscle.
- 2- the aortic arch(يطرولاً سوق), is a curves from the right to the left also extends backward; gives off three large branches:
 - A- the brachiocephalic trunk (supply the right upper extremity and the right side of the head).
 - B- left common carotid artery(يجادولا supply left side of the head).
 - C- left subclavian artery "supply the left upper extremity.
- 3- the thoracic aorta, lies in front of thoracic vertebral column “supply the chest organ and thoracic wall”.
- 4- the abdominal aorta, lies in the abdominal cavity and supply the abdominal part of the body and both lower extremities.



● **FIGURE 13-15** An Overview of the Arterial System.

2-3- Anastomoses:

- Is a communication between two arteries, so blood reaches vital organs by more than one route. For example:
- 1- the circle of Willis; receives blood from the two internal carotid arteries as well as from the basilar artery, which is formed by the union of two vertebral arteries. This arterial circle lies just under the center of the brain and send branches to the cerebrum and other parts of the brain.
- 2- the volar arch; is formed between radial and ulnar arteries in the hand it send branches to the hand and fingers.



● **FIGURE 13-18** Arteries of the Neck, Head, and Brain. (a) The general circulation pattern of arteries supplying the neck and superficial structures of the head. (b) The arterial supply to the brain.

2-4

الوحدة السادسة عشر - المحاضرة السابعة عشر - الزمن: 120 دقيقة

أهداف المحاضرة السادسة عشر:

يتوقع في نهاية الجلسة أن يكون الطالب قادراً على معرفة ماهو heart

:

الأساليب والأنشطة والوسائل التعليمية

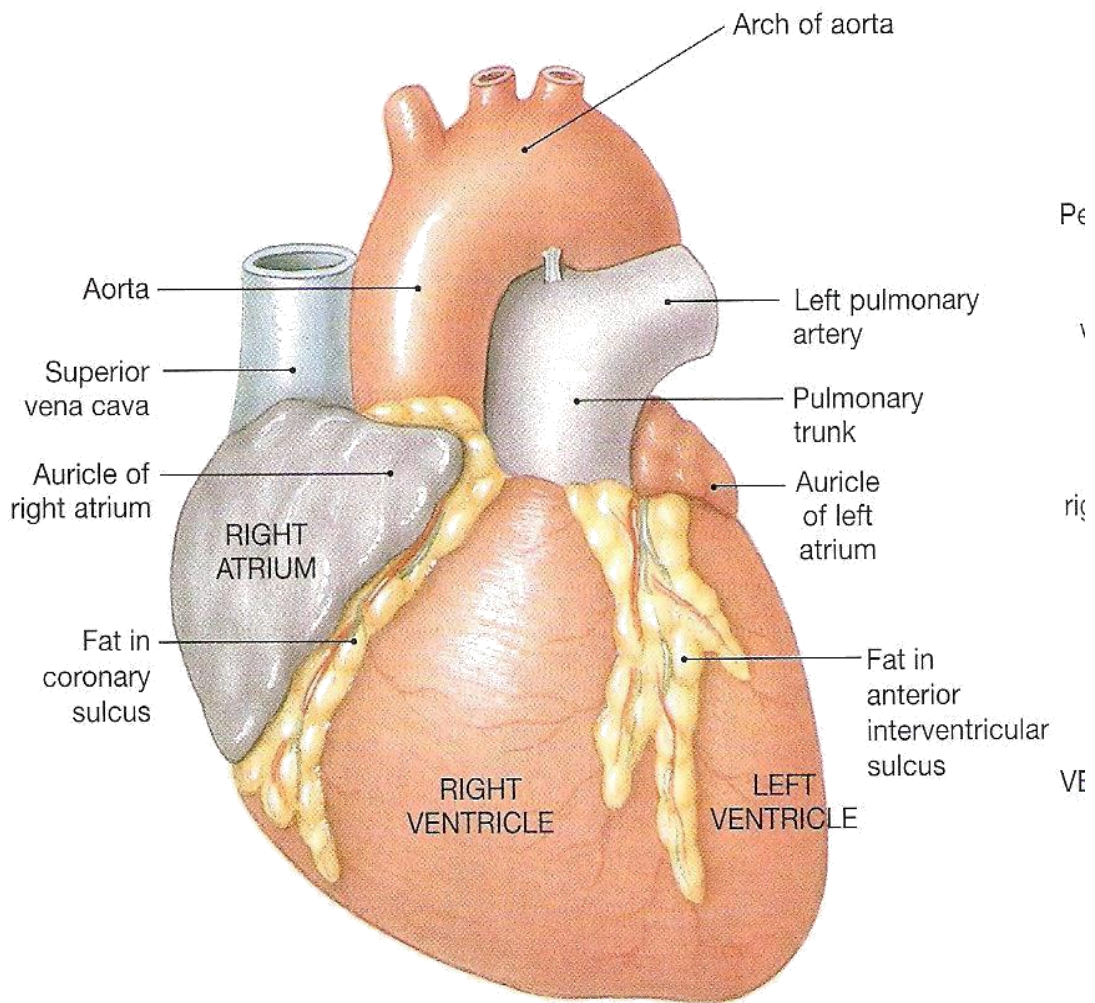
الوسائل التدريبية	الأساليب والأنشطة التدريبية	م
<ul style="list-style-type: none">• جهاز حاسوب• جهاز عرض• سبورة• اوراق واقلام	<ul style="list-style-type: none">• محاضرة• مناقشة• سؤال وجواب	16

المادة العلمية:

The cardiovascular system: consists of the heart, blood vessels, and blood.

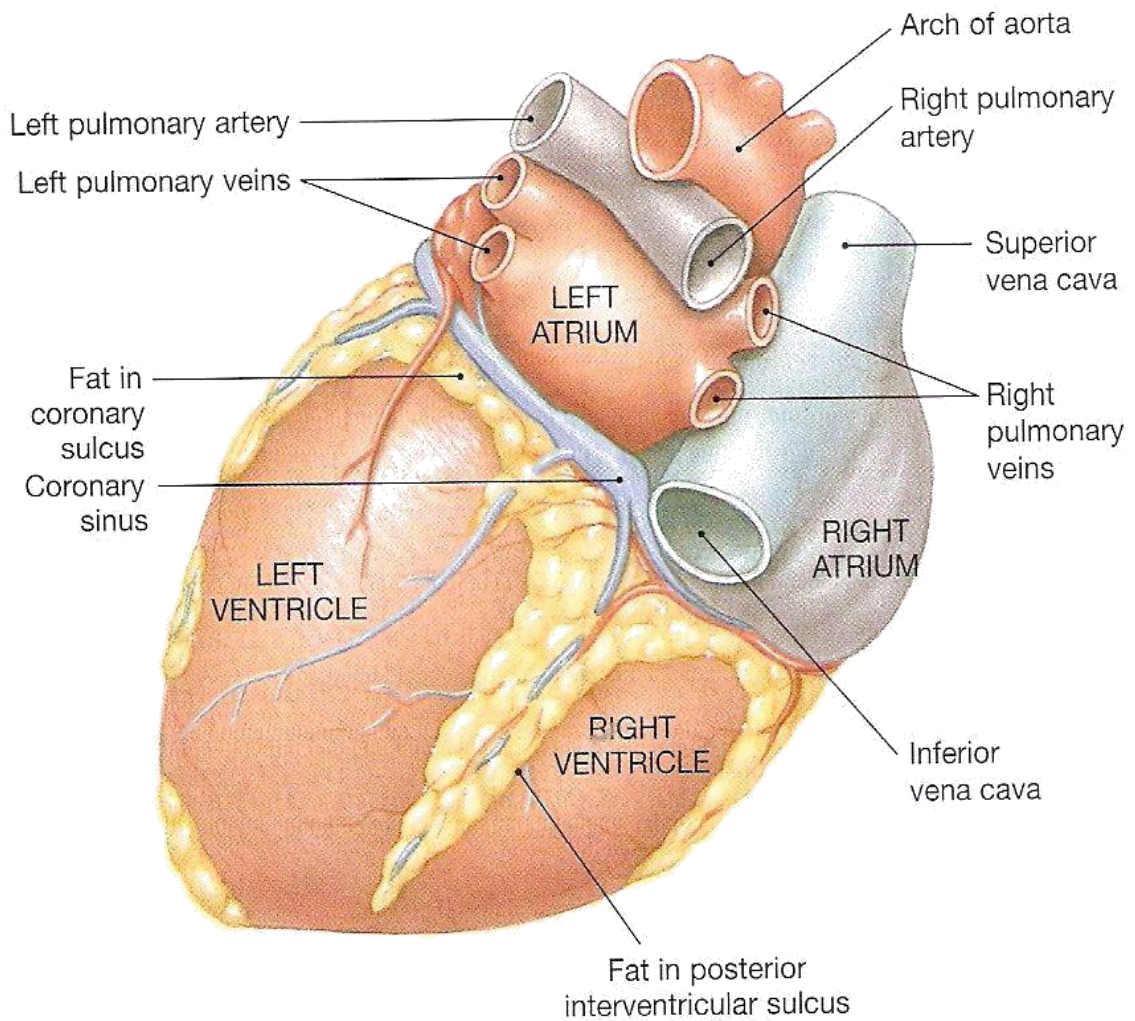
— **1- The heart:**

- is a muscular pump consisting of four chambers; two atria and two ventricles.
- 1-1-Right and left atria:- the two atria are separated from each other by the interatrial septum. They receive blood from veins “R.atria” from vena cava superior and inferior, and the “left atria” from the four pulmonary arteries.
- 1-1-1-The atrial functions:
 - 1- primarily as reservoirs, where the blood returning from veins collects before it enters the ventricles.
 - 2- contraction of the atria forces blood into the ventricles to complete ventricular filling.



— 1-2- the right and left ventricles: they are the major pumping chambers of the heart. They eject they blood into arteries “ R.ventricle into pulmonary trunk to pulmonary circulation, and left ventricle into aorta to systemic circulation throughout all the body”. The two ventricles are separated from each other by the muscular interventricular septum.

The wall of the L.ventricle is thicker than the wall of R. ventricle because it does more work than the R.ventricle “ the pressure approximately 120 mmHg in the L.ventricle, while in the R.ventricle reach only to one fourth of the pressure in the L.ventricle during systole”.



(b) Posterior surface

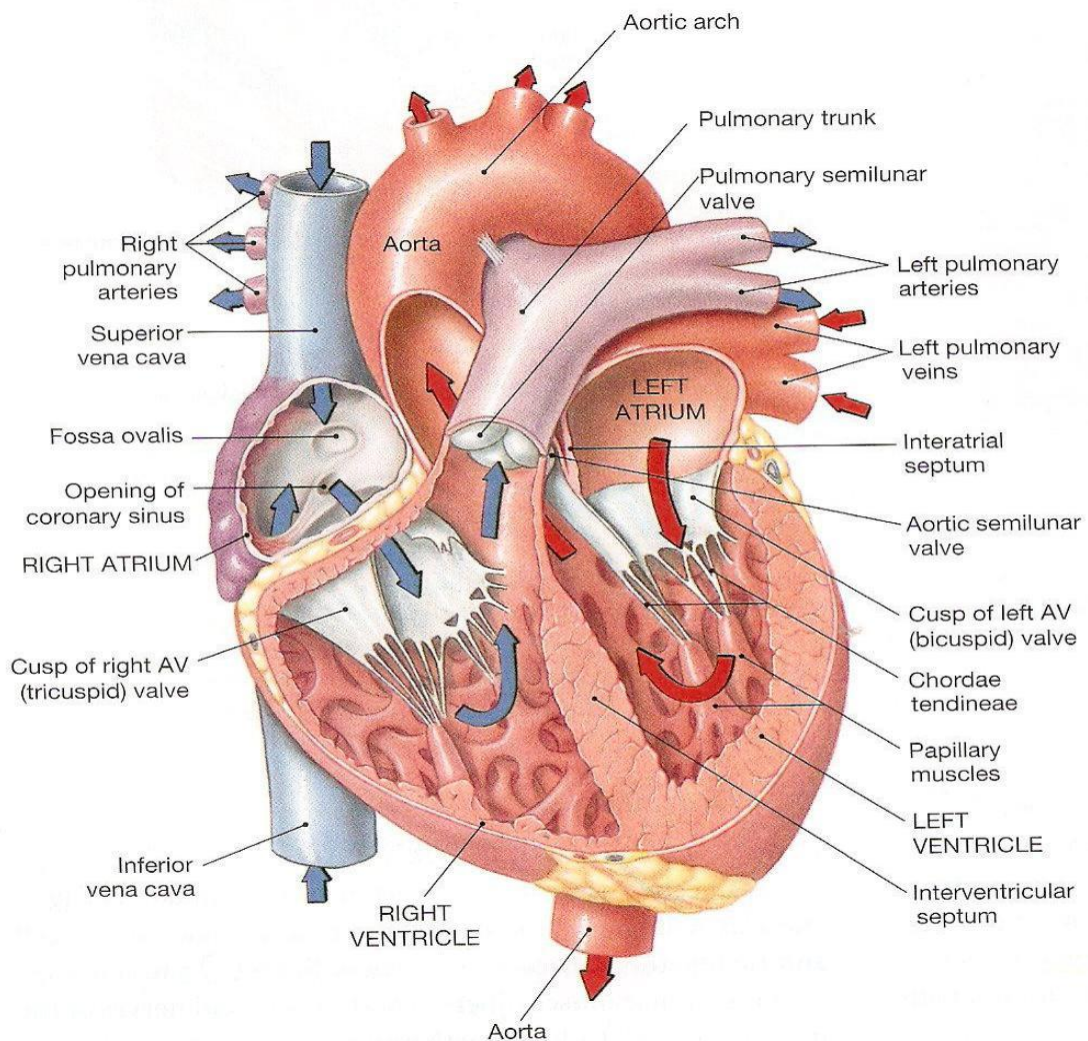
1-3-The heart valves:

— 1-3-1- atrioventricular valves:

They are located between R. atrium and R. ventricle, and L. atrium and L. ventricle. Their function to allow blood to flow from the atria into ventricles but prevent the backflow of blood from ventricles into the atria.

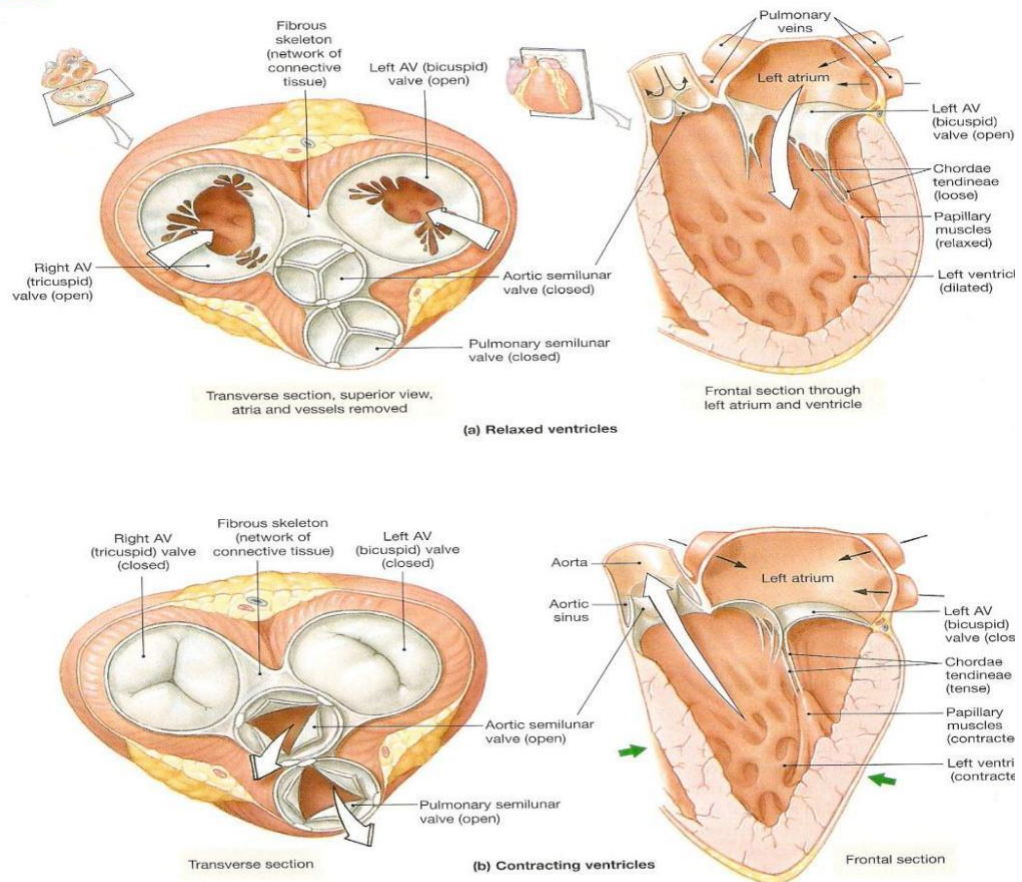
- 1- The valve between the R.A. and R.V. have three flaps, or cusps of fibrous tissue known as the tricuspid valve.

- 2- the valve between L.A. and L.V. has only two flaps, or cusps known as bicuspid or mitral valve.
- Each ventricle contains cone-shaped muscular pillars called papillary muscles, which attached by thin, strong connective tissue fibers called chordae tendineae to the cusps of A.V. valves. their function to prevent the valves from opening into the atria so much by pulling on the chordae tendineae.



- 1-3-2- aortic and pulmonary semilunar valves: each valve consists of three pocketlike semilunar cusps “half moon-shaped”. Blood flowing out the ventricles pushing against each valve; forcing it open. When blood flow back toward ventricles; it enter the pockets of the cusps, causing them to meet in the center of the Aorta and the pulmonary trunk and closing them to prevent the

backflow of blood from the Aorta into L. ventricles. And from the pulmonary trunk into R. ventricles.

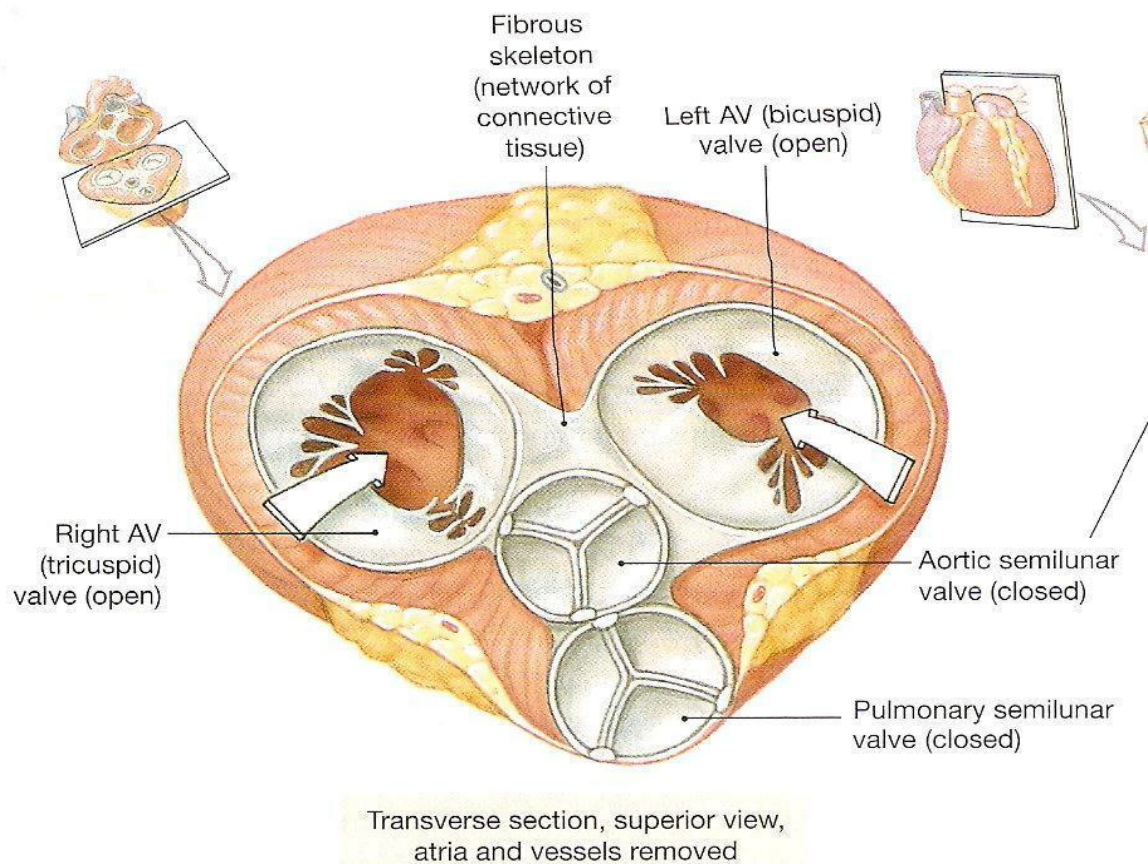


● **FIGURE 12-6 The Valves of the Heart.** White arrows indicate blood flow into and out of the ventricle; black arrows, blood flow into an atrium; and, green arrows, ventricular contraction. (a) When the ventricles are relaxed, the AV valves are open, and the semilunar valves are closed. The chordae tendineae are slack, and the papillary muscles are relaxed. (b) When the ventricles contract, the AV valves are closed, and the semilunar valves are open. Notice in the frontal section that the chordae tendineae and papillary muscles prevent backflow through the left AV valve.

1-4- Connective tissue of the heart:

- A-The connective tissue of the heart include abundant collagen and elastic fibers that wrap around each cardiac muscle cell and tie together adjacent cells. These fibers:
 - 1- provide support for the cardiac muscle fibers, blood vessels, and nerves of the myocardium.
 - 2- add strength and prevent overexpansion of the heart.
 - 3- help the heart to return to normal shape after contraction.

- B- Connective tissue also forms the fibrous skeleton of the heart as a plate of fibrous connective tissue rings around the atrioventricular and semilunar valves, its functions:
 - 1- provide a solid support for the valves.
 - 2- serves as electrical insulation between the atria and ventricles.
 - 3- provide a rigid site of attachment for cardiac muscle, so it called the skeleton of the heart.



(a) Relaxed ventricles

1-5- conducting system of the heart:

- These are specialized cardiac muscle cells in the wall of the heart that form the conducting system of the heart. It consists of:
 - 1-5-1-Sinoatrial node(SA):- it is the pacemaker of the heart; located in the upper posterior wall of the right atrium, which

initiates the contraction cycle activity of the heart by origination the action potentials in the SA node and spread it over the R. & L. atria and the rest of conducting system. Pacemaker cells depolarized rapidly and spontaneously, generating 70-80 action potentials per minute. This results in a heart rate or 70 -80 beats per minute(bpm).

- After the stimulus for a contraction is generated at SA node, it must be distributed so that;
- 1- the atria contract together, before the ventricles.
- 2- the ventricles contract together, in a wave that begins at the apex and spreads toward the base. When the ventricles contract in this way, blood is pushed toward the base of the heart into Aorta and pulmonary trunk.

الوحدة الثامنة عشر - المحاضرة التاسعة عشر - الزمن: 120 دقيقة

أهداف:

يتوقع في نهاية الجلسة أن يكون الطالب قادراً على معرفة ماهو blood vessels

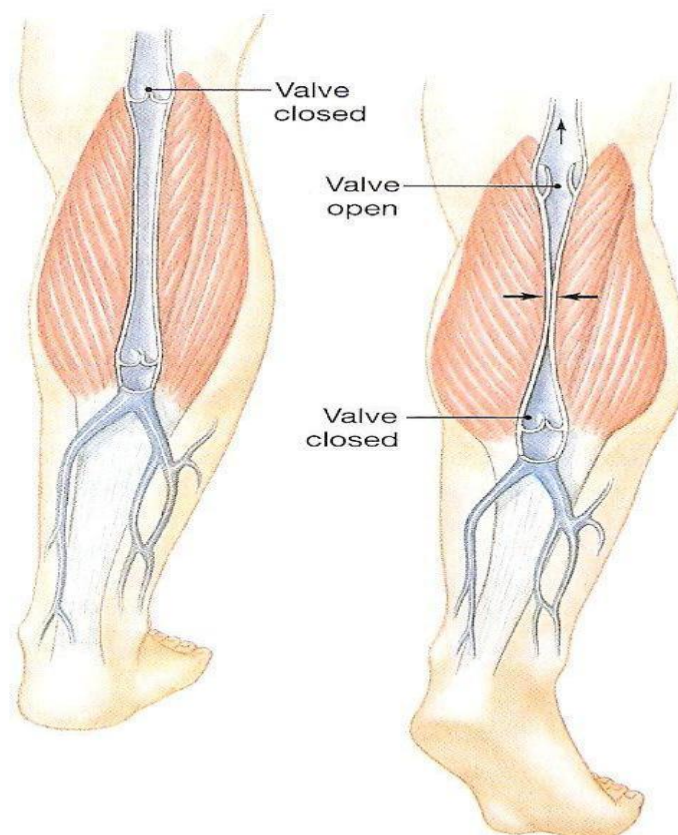
الأساليب والأنشطة والوسائل التعليمية

الوسائل التدريبية	الأساليب والأنشطة التدريبية	م
<ul style="list-style-type: none">● جهاز حاسوب● جهاز عرض● سبورة● اوراق واقلام	<ul style="list-style-type: none">● محاضرة● مناقشة● سؤال وجواب	18

المادة العلمية:

- Names of systemic veins:

- 1- superficial veins: these veins are found near the surface under the skin, as those in the extremities.
- 3- deep veins: the deep veins tend to parallel arteries and usually have the same names as the corresponding arteries as femoral vein.
- 3- superior vena cava: it collect blood from head, neck, upper extremities, and the chest; then goes to the heart.
- 4- inferior vena cava: it is much longer than the superior vena cava. It collect blood from the part of the body below the diaphragm and goes to the heart.
- 5- venous sinuses: is a large channel that drains deoxygenated blood but does not have the usual tubular structure of the veins. Such as coronary sinus which receives of most of the blood from the veins of the heart.



● **FIGURE 13-5 The Function of Valves in the Venous System.** Valves in the walls of medium-sized veins prevent the backflow of blood. The compression of veins by the contraction of adjacent skeletal muscles helps maintain venous blood flow.

3- The physiology of circulation:

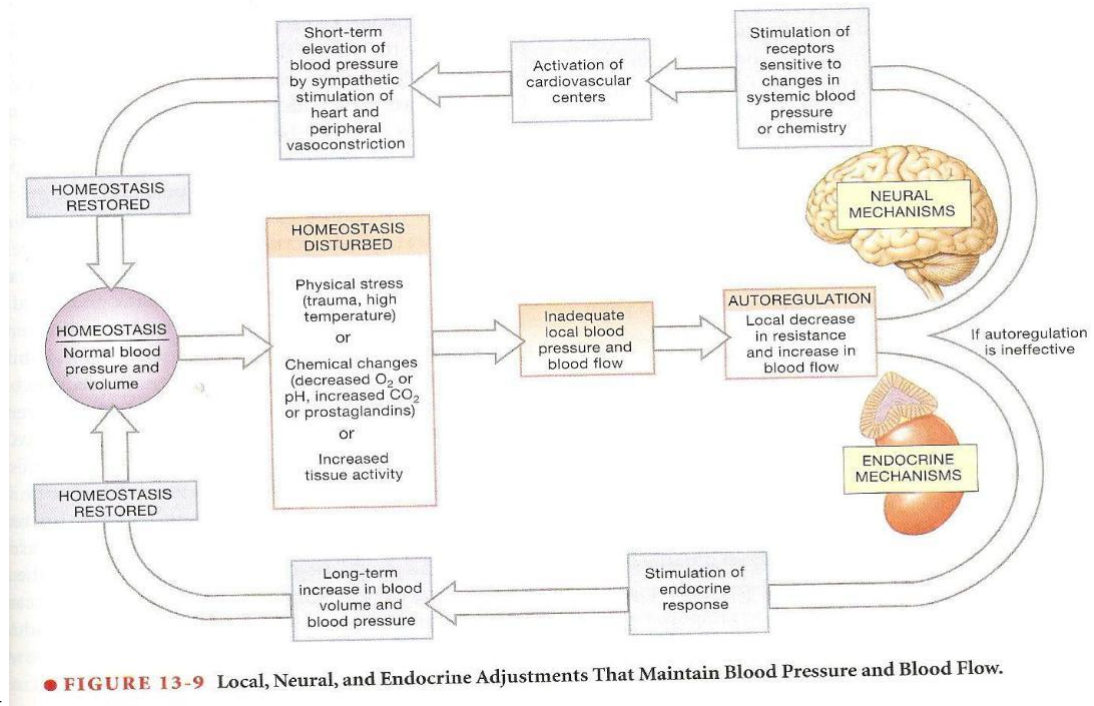
- 3-1- How capillaries work: the blood flows through capillaries surrounding the air sacs in the lungs, it picks up oxygen and unloads carbon dioxide; later when this oxygenated blood is pumped to capillaries in other parts of the body, it unloads the oxygen and picks up carbon dioxide as well as other substances resulting from cellular activities.
- 3-2- Vasoconstriction and vasodilatation: Vasoconstriction; refers to a decrease in the diameter of a blood vessel.
- vasodilatation; refers to an increase in the diameter of a blood vessel.

3-3- Regulation of blood pressure:

- Many factors includes in regulation of blood pressure:
- 1- Vasomotor activities: serve in part to regulate blood pressure
- 2- total blood volume.
- 3- cardiac output.
- 4- blood viscosity.
- 5- peripheral resistance.
- When blood vessels dilate; blood pressure decrease, and when vessels constrict; blood pressure increase.

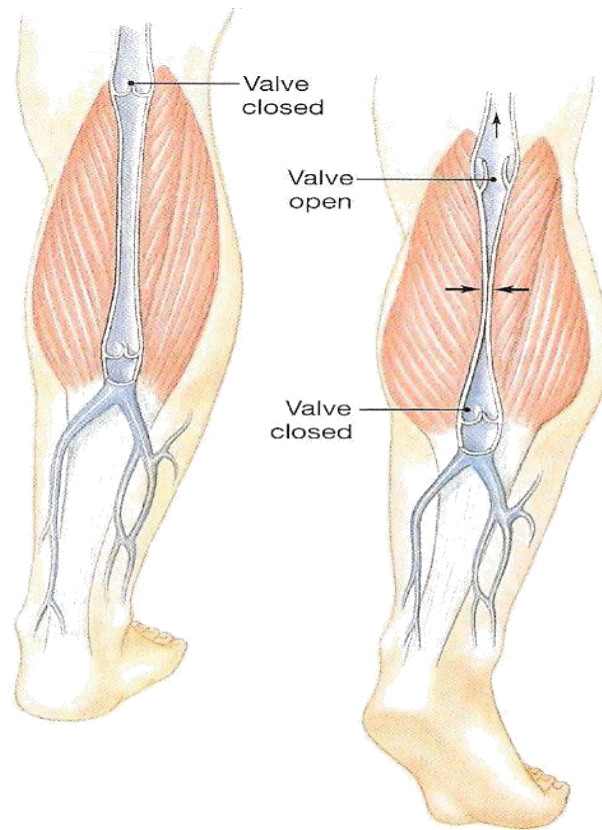
3-4- Blood distribution:

- Vasomotor activities regulate the amount of blood that flows to various parts of the body. Some organs, such as brain, liver, and kidneys, event at rest require large quantities of blood. Other organs, such as skeletal muscles and digestive organ need an increased supply of blood during increased activity(the blood flow in muscle can increase 20 times during exercise).
- This done by vasomotor changes, particularly by vasodilatation of arterioles which allows delivery of more blood to the tissues, while it decrease by vasoconstriction.



3-5- Return of blood to the heart:

- The blood return to the heart is done by two mechanism:
- By skeletal muscles contraction which squeeze the blood in the veins forward to the heart through the veins' valves, which prevent blood from flowing backward.
- During inspiration the chest expand, and the pressure in the chest cavity drops(negative pressure), causing the large veins in the chest “vena cava inferior and superior” to expand and draw blood back toward the heart.



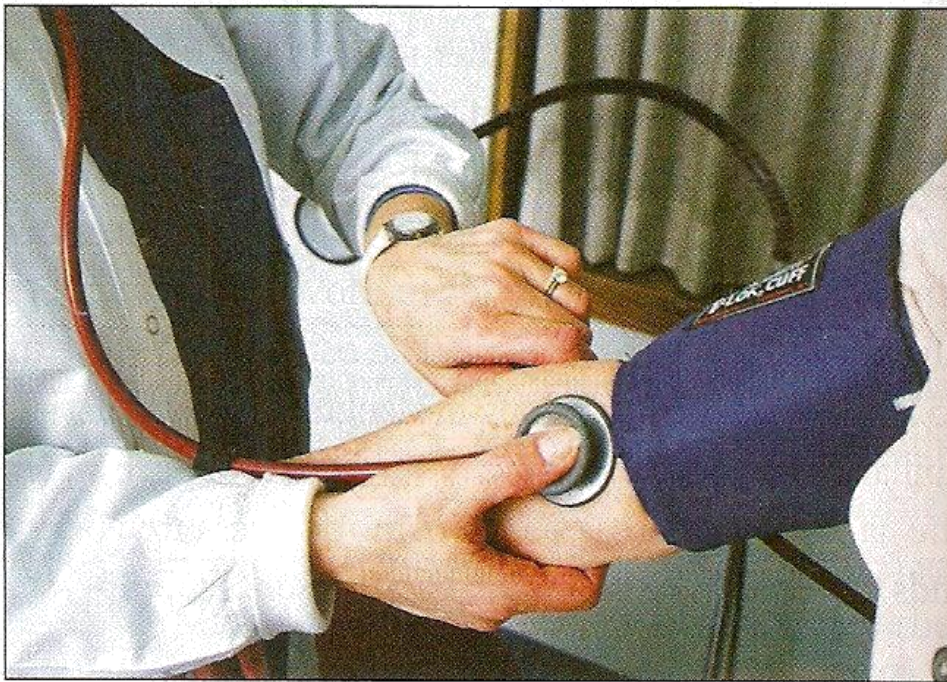
● **FIGURE 13-5 The Function of Valves in the Venous System.** Valves in the walls of medium-sized veins prevent the backflow of blood. The compression of veins by the contraction of adjacent skeletal muscles helps maintain venous blood flow.

418

3-5- Pulse and blood pressure:

— 3-5-1-Pulse: is the force of ventricular contraction starts a wave of increased pressure that begins at the heart and travels along the arteries. It's about 70-80 times per minute. It can be felt in any artery that is relatively close to the surface; such as radial (يربعك), carotid (يتابس), and dorsalis pedis (مدقلا رهظ) arteries. It is important to measure:

— 1- strength., 2- the regularity, 3- the rate.



(b)

● **FIGURE 13-8** Checking the Pulse and Blood Pressure. (a) Several pressure points can be used to monitor the pulse or control peripheral bleeding. (b) A sphygmomanometer and a stethoscope are used to check an individual's blood pressure.

3-5-2- blood pressure and its determination:

- Blood pressure: is the force that the blood produced against the blood vessels wall. It measured by instrument called a sphygmomanometer.
- Two variables are measured:
 - 1- systolic pressure: occurs during heart muscle contraction; average around 120 mmHg and is expressed in millimeter of mercury.
 - 2- diastolic pressure: occurs during relaxation of the heart muscle; average around 80mmHg
- Procedure method: the sphygmomanometer is essentially a graduated column of mercury connect to an inflatable cuff. The

cuff is wrapped around the patient's arm above of the right or left elbow joint; and then inflated it with air by hand bulbe until the brachial artery is compressed and the blood flow cutoff. Then, listening with stethoscope placed over the artery distal to the cuff; slowly lets air out of the cuff by opening the valve on the bulbe until the first pulsation are heard, at this time the pressure is equal to the systolic pressure, and this pressure is read off the mercury column. Then, more air is let out until the pulse's sound become characteristic muffled or disappears, at this point it indicates diastolic pressure. The distinctive sounds heard during this test are called sounds of korotkoff. When the blood pressure is recorded, systolic and diastolic pressures are usually separated by a slash, as in "120/80"(read "one twenty over eighty")

الوحدة العشرون - المحاضرة الواحد والعشرون- الزمن: 120دقيقة

أهداف المحاضرة

يتوقع في نهاية الجلسة أن يكون الطالب قادراً على معرفة ماهو and immune system- lymphatic system

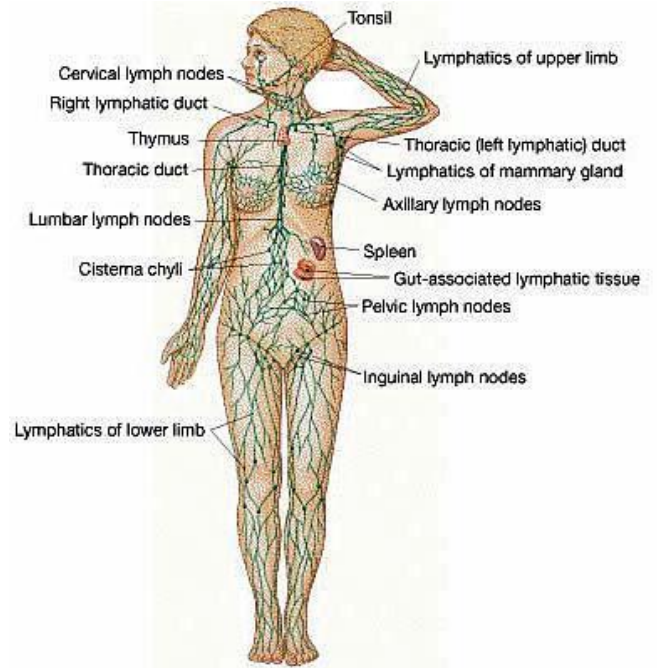
الأساليب والأنشطة والوسائل التعليمية

الوسائل التدريبيه	الأساليب والأنشطة التدريبيه	م
<ul style="list-style-type: none"> • جهاز حاسوب • جهاز عرض • سبورة • اوراق واقلام 	<ul style="list-style-type: none"> • محاضرة • مناقشة • سؤال وجواب 	20

المادة العلمية:

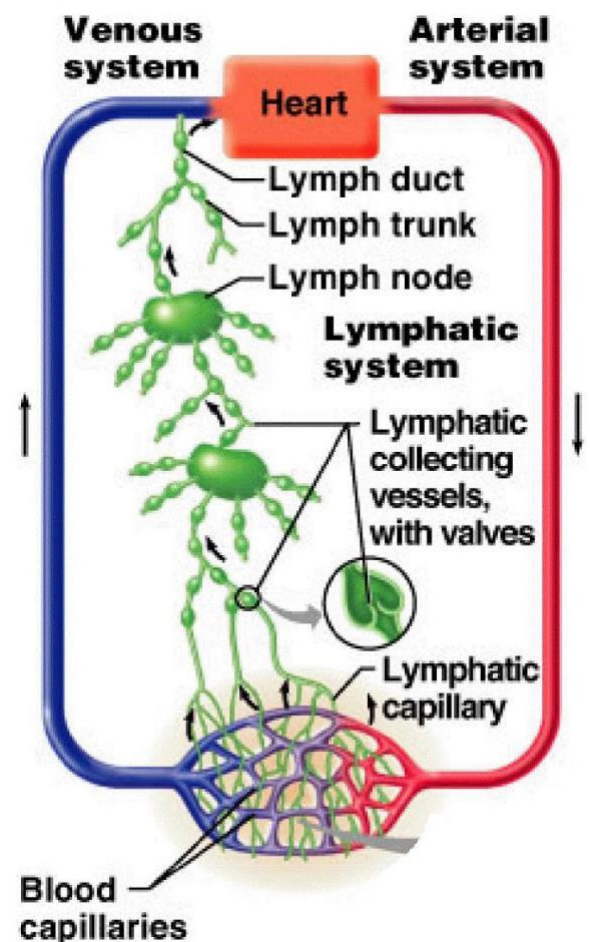
The Lymphatic System

- network of tissues, organs and vessels that help to maintain the body's fluid balance & protect it from pathogens
- lymphatic vessels, lymph nodes, spleen, thymus, tonsils, etc
- without it neither the circulatory system nor the immune system would function
- can be thought of as an accessory to the circulatory system
- it helps the circulatory system to do its job
- the two systems are directly connected together
- it consists of fluid derived from plasma =lymph and white blood cells (esp. lymphocytes and macrophages (monocytes))
- the lymph travels in only one direction - it doesn't circulate



General Functions of Lymphatic System:

1. **Returns Fluid from Tissues to Blood** ~85% of fluids that leak out of blood returns to blood via blood capillaries ~15% returns via lymph capillaries- in 24 hrs lymphatics return fluid equivalent to entire blood volume - if lymphatic system becomes blocked edema
2. **Returns Large Molecules to Blood** ~25-50% of blood proteins leak out of capillaries each day
 - they cannot get back into capillaries
 - instead lymphatic capillaries pick them up and return them to the blood
 - if lymphatics are blocked blood protein decreases leading to fluid
 - imbalances in body
3. **Absorb and Transport Fats** - Special lymphatic capillaries (=lacteals) in villi of small intestine absorb all lipids and fat soluble vitamins from digested food bypasses liver much goes straight to adipose tissues
4. **Hemopoiesis** - some WBC's (lymphocytes, monocytes) are made in lymphatic tissues (not bone marrow) main supply of lymphocytes
5. **Body Defense/Immunity** - lymphoid tissue is an important component of the Immune System (forms a diffuse surveillance defense system in all body tissues and organs
 - the major role of WBC's is in body defense
 - lymphatic system screens body fluids and removes pathogens and damaged cells



Lymph

- Lymph is a clear watery fluid that resembles blood plasma but: has fewer proteins its composition varies depending on organs that it drains
- the lymphatic system handles 125 ml/hr (2500-2800 ml of lymph/day) ~1/2 of this from the liver and small intestine alone

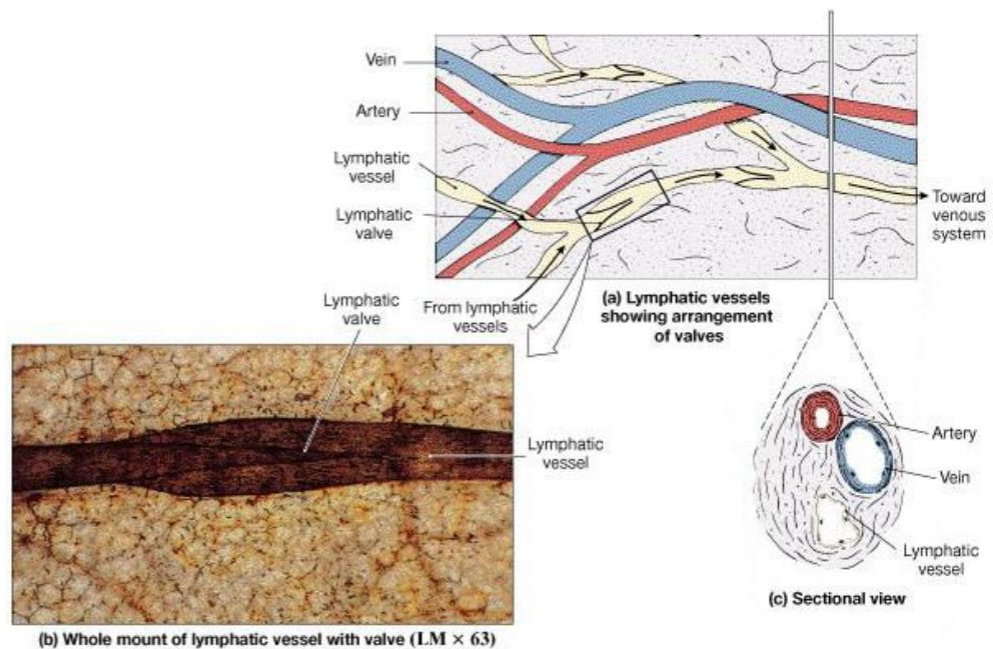
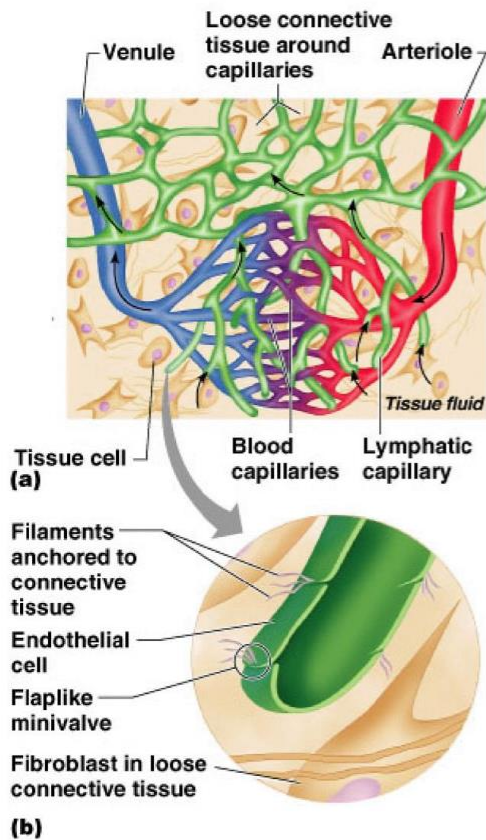
Lymphatic Vessels (lymphatics):

Lymphatic Capillaries originate in tissues as tiny blind ended sacs

- lie side by side with blood capillaries
- single layer of endothelial cells like blood capillaries
- but much more permeable to solvents, and large solutes and whole cells

Lymphatic Vessels - these small lymphatic capillaries merge with others to form larger lymphatic vessels - they resemble veins in structure:

- three layers – but much thinner
- 1-way valves – but many more (every few mm or so)
- also has lymph nodes at intervals along its course
- as they converge they become larger and larger

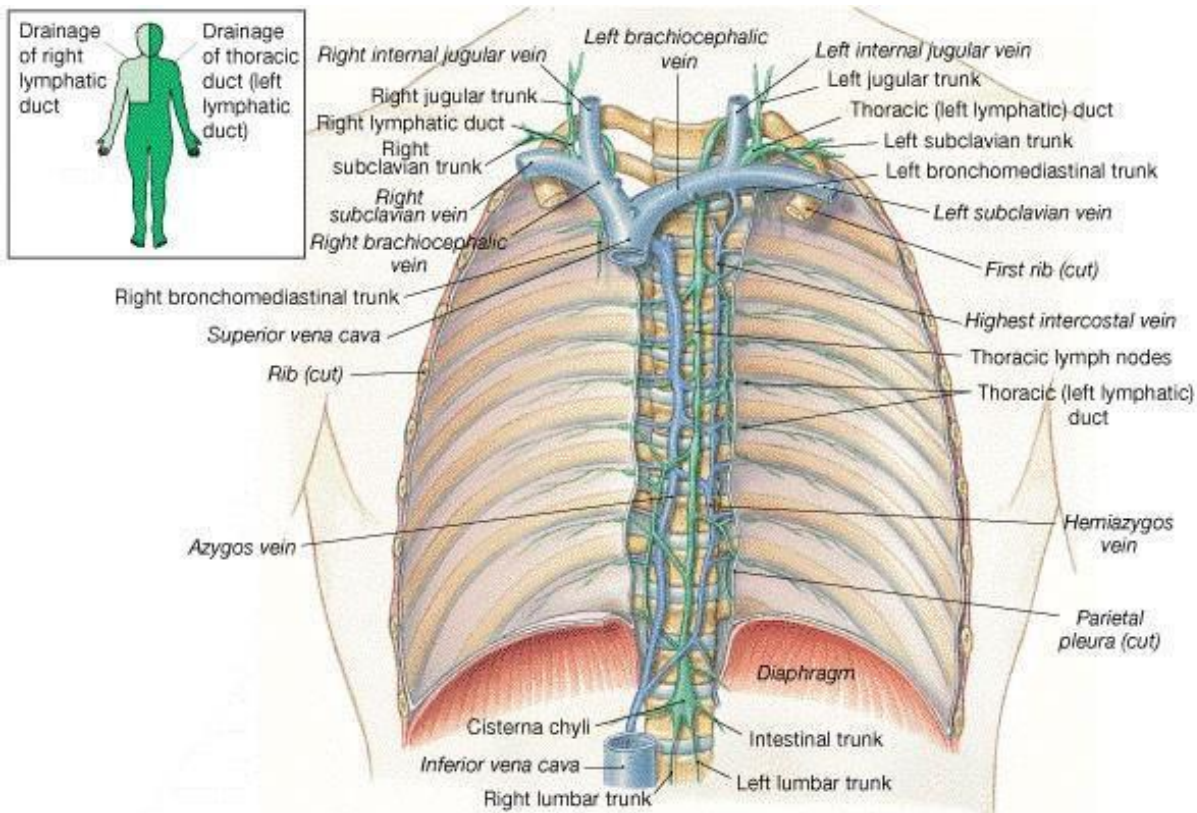
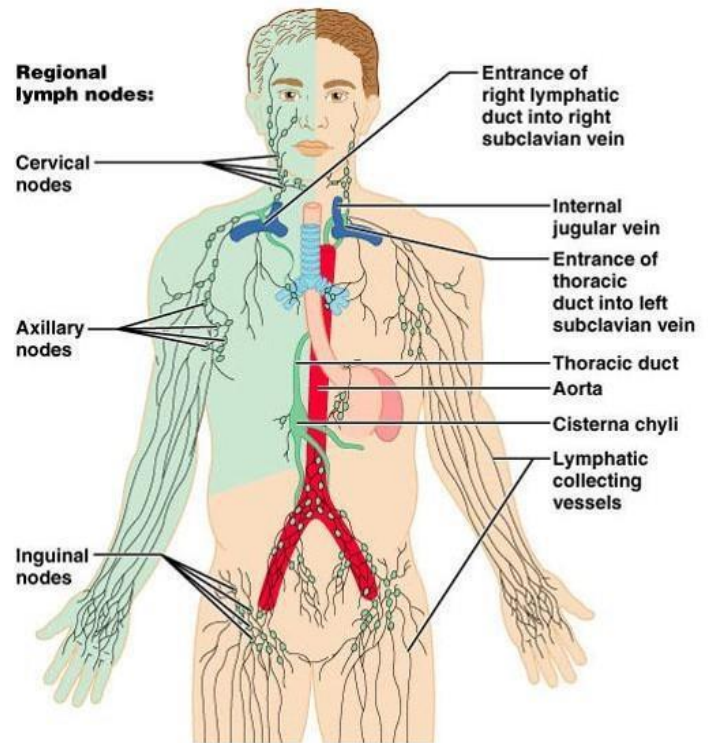


Lymphatic Ducts

- these lymphatic trunks merge together to form two major Lymphatic Ducts
- equivalent to major vessels of circulatory system but more like veins than arteries

Two major Lymphatic Ducts:

- **Right Lymphatic Duct** very short drains upper right quadrant of body drains into right subclavian vein at jct with jugular V
- **Thoracic Duct** much larger and longer drains the rest of body (3/4ths): all of body below diaphragm and left arm and left side of head, neck and thorax begins just below the diaphragm, anterior to vertebral column lumbar trunks and intestinal trunk join to form saclike cisterna chyli drains into left subclavian vein

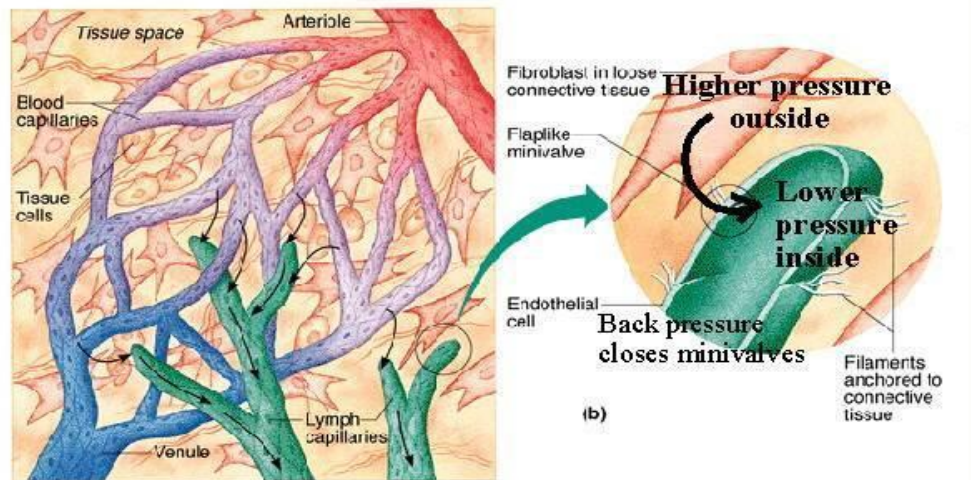


Flow of Lymph:

- fluid pressure in lymphatic system is very low, as in veins
- vessels contract rhythmically direction of flow is maintained by 1-way valves
- also body movements and pulsing of arteries help to move lymph along
- many vessels are wrapped in connective tissue with arteries: the pulsing of the arteries also helps move lymph along

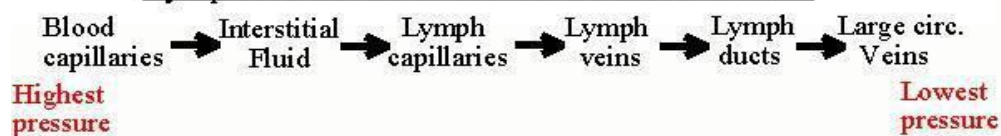
Lymph Circulation

- Lymph vessels are thin walled, valved structures that carry lymph
- Lymph is not under pressure and is propelled in a passive fashion
- Fluid that leaks from the vascular system is returned to general circulation via lymphatic vessels.
- Lymph vessels act as a reservoir for plasma and other substances including cells that leaked from the vascular system
- The lymphatic system provides a one-way route for movement of interstitial fluid to the cardiovascular system.
- Lymph returns the excess fluid filtered from the blood vessel capillaries, as well as the protein that leaks out of the blood vessel capillaries.
- Lymph flow is driven mainly by contraction of smooth muscle in the lymphatic vessels but also by the skeletal-muscle pump and the respiratory pump.



(a)

Lymphokinetic Motion and Pressure Gradient



LYMPH CIRCULATION

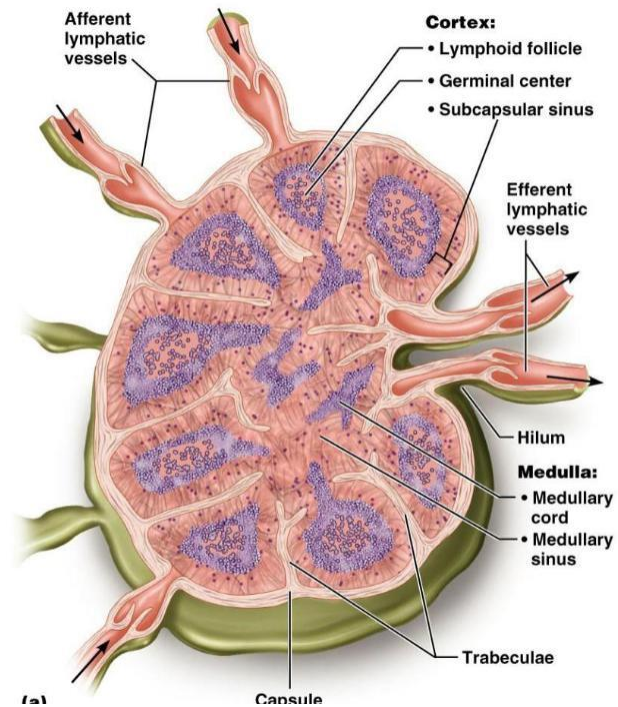
Interstitial fluid → Lymph → Lymph capillary → Afferent lymph vessel → Lymph node → Efferent lymph vessel → Lymph trunk → Lymph duct {Right lymphatic duct and Thoracic duct (left side)} → Subclavian vein (right and left) → Blood → Interstitial fluid

Lymph Nodes

- also called lymph glands
- oval, vary in size from pinhead to lima bean
- most numerous of the lymphatic organs (100's)

Functions of lymph nodes:

1. *cleanse lymph* - as lymph flows through sinuses node it slows down and microorganisms and foreign matter are removed
 2. *alert immune system* to pathogens
 3. *important in hemopoiesis* - lymphocytes and monocytes are made here
- lymph moves into nodes by way of several afferent lymphatic vessels
 - moves through sinus channels lined with phagocytic white blood cells
 - exits via 1-3 efferent lymph vessels
 - the WBC's in each node remove ~99% of impurities as lymph passes from node to virtually all impurities are normally removed
 - lymph nodes are widespread in body but most occur in groups or clusters:
 - eg. submental & submaxillary lymph nodes floor of mouth; drain nose, lips teeth
 - eg. cervical lymph nodes neck drain neck and head
 - eg. axillary lymph nodes armpit (axilla) and upper chest drains arm and upper thorax including breasts
 - breasts contains 2 sets of lymphatics: (NOT mammary glands) those that drain the skin over breast excluding the areola and nipple those that originate in and drain deeper portions of breast and skin of areola and nipple
 - numerous connections join the lymphatic systems of the breast with: the other breast axillary nodes (85% of lymph from breast enters them)
 - abdominal nodes
 - eg. inguinal lymph nodes in groin area drain legs and genitals



of

node

الوحدة الثاني وعشرون - المحاضرة الثالث وعشرون- الزمن: 120 دقيقة

أهداف المحاضرة الثاني وعشرون:

يتوقع في نهاية الجلسة أن يكون الطالب قادراً على معرفة ما هو respiratory system

الأساليب والأنشطة والوسائل التعليمية

م	الأساليب والأنشطة التدريبية	الوسائل التدريبية
22	<ul style="list-style-type: none">• محاضرة• مناقشة• سؤال وجواب	<ul style="list-style-type: none">• جهاز حاسوب• جهاز عرض• سبورة• اوراق واقلام

المادة العلمية:

-The respiratory system functions:-

- 1- Providing a large area for gas exchange between air and circulating blood.
- 2- Moving air to and from the gas-exchange surfaces of the lungs.
- 3- Protecting the respiratory surfaces from dehydration and defending against invading pathogens.
- 4- Producing sounds permitting speech, singing, and nonverbal auditory communication.
- 5- Providing olfactory sensations to the central nervous system for the sense of smell.

The organization of the respiratory system:

The major anatomical structures of the respiratory system are:

- Nose (including the nasal cavity and paranasal sinuses).
- Pharynx (throat).
- Larynx (voice box).
- Trachea (wind-pipe).
- Bronchi.



-Lungs contain the bronchioles (conducting passageways).



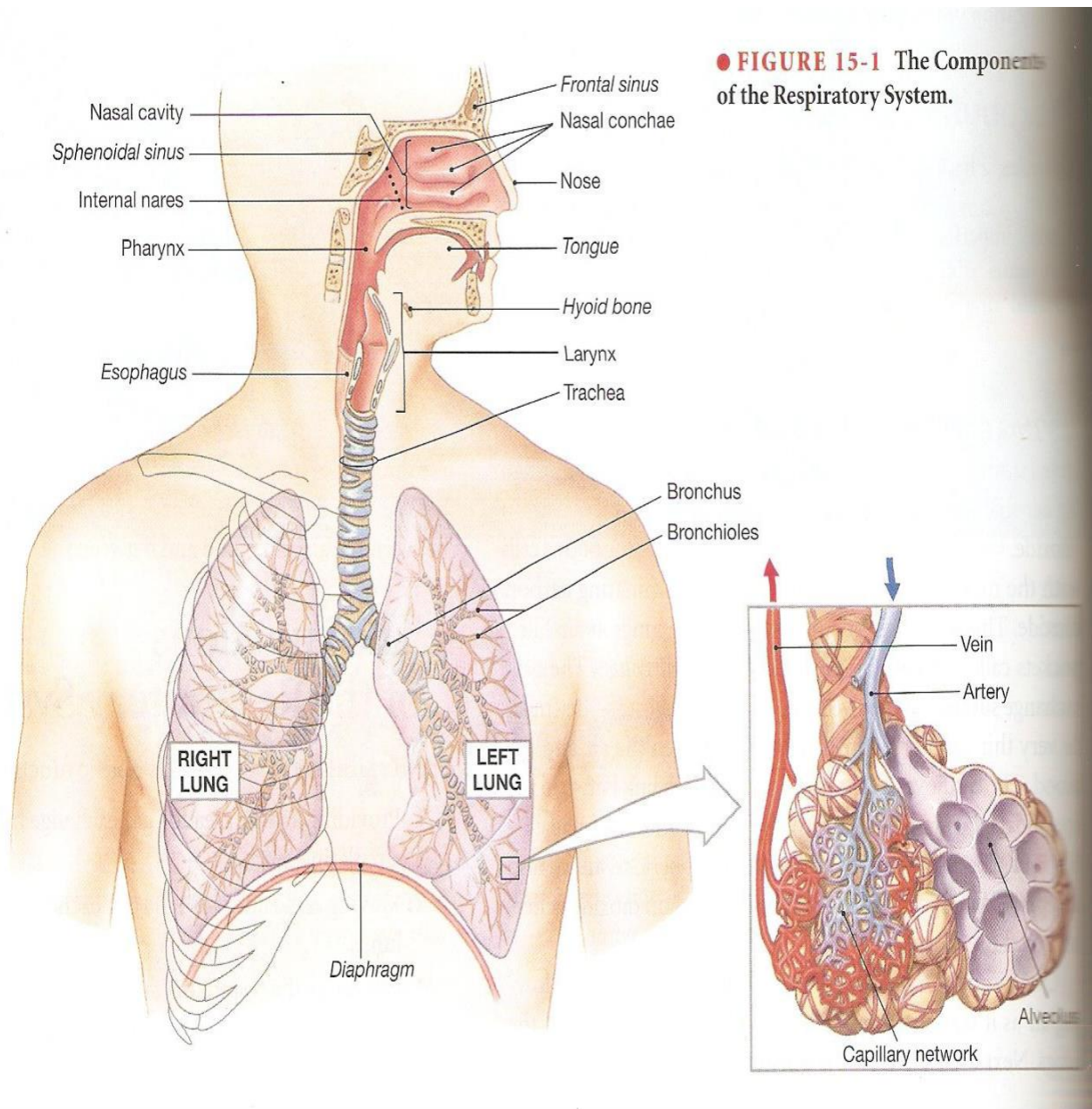
-Alveoli (exchange surfaces).

Respiratory tract: the airways that carry air to and from the exchange surfaces of the lungs, which can be divided into:



1- conducting portion: begins at the entrance to the nasal cavity and continues through the pharynx, larynx, trachea, bronchi, and the larger bronchioles. In addition to delivering air to the lungs, conducting passageways filter, warm, and humidify the air, thereby protecting the alveoli from debris, pathogens, and environmental extremes. By the time inhaled air reaches the alveoli, most foreign particles and pathogens have been removed, and the humidity and temperature are within acceptable limits.

▲ **2- Respiratory portion:** includes the smallest and most delicate bronchioles and the alveoli, which provide large blood-gas exchange surfaces.

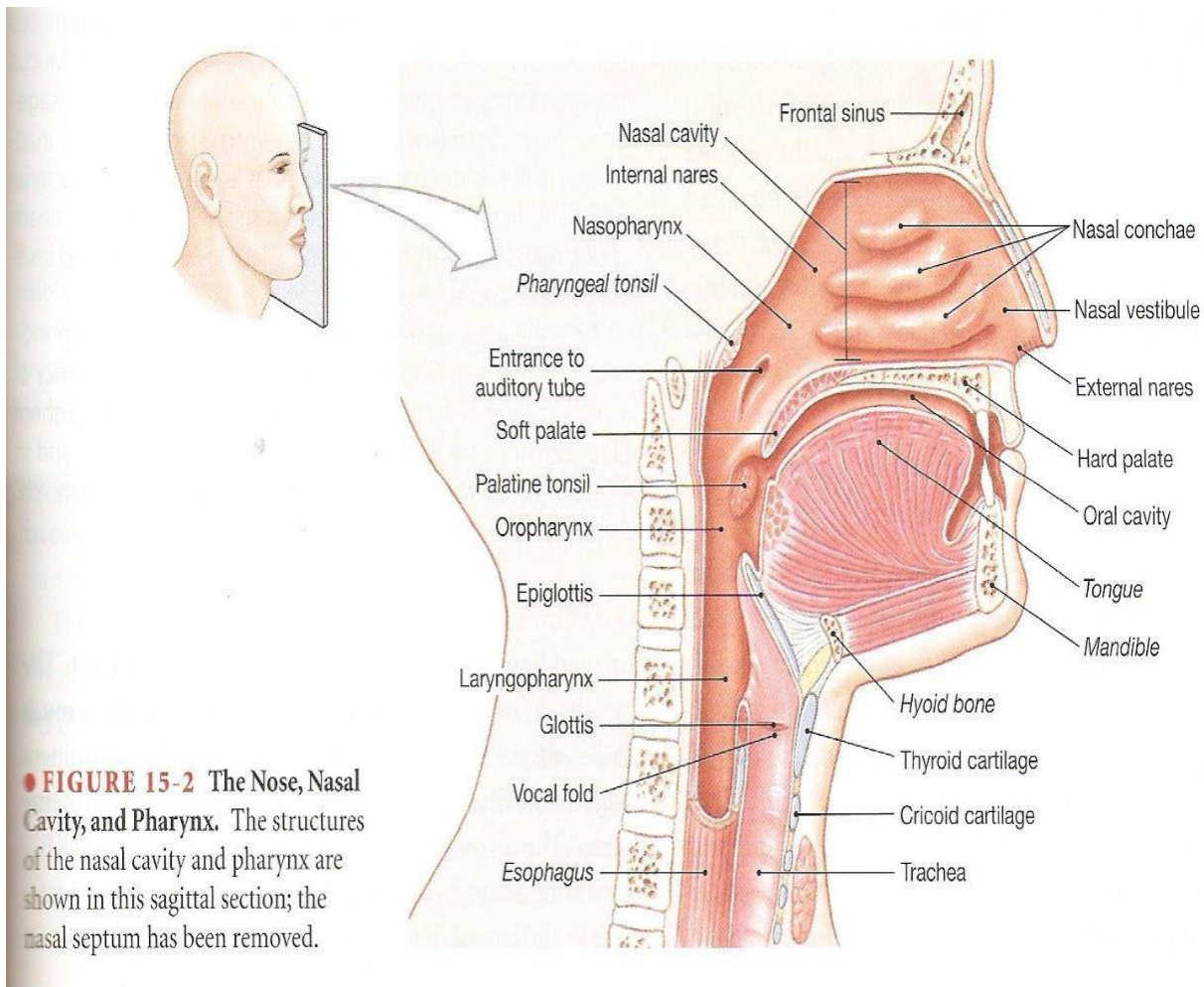


▲ **The nose :** air normally enters the respiratory system through the paired external nares, or nostrils, which opened into the nasal cavity. The nasal vestibule is the space enclosed within the flexible tissues of the nose. Here coarse hairs extend across the nostrils and guard the nasal cavity from large particles such as sand, dust, and even insects. The nasal cavity opens into nasopharynx at the internal nares.

▼ The nose contain also paranasal sinuses (the frontal, sphenoid, ethmoid, and maxillary sinuses).

▲ The nasal septum divides the nasal cavity into left and right sides.

▼ The nasal cavity and much of the respiratory tract are lined by protective, mucous membrane, or respiratory mucosa. This membrane is made of respiratory epithelium, a ciliated columnar epithelium containing many goblet cells, and underlying loose connective tissue layer (the lamina propria) containing mucous glands. Cilia sweep that mucous and any trapped debris or microorganism toward pharynx, where they can be swallowed and exposed to the acids and enzymes of the stomach.



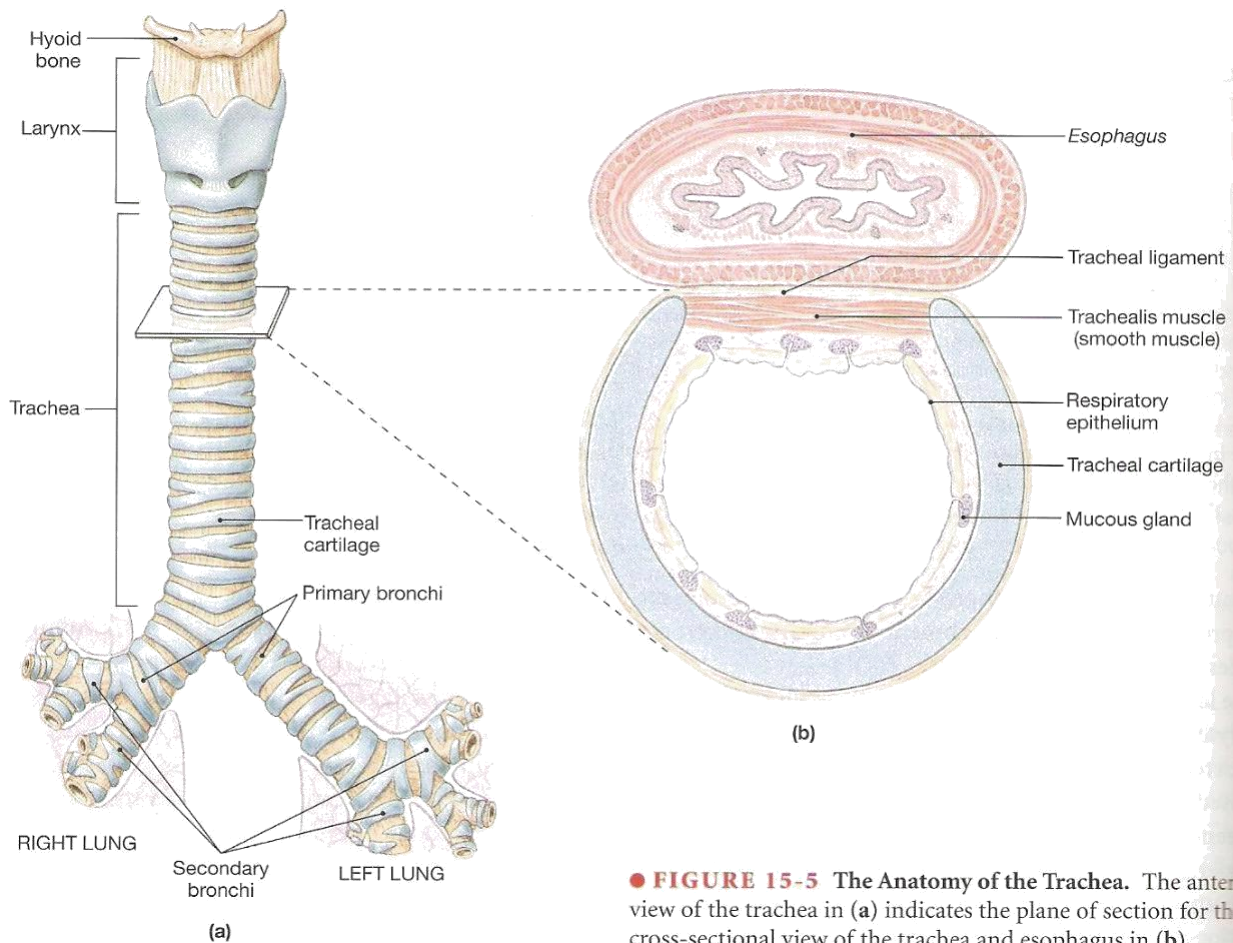
▲ **The pharynx:** or throat, is a chamber shared by the digestive and respiratory systems. It extends between the internal nares and the entrances to the larynx and esophagus and consists of three subdivisions: the nasopharynx, the oropharynx, and the laryngopharynx. The last two regions are lined by a stratified squamous epithelium that can resist mechanical abrasion, chemical attack, and pathogenic invasion.

↑ **The larynx:** or voice box, consists of nine cartilages stabilized by ligaments, skeletal muscles, or both. The glottis is a narrow opening for entry of inhaled air through larynx. Epiglottis projects above the glottis. During swallowing, the larynx is elevated and the elastic epiglottis folds back over the glottis, preventing the entry of liquids or solid food into the respiratory tract. The larynx contain the vocal cords for producing the voice. The voices ton related to the length, diameter, and the tension of the vocal cord. short, and thin cord vibrate more rapidly, producing high-pitched tone, while thick, and long cord vibrate more slowly producing a low pitched tone.

▶ **The trachea:** or windpipe, is a tough, flexible tube that is about 2.5 cm in diameter and approximately 11 cm long. The trachea begins at the level of the sixth cervical vertebra, where it attaches to the cricoid cartilage of the larynx. It ends in the mediastinum, at the level of the fifth thoracic vertebra, where it branches to form the right and left primary bronchi.

↑ The wall of the trachea are supported by 15-20 tracheal cartilages. These C-shape cartilages protect the airway; by stiffening the tracheal walls, they prevent trachea's collapse or overexpansion as pressures change in the respiratory system. The open portion of the c-shaped tracheal cartilages face posteriorly, toward the esophagus, so the posterior tracheal wall can easily distort, allowing large masses of food to pass along the esophagus.

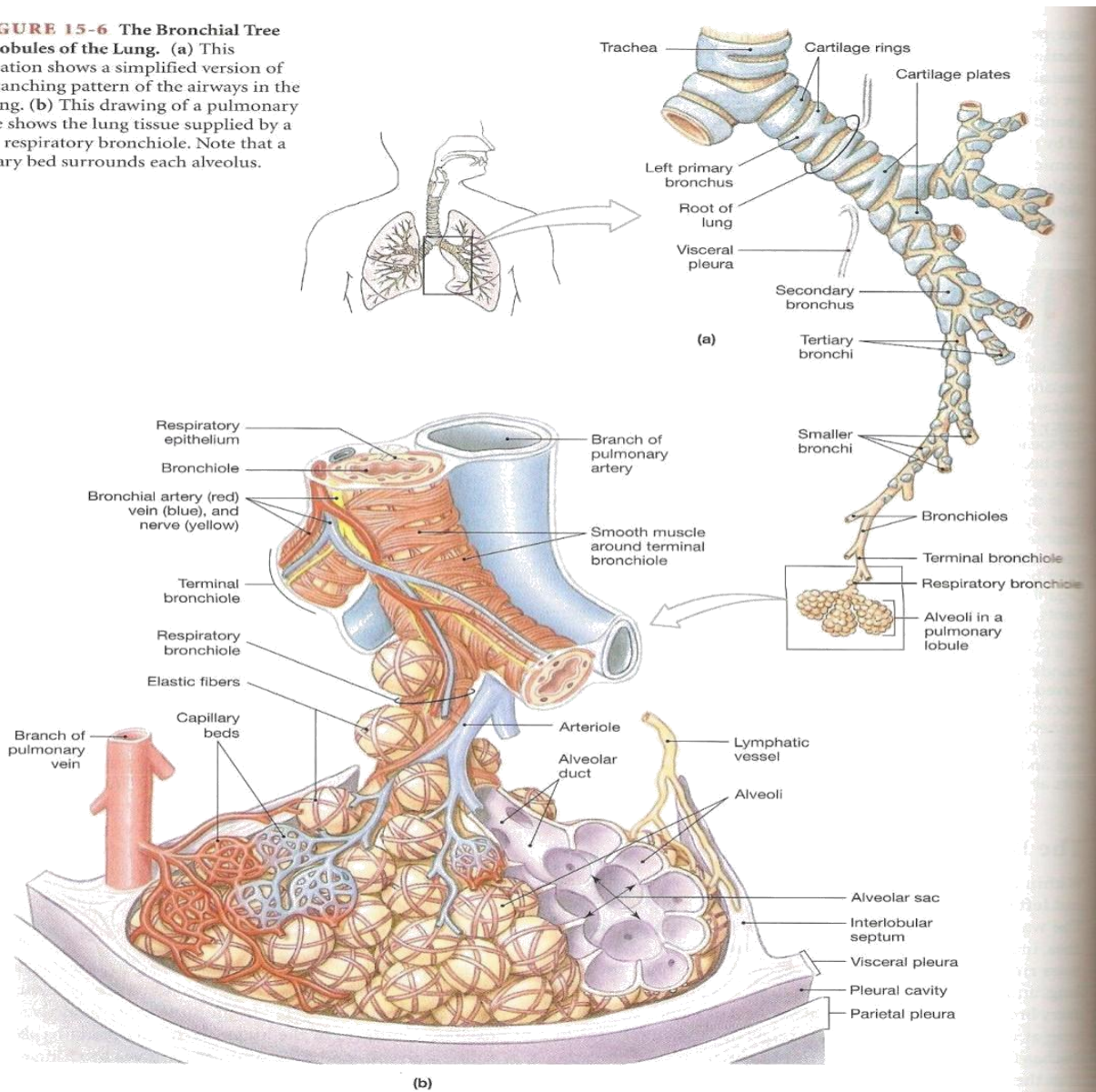
↑ The ends of each tracheal cartilage are connected by an elastic ligament and the smooth tracheal muscle allowing the change of diameter of the trachea under autonomic control. Sympathetic stimulation increases the diameter of the trachea, making it easier to move large volumes of air along the respiratory passageways.



● **FIGURE 15-5** The Anatomy of the Trachea. The anterior view of the trachea in (a) indicates the plane of section for the cross-sectional view of the trachea and esophagus in (b).

- ▲ **The bronchi:** within the mediastinum the trachea branches into the right and left primary bronchi. The walls of the primary bronchi resemble that of the trachea, including a ciliated epithelium and C-shaped cartilaginous rings.
- ▲ The right primary bronchus supplies the right lung, and the left supplies the left lung.
- ▲ In each lung, the primary bronchi branch into smaller and smaller airways that form the bronchial tree which consist of secondary and tertiary bronchi.

● **FIGURE 15-6 The Bronchial Tree and Lobules of the Lung.** (a) This illustration shows a simplified version of the branching pattern of the airways in the left lung. (b) This drawing of a pulmonary lobule shows the lung tissue supplied by a single respiratory bronchiole. Note that a capillary bed surrounds each alveolus.



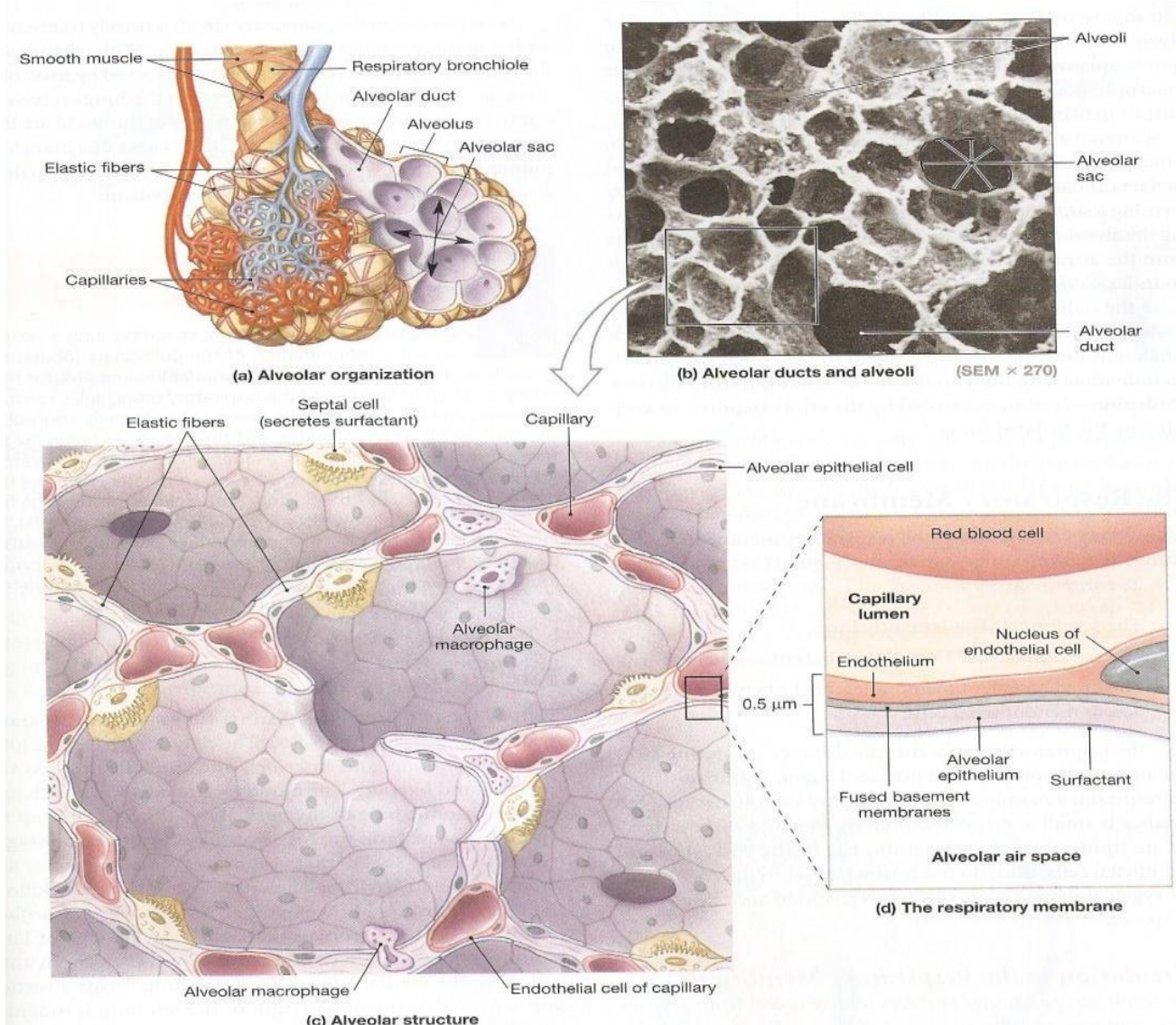
↑ **The bronchioles:** are the smallest airway in the bronchial tree with diameter about 1mm.

↑ Bronchioles branch further into terminal bronchioles with diameter of 0.3-0.5mm. Each terminal bronchiole supplies air to a lobule of the lung. Within a lobule, a terminal bronchiole divides to form several respiratory bronchioles. these passages, the thinnest branches of the bronchial tree, deliver air to the gas-exchange surfaces of the lung.

↑ **The alveolar ducts and alveoli:** respiratory bronchioles open into passageways called alveolar ducts. The ducts end at alveolar sacs, common chambers connected to multiple individual alveoli—the exchange surfaces of the lung (equal

approximately 140 square meters). Each lung contains about 150 million alveoli, and their abundance gives the lung an open, spongy appearance.

↑
 The alveolar epithelium primarily consists of an unusually thin simple Squamous epithelium. Each alveoli contain alveolar macrophages (dust cell) patrol the epithelium, phagocytizing dust or debris that reached the alveolar surfaces. Also here present septal cells, which secrete onto the alveolar surfaces an oily secretion called surfactant to reduced surface tension to prevent collapse the delicate alveolar walls.



● **FIGURE 15-7 Alveolar Organization.** (a) Several alveoli open off of a single alveolar duct. (b) This SEM reveals the open, spongy texture of lung tissue. (c) This diagram provides some details of alveolar structure. (d) The respiratory membrane is made up of an alveolar epithelial cell, a capillary endothelial cell, and their fused basement membranes.

The respiratory membrane:

▶ Gas exchange occurs across the respiratory membrane of the alveoli. The respiratory membrane consists of three components:

- ▶ 1- The squamous alveolar epithelium.
- ▶ 2- The endothelial cells lining an adjacent capillary.
- ▶ 3- The fused basement membranes that lie between the alveolar and endothelial cells.

▶ At the respiratory membrane, the distance separating alveolar air from blood can be as little as $0.1\mu\text{m}$. Diffusion across the respiratory membrane proceeds very rapidly because the distance is very small and because both oxygen and carbon dioxide are lipid soluble. The membranes of the epithelial and endothelial cells, thus, do not pose a barrier to the movement of oxygen and carbon dioxide between blood and the alveolar air spaces.

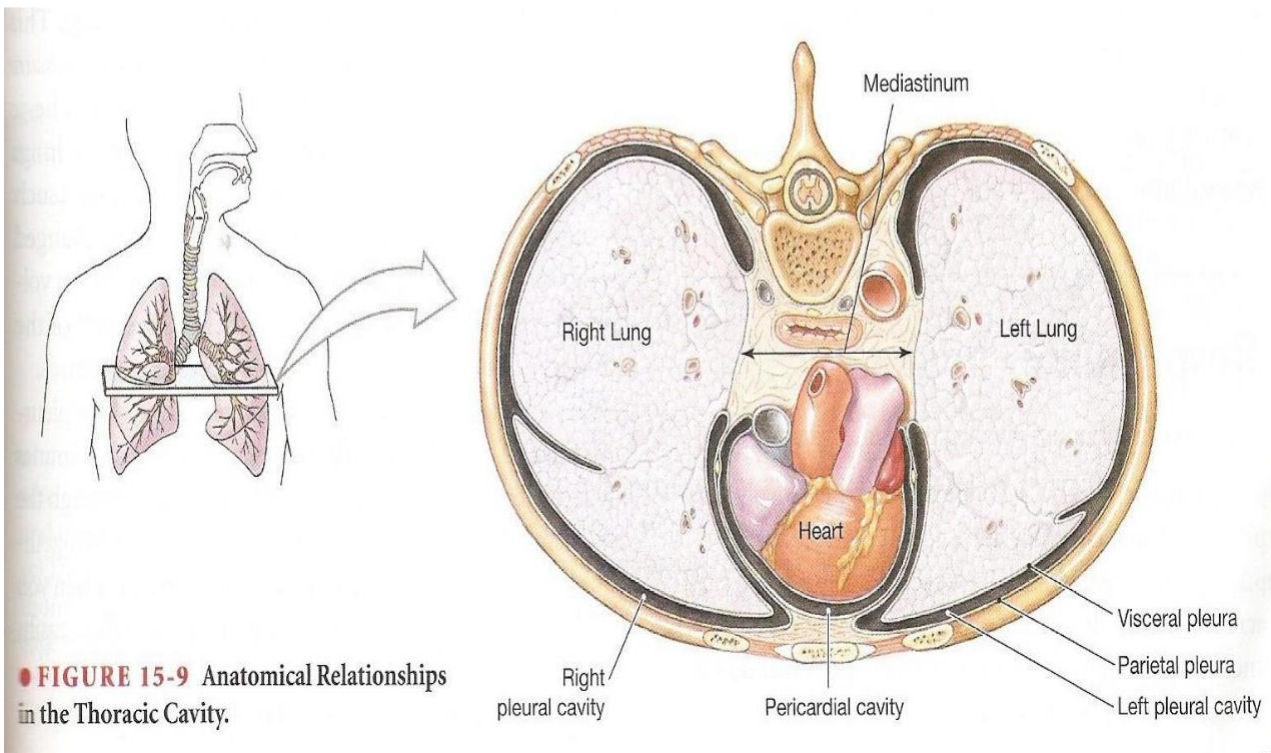
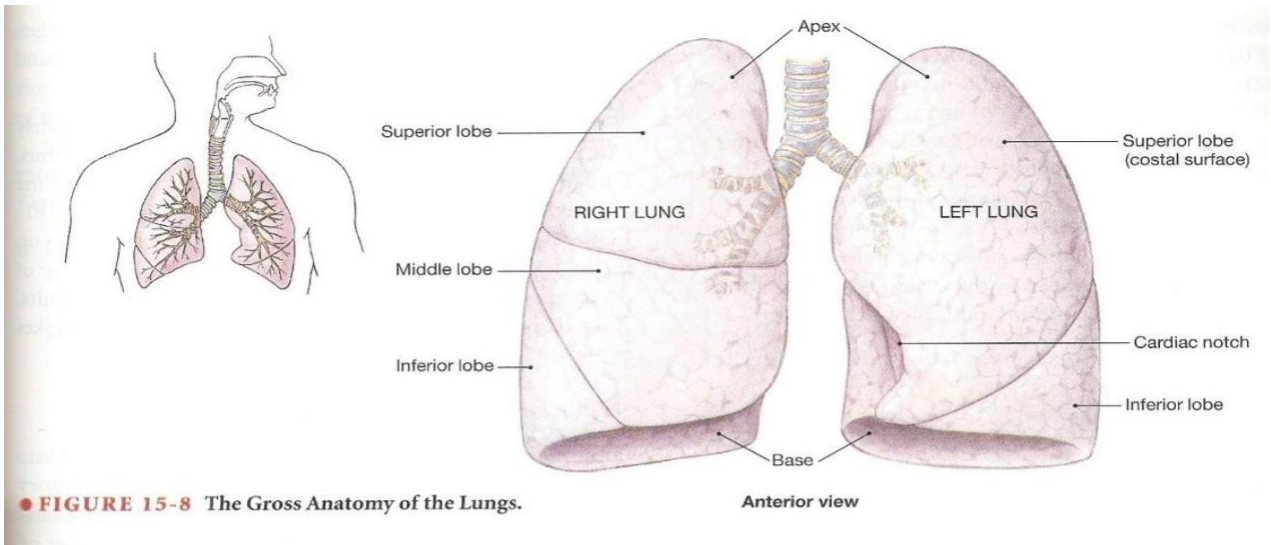
Circulation to the respiratory membrane:

- ▶ The respiratory exchange surfaces receive blood from arteries of the pulmonary circuit. Each lobule receives an arteriole. And network of capillaries surrounds each alveolus directly beneath the alveolar epithelium. After passing through the capillaries and into venules, blood enters the pulmonary veins, which deliver it to the left atrium.
- ▶ Blood pressure in the pulmonary circuit is usually relatively low, with systemic pressures of 30mmHg or less.

The organization of the respiratory system:

- ▶ The lung: each of the two lungs has distinct lobes that are separated by deep fissures. The right lung has three lobes (superior, middle, and inferior), and the left lung has two (superior, and inferior).
- ▶ The lungs have a light and spongy consistency because most of the actual volume of each lung consists of air-filled passageways and alveoli. An abundance of elastic fibers gives the lungs the ability to tolerate the large changes in volume.
- ▶ The pleural cavities: the thoracic cavity has the shape of a broad cone. Its wall are the rib cage, and its floor is the muscular diaphragm. Within the thoracic cavity, each lung occupies a single pleural cavity. Lined by a serous membrane called pleura. The

parietal pleura covers the inner surface of the body wall and extends over the diaphragm and mediastinum. The visceral pleura covers the outer surfaces of the lungs, extending into the fissures between the lobes. The two pleural cavities are separated by the mediastinum. Pleural cavity contain pleural fluid to reduce friction between the two layers of the pleural during respiration.



Respiratory physiology:

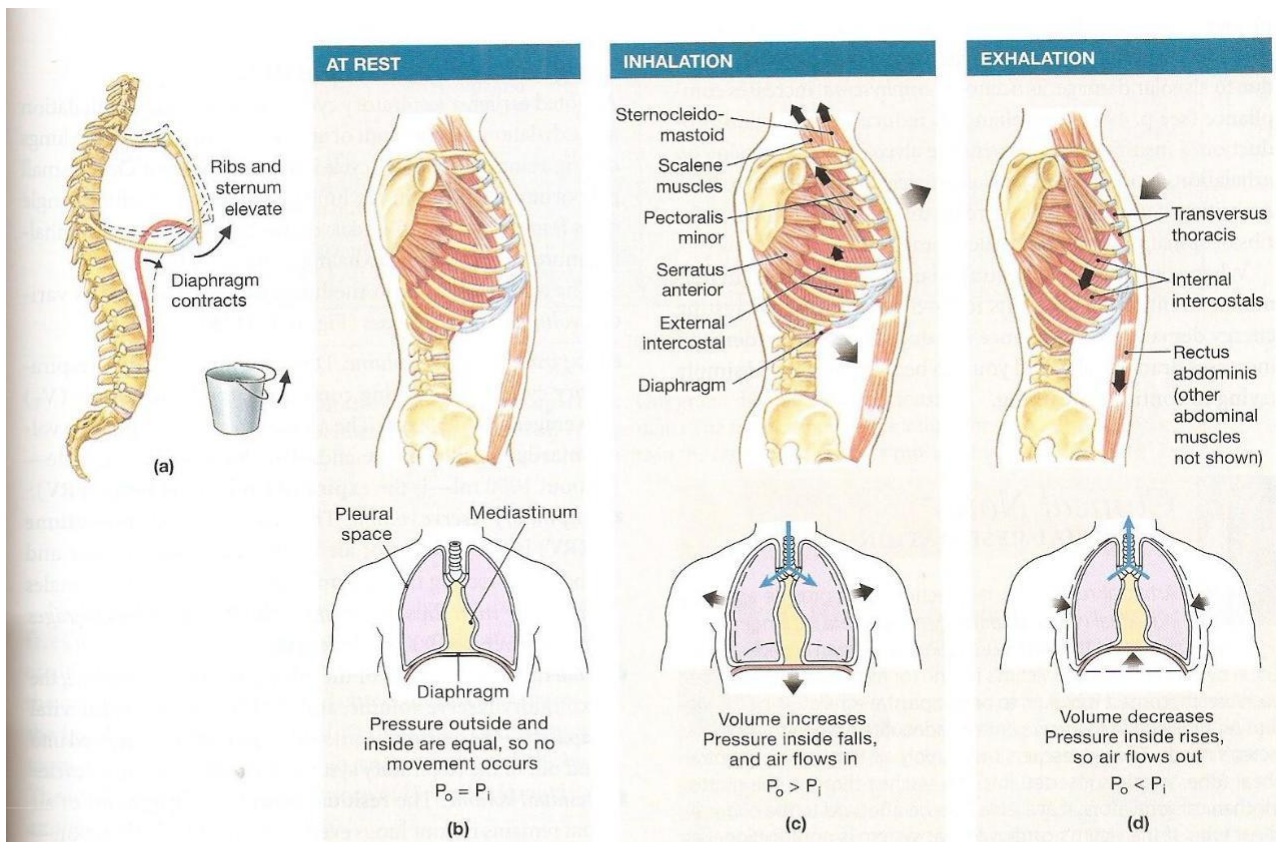
- ▶ The process of respiration involves three integrated steps:

- ▶ Step 1: pulmonary ventilation, or breathing, which involves the physical movement of air into and out of the lungs.
- ▶ Step 2: gas exchange, which involves gas diffusion at two sites: across the respiratory membrane between alveolar air spaces and alveolar capillaries. And across capillary cell membranes between blood and other tissues.
- ▶ Step 3: gas transport, which involves the transport of oxygen and carbon dioxide to and from the alveolar capillaries and the capillary beds in other tissues.
- ▶ Abnormalities affecting any of these processes will ultimately affect the gas concentrations (hypoxia, or anoxia) of the interstitial fluids and, thus, cellular activities as well.

Pulmonary ventilation:

- ▶ Pulmonary ventilation is the physical movement of air into and out of the respiratory tract. A single breath, or respiratory cycle, consists of an inhalation (or inspiration) and exhalation (or expiration).
- ▶ The respiratory rate is the number of breaths per minute. This rate in normal adults at rest ranges from 12 to 18 breath per minute. Children breathe more rapidly, about 18 to 20 breaths per minute.
- ▶ Breathing functions to maintain adequate alveolar ventilation, the movement of air into and out of the alveoli. Alveolar ventilation prevents the buildup of carbon dioxide in the alveoli and ensures continuous supply of oxygen that keeps pace with absorption by the bloodstream.
- ▶ Changes in the volume of the thoracic cavity result from movements of the diaphragm and rib cage. As the volume of the container (the lungs) increases, the pressure of the gas (air) decreases; as volume decreases, pressure increases.
- ▶ At the start of a breath, pressures inside and outside the lungs are identical, and there is no movement of air (figure15-10b).
- ▶ When the diaphragm contracts and the movement of respiratory muscles enlarges the thoracic cavity, the pleural cavities and lungs expand to fill the additional space, so the pressure inside the lungs decreases. Air now enters the respiratory passageways because the pressure inside the lungs (P_i) is lower than the atmospheric pressure (pressure outside, or P_o) (figure15-10c).

Downward movement of the diaphragm during exhalation reverse the process and reduce the volume of the lungs. Pressure inside the lungs now exceeds atmospheric pressure, and air moves out of the lungs (figure15-10d).



● **FIGURE 15-10 Pressure and Volume Relationships in the Lungs.** (a) Just as raising the handle of a bucket increases the amount of space between it and the bucket, the volume of the thoracic cavity increases when the ribs are elevated and when the diaphragm is depressed during contraction. (b) When the rib cage and diaphragm are at rest, the pressures inside and outside are equal, and no air movement occurs. (c) During inhalation, elevation of the rib cage and depression of the diaphragm increase the volume of the thoracic cavity. Pressure in the lungs decreases, and air flows into the lungs. (d) During exhalation, the rib cage returns to its original position or the diaphragm relaxes, reducing the volume of the thoracic cavity. Pressure in the lungs rises, and air flows out of the lungs. During both inhalation and exhalation, contraction of accessory muscles may assist movements of the rib cage to increase the depth and rate of respiration.

Modes of breathing:

The respiratory muscles are used in various combinations, depending on the volume of air that must be moved into or out of the system. Respiratory movements are classified as quiet breathing or forced breathing.

Quiet breathing, inhalation involves muscular contractions, but exhalation is passive. Inhalation involves the contraction of the diaphragm muscles (75% of air) and the external intercostal muscles (25% of air).

- ▶ **forced breathing**, both inhalation and exhalation are active. Forced breathing involves the accessory muscles during inhalation and the internal intercostal muscles and abdominal muscles during exhalation.

- ▶ As noted earlier, A respiratory cycle is a single cycle of inhalation and exhalation.

- ▶ Tidal volume (V_T): the amount of air moved into or out of the lungs during a single respiratory cycle, the average V_T is 500ml.

- ▶ Expiratory reserve volume (ERV): is the amount of air that could be voluntarily expelled at the end of a respiratory cycle, it is about 1000ml.

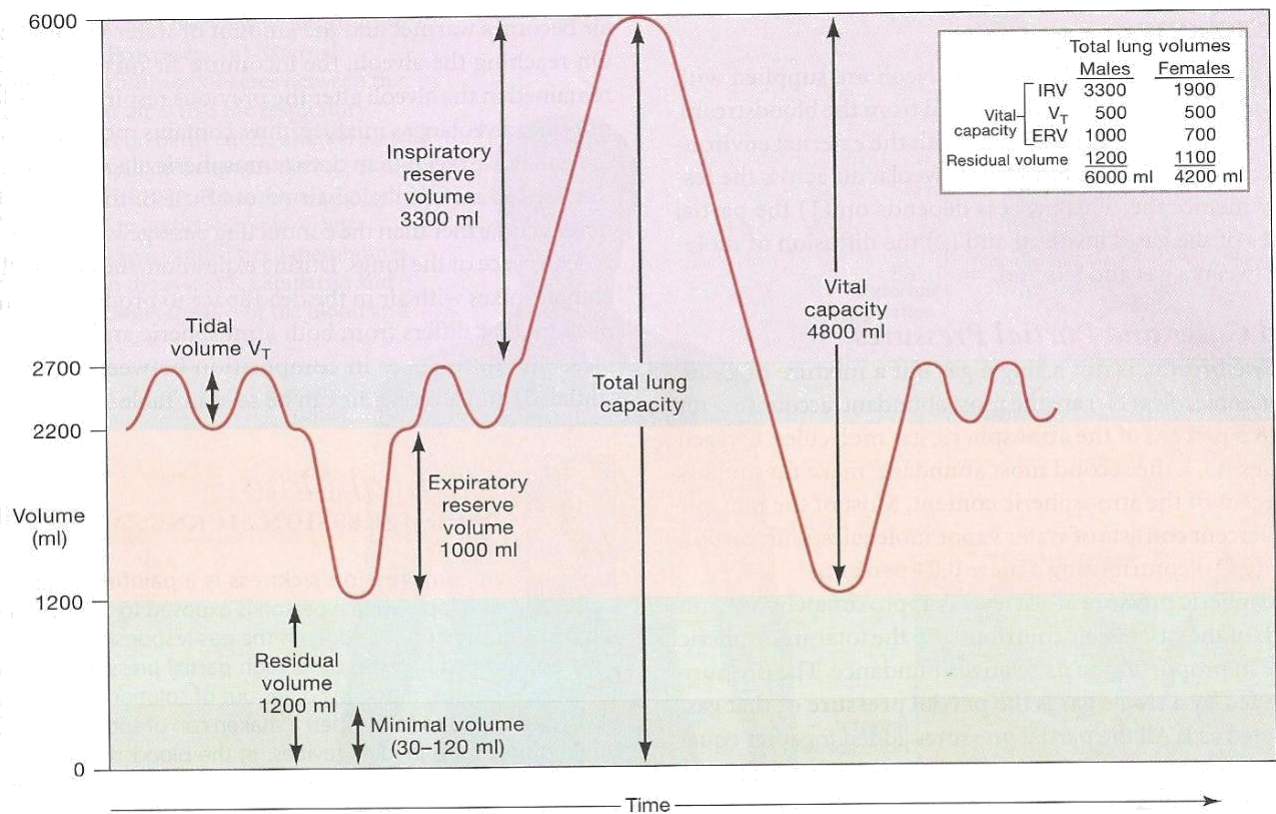
- ▶ Inspiratory reserve volume (IRV): is the amount of air that can be taken in over and above the resting tidal volume. Because the lungs of the males are larger than those of females. The IRV of males averages 3300ml versus 1900ml in females.

- ▶ Vital capacity: the sum of the ERV and IRV and V_T . It is the maximum amount of air that can be moved into and out of the respiratory system in a single respiratory cycle.

- ▶ Residual volume: is the amount of air that remains in the lung even after maximal exhalation, it average about 1200ml in males and 1100ml in females.

- ▶ Minimal volume: is the amount of air that remains in the respiratory system after penetration of the chest cavity (pneumothorax), it about (30-120ml).

- ▶ Anatomic dead space: is the total volume of respiratory passageways of the lungs, it average about 150ml which not take part in gas exchange with the blood.



● **FIGURE 15-11 Respiratory Volumes and Capacities.** This graph diagrams the relationships between the respiratory volumes and capacities of an average male. The table compares the values for males and females. The red line indicates the volume of air within the lungs as respiratory movements are performed.

Gas exchange:

- ▶ During pulmonary ventilation, the alveoli are supplied with oxygen, and carbon dioxide is removed from the bloodstream. The actual process of gas exchange with the external environment occurs between the blood and alveolar air across the respiratory membrane. This process depends on:
 - ▶ 1- The partial pressures of the gases involved (the pressure contributed by single gas), for oxygen $P_{O_2} 159 \text{ mmHg}$ in the atmospheric air. Each gas contributes to the total pressure in proportion to its relative abundance.
 - ▶ 2- The diffusion of molecules between the gas and a liquid.

الوحدة الرابعة وعشرون - المحاضرة الخامسة وعشرون- الزمن: 120 دقيقة

أهداف المحاضرة

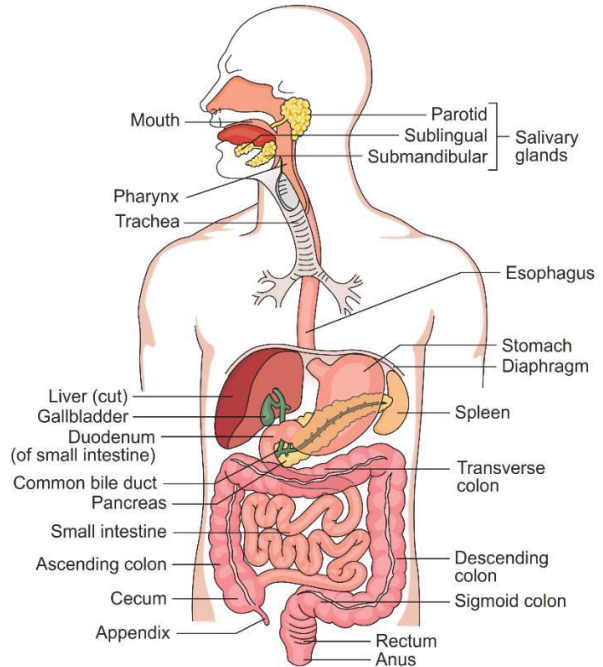
يتوقع في نهاية الجلسة أن يكون الطالب قادراً على معرفة ماهو digestive system

الأساليب والأنشطة والوسائل التعليمية

م	الأساليب والأنشطة التدريبية	الوسائل التدريبية
23	<ul style="list-style-type: none">• محاضرة• مناقشة• سؤال وجواب	<ul style="list-style-type: none">• جهاز حاسوب• جهاز عرض• سبورة• اوراق واقلام

المادة العلمية:

The digestive system is composed of a continuous tract beginning with the oral cavity and ending at the anus. This tract, called the alimentary canal or the gastrointestinal (GI) tract, is complemented by accessory organs that convert food and fluids into a form that permits the body to absorb nutrients. The GI tract is



divided into two sections: the upper GI tract, which consists of the oral cavity (mouth), oesophagus, and stomach, and the lower GI tract, which consists of the intestines. The three main functions of the digestive system are **digestion**, **absorption**, and **elimination**.

The Upper Gastrointestinal Tract

Digestion begins in the oral cavity where food is broken apart by **mastication**, which is a technical term for chewing. Saliva produced by the salivary glands moistens the food.

From the **pharynx**, the food bolus passes into the oesophagus where it is lubricated with mucus before being carried into the **stomach** by wavelike muscular contractions called **peristalsis** [from the Greek word *peristaltiko*

(clasp and compress)]. The **cardiac sphincter** [(from the Greek word *sphingein: to bind tight*)] is a ring-like muscle that controls the flow from the oesophagus into the stomach.

The stomach is the center of the system, both physically and functionally. Its first job is to act as a temporary storage place for the food while it does its second job: secreting acid and enzymes to help break down proteins, fats, and carbohydrates.

The partially digested food (**chyme**) passes through the **pyloric sphincter**, a muscle at the distal end of the stomach, and into the **duodenum**.

The Lower Gastrointestinal Tract

The lower GI tract begins with the small intestine, which extends from the pyloric sphincter to the first part of the large intestine. Although it is about 20 feet in length, it is known as the small intestine because it is smaller in diameter than the large intestine.

The small intestine is divided into three parts: the **duodenum** [from the Greek *dodekadaktylon (12 fingers long)*], **jejunum** [from the Latin word *jejunus (empty, fasting, hungry)*], and **ileum** [a Latin word meaning “flank, groin”]. From the duodenum, chyme moves into the jejunum and from there into the ileum. The ileocecal sphincter controls the flow from the ileum into the cecum, the first part of the large intestine.

Accessory Organs

The **salivary glands**, **liver**, **gallbladder**, and **pancreas**, although not part of the alimentary canal, play a key role in the digestive process and are referred to as accessory organs of the digestive system.

Salivary Glands

The senses of taste and smell stimulate the salivary glands to secrete **saliva**, a watery liquid that contains enzymes that begin the digestive process. Saliva also helps eliminate bacteria in the mouth and keeps the teeth and tongue clean.

Liver

The liver, located in the upper right quadrant of the abdomen under the dome of the diaphragm, plays many important roles in digestion, metabolism, and detoxification of harmful substances. One of its main digestive functions is the manufacture and secretion of **bile**. Our bodies need bile to process fats before they are released into the bloodstream. Once bile is produced in the liver, it travels down the **common bile duct** to the **gallbladder** for storage.

Gallbladder

Although the liver produces and recycles bile, the gallbladder, which is located in a depression under the liver, stores, condenses, and delivers the bile to the small intestine. The gallbladder is also sometimes referred to as the **cholecyst**.

Pancreas

the pancreas [from the Greek words **pan** (all) and **creas** (flesh, meat)] is an elongated feather-shaped organ that lies posterior to the stomach. It has both digestive and endocrine functions. It produces digestive enzymes that aid in processing carbohydrates and fats in foods as well as secreting hormones directly into the bloodstream.

Disorders of the Upper Gastrointestinal Tract

- **Parotitis**: is an inflammation of the parotid gland. 3

-
14. **Dysphagia** [**dys-** (difficulty); **phag/o** (eating, swallowing); **-ia** (condition of)]: difficulty in swallowing.
 15. **Esophagitis**: inflammation of the oesophagus.
 16. **Hiatus hernia** [**from the Latin word hiatus** (opening); **-al** (adjective suffix)] **hernia** [**the Latin word hernia** (rupture)]: stomach protruding into the thoracic cavity.
 17. **Gastroesophageal reflux disease**: upward flow of stomach acid into the oesophagus.
 18. **Gastritis** [**gastr/o** (stomach); **-itis** (inflammation)]: inflamed gastric mucosa.

Disorders of the Lower Gastrointestinal Tract

- **Appendicitis** [**from the Latin word appendix** (something attached); **-itis** (inflammation)]: a common acute inflammatory disease. The appendix can become abscessed and may rupture, causing **peritonitis** (an inflammation of the peritoneum, which is the sac that lines the abdominal cavity).
- **Cholelithiasis** [**chol/e** (bile, gall); **-lithiasis** (condition of having stones)]: a condition in which stones reside in the gallbladder or bile ducts.
- **Cholecystitis** [**cholecyst/o** (gallbladder); **-itis** (inflammation)]: inflammation of the gallbladder.
- **Hepatitis** [**hepat/o** (liver); **-itis** (inflammation)]: inflammation of the liver
- **Jaundice** [**from Middle French word jaunisse** (yellow)]: a symptom of hepatitis characterized by a yellow appearance of skin or eyes.
- **Cirrhosis** of the liver: chronic liver disease.

Colonoscopy [colon/o (colon); -scopy (viewing)]: visual examination of the colon with a colonoscope.

الوحدة السادسة وعشرون - المحاضرة السادسة وعشرون - الزمن:

120 دقيقة

أهداف المحاضرة السادسة وعشرون:

يتوقع في نهاية الجلسة أن يكون الطالب قادراً على معرفة ماهو metabolism

الأساليب والأنشطة والوسائل التعليمية

م	الأساليب والأنشطة التدريسية	الوسائل التدريسية
26	<ul style="list-style-type: none">• محاضرة• مناقشة• سؤال وجواب	<ul style="list-style-type: none">• جهاز حاسوب• جهاز عرض• سبورة• اوراق واقلام

المادة العلمية:

Carbohydrate Metabolism Definition of Metabolism: The chemical processes occurring within a living cell or organism that are necessary for the maintenance of life. All these are called anabolism and catabolism. Metabolism Anabolic reaction catabolic reaction 1. synthesis of complex molecules 1.break down of large molecules from simple compound. Such as polysaccharides, proteins 2. energy is needed for synthesis Into small molecules like, CO₂, (endergonic reaction) NH₃, H₂O. 2. liberated energy. (exergonic reaction) Digestion and absorption: Digestion of CHO is accomplished by the enzymes of digestive fluids, saliva, pancreatic juice and intestinal juice. 1. mouth: salivary glands secrete saliva Saliva contains: α- amylase (ptyalin), water 99.5% and glycoprotein as food lubricant. α- amylase, hydrolysis starch to dextrin and maltose. PH of α- amylase = 5.8 – 7.1 less than 4.0 is in active 2. stomach ----- no digestion is seen in stomach , amylase is in active Because the PH of stomach (1 - 2) very acidic. 3. small intestine: it is the major site of digestion of CHO, pancreatic amylase hydrolyze dextrin into maltose. The optimum PH of amylase = 7.1 4. intestinal mucosal : mucosal cell membrane – bound enzymes , the site where disaccharides hydrolyze. Maltose maltase glucose + glucose Sucrose sucrase glucose + fructose Lactose lactase glucose + galactose

Absorption of Carbohydrates:

1. transport into epithelial cells (of the villi) glucose and galactose are transported by active transport, while fructose is transported by facilitated diffusion.
2. transport from epithelial cells into the blood stream is by facilitated diffusion. Fate of glucose after absorption In the liver, glucose undergoes variety of chemical changes depending upon the physiological need of the body.
 1. Body need for energy: glucose oxidized completely to CO₂, H₂O and energy by (glycolysis and citric acid cycle).
 2. Excess glucose may be converted to glycogen, deposit in liver, muscle tissues By (glycogenesis)
3. To maintain glucose blood level, liver glycogen reconverted to glucose enters blood By (glycogenolysis).
4. excess glucose after conversion to glycogen , convert to fatty acids stored in adipose tissue as triglycerides (lipogenesis).
5. small amounts of glucose may be utilized for the synthesis of ribose and deoxyribose for synthesis of nucleic acids.
6. in muscle contraction, only partial degradation of glucose may take place, resulting in formation of lactic acid disposed off by the liver. The metabolism of CHO may be subdivided in the following categories. Glycolysis: (from glycolysis, an term for glucose + -lysis degradation)
 1. It is the metabolic pathway that converts glucose C₆H₁₂O₆, into pyruvate.
 2. The free energy released in this process is used to form the high-energy molecules ATP and NADH.
 3. Glycolysis is an oxygen independent metabolic pathway, said to be anaerobic.
 4. Glycolysis occurs in the cytosol (cytoplasm) of the cell.
 5. The most common type of glycolysis is the Embden–Meyerhof–Parnas (EMP), which was discovered by Gustav Embden, Otto Meyerhof, and Jakub Karol Parnas.
 6. The glucose in the blood circulation, when enter the cell become phosphorylated given by ATP (Activation by phosphate group).
 7. This phosphorylation occurs on the cell membrane by the action of two enzymes. 1. specific enzyme (glucokinase) in the liver. 2. nonspecific enzyme (hexokinase), Present in liver and other extra hepatic cell
 8. Glu-6- p is an important compound for several metabolic pathways.

The reaction is irreversible.

الوحدة السابعة وعشرون - المحاضرة السابعة وعشرون- الزمن: 120 دقيقة

أهداف المحاضرة السابعة وعشرون:

يتوقع في نهاية الجلسة أن يكون الطالب قادراً على معرفة urinary system

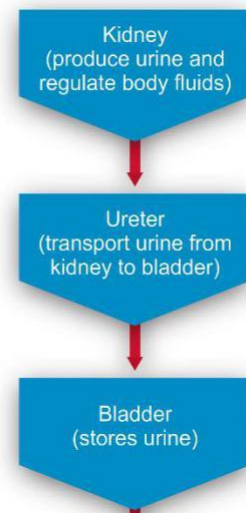
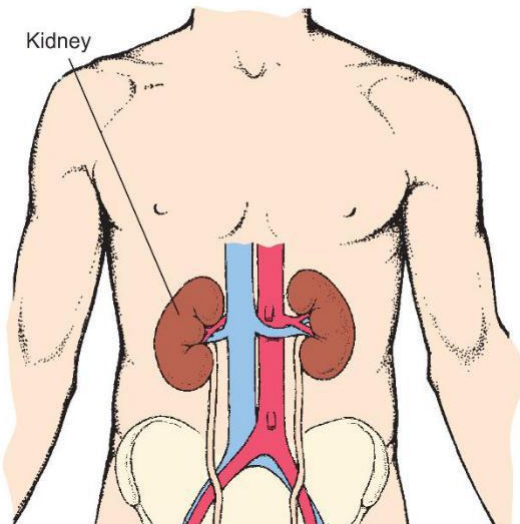
الأساليب والأنشطة والوسائل التعليمية

م	الأساليب والأنشطة التدريبية	الوسائل التدريبية
27	<ul style="list-style-type: none">• محاضرة• مناقشة• سؤال وجواب	<ul style="list-style-type: none">• جهاز حاسوب• جهاز عرض• سبورة• اوراق واقلام

المادة العلمية:

The Urinary System

The urinary system is composed of the **kidneys**, **ureters**, **urinary bladder**, and **urethra**. The primary function of the urinary system is to remove wastes and toxins from the body.



The kidneys

The kidneys are bean-shaped organs and are about the size of a man's fist; they lie at the back of the abdominopelvic cavity, along each side of the spinal column. Each kidney is covered by a thin membrane called the **renal capsule**. A thicker layer of fatty tissue, called the **perirenal fat**, surrounds the renal capsule

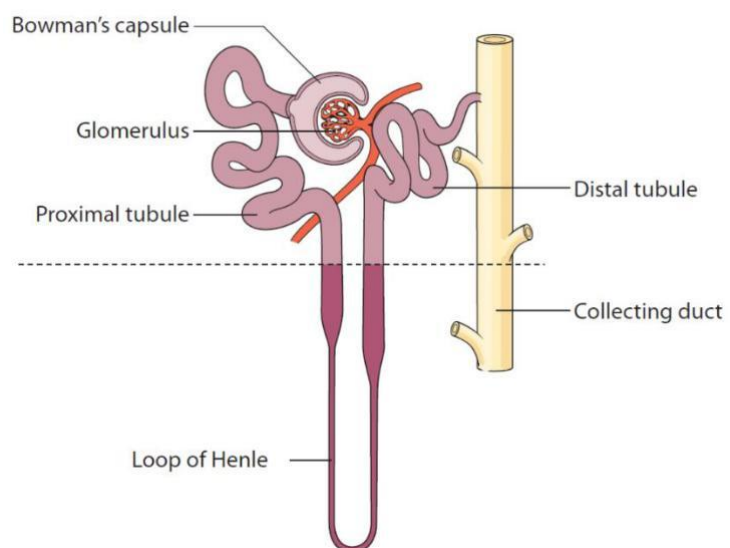
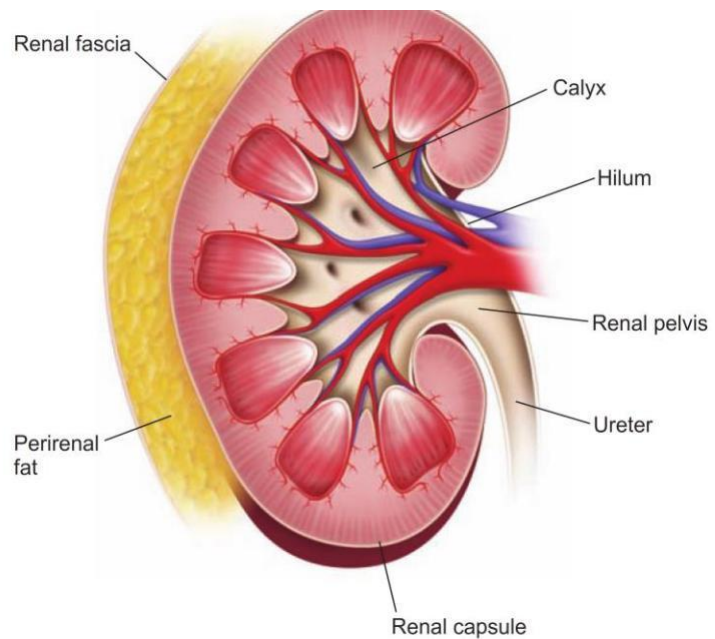
and thus provides protection for this vital organ. Finally, a thin layer of connective tissue, called the **renal fascia**, forms each kidney's outer covering.

The kidneys produce **urine** [from the Greek word **ouron** (**urine**)] and remove two

natural products of metabolism, **urea** and **uric acid**, along with other waste products from the blood. The kidneys also filter, reabsorb, and secrete nonwaste products back into the system.

Filtration and the urine production process begin in the **nephrons** [from the Greek word **nephros** (**kidney**)], which are the functional units of the kidneys. Each kidney has approximately 1 million nephrons, and each nephron

contains a tiny filtration unit called the **glomerulus** [a Latin word meaning "small ball," "round knot"], which consists of a cluster of capillaries. Blood travels through the capillaries, which permit waste products within the urine to enter the ureter, where it is carried to and stored in the urinary bladder.



The bladder collects the urine until the volume triggers the urge to urinate, an event known as the **micturition reflex**. Urination is regulated by two **sphincters**, the circular muscles that surround the urethra. They are the internal urethral sphincter, which is located at the entrance to the urethra and is involuntarily controlled, and the external urethral sphincter, which is located at the distal end of the urethra and is under conscious control.

Disorders of the Renal System

- **Dysuria** [**dys-** (difficult); **ur/o** (urine); **-ia** (condition)]: painful, difficult urination.
- **Incontinence**: the loss of urinary control.
- **Retention**: the inability to empty the bladder.
- **Cystitis** [**cyst/o** (bladder); **-itis** (inflammation)]: inflammation of the bladder.
- **Pyelonephritis**: [**pyel/o** (pelvis); **nephro/o** (kidney); **-itis** (inflammation)]: inflammation of the renal or kidney pelvis due to local bacterial infection.
- **Glomerulonephritis** [**glomerul/o** (glomerulus); **nephro/o** (kidney); **-itis** (inflammation)]: renal disease characterized by inflammation of glomeruli.
- **Renal failure**: kidneys cease urine production.

الوحدة الثامنة وعشرون - المحاضرة التاسعة وعشرون- الزمن: 120 دقيقة

أهداف المحاضرة الثامنة وعشرون:

يتوقع في نهاية الجلسة أن يكون الطالب قادراً على معرفة ماهو fluid-electrolyte and acid – base balance

الأساليب والأنشطة والوسائل التعليمية

م	الأساليب والأنشطة التدريبية	الوسائل التدريبية
28	<ul style="list-style-type: none">• محاضرة• مناقشة• سؤال وجواب	<ul style="list-style-type: none">• جهاز حاسوب• جهاز عرض• سبورة• اوراق واقلام
	<ul style="list-style-type: none">•	<ul style="list-style-type: none">•

Fluid, electrolyte, and acid-base balance

- ⌚ About 46% to 60% of the average adult's weight is water, which is vital to health and normal cellular function, serving as:
 - A medium for metabolic reaction within cell
 - A transport of nutrients, waste product, and other substances
 - A lubricant
 - An insulator and shock absorber
 - One means of regulation and maintaining body temperature
- ⌚ Age, sex, and body fat affect the total body water.
- ⌚ Infant have the highest proportion of water. Accounting for 70% -80% of their body weight
- ⌚ Fat tissue is essentially free of water. lean tissue containing significant amount of water.

Distribution of body fluid

The body fluid is divided into two major components:



intracellular fluid.



extra cellular fluid.



intracellular fluid:

- ⌚ is found within the cell of the body
- ⌚ constitute approximately two third of the total body fluid in adult
 - ⌚ is vital to normal cell function
 - ⌚ It contain solute such as oxygen, electrolyte and glucose
- ⌚ It provide medium in which metabolic process of the cell take place

🕒 **extra cellular fluid:**

found outside the cell

Accounts for about one-third of the total body fluid

divided into:

intravascular fluid(plasma) is found within the vascular system

interstitial surrounding the cell

Lymph and transcellular fluid include cerebrospinal,
pericardial.

Movement of body fluids and electrolytes



Osmoses: is the movement of water across the cell membrane, from the less concentrated solution to the more concentrated solution

Isotonic solution: solution has the same osmolality as body fluid, normal saline, and 0.9% sodium chloride

Hypertonic solution: have a higher osmolality than body fluid: 3% sodium chloride

Hypotonic solution: have low osmolality than body fluid, e.g. 0.45 sodium chloride

Movement of body fluids and electrolytes

- **Diffusion:** is the continual intermingling of molecules in liquids. Gases or solid brought about the random movement of the molecules

- ♦ **Filtration:** is a process whereby fluid and solution move together across membrane from one component to another

- ♦ **Active transport:** substances can move across cell membrane from less concentration solution to amore concentration solution one by active transport

Regulation of body fluid

□ Fluid intake:

The average adult needs 2.500 ml /day
1.500 ml drinks and 100ml from the food

- ♦ Fluid output: there are four rote of fluid output:
 - urine: normal urine output from an adult is 1.400 to 1.500 ml per 24 hr .if fluid loss through perspiration is large, whoever , urine volume decreases to maintain fluid balance in the body
 - insensible loss through the skin and through the lung
 - noticeable loss through the skin
 - loss through the intestines in feces

Ra'eda Almashaqba

- **Average daily output from an adult is 2.300 to 2.600 ml.**

- **Obligatory loss:** certain fluid losses are required to maintain normal body function.

Maintaining homeostasis:

- ⌚ Kidney
- ⌚ Antidiuretic hormone
- ⌚ Renin angiotensin aldosterone system
- ⌚ Atrial natriuretic factor

Regulating electrolyte:

- ⌚ Electrolytes are important for:
 - Maintaining fluid balance contributing to acid base regulation.
 - Facilitating enzyme reaction.
 - Transmitting neuromuscular reaction.
- Ra'eda Almashaqba

Acid- base balance

- ⌚ Acid is substance that release hydrogen ions in solution.
- ⌚ Base or alkalis have a low hydrogen ions concentration and can accept hydrogen ions in solution.
- ⌚ PH are reflect the hydrogen ions in solution.
 - ⌚ The higher hydrogen ions is the lower pH.
 - ⌚ PH of water is 7.
 - ⌚ PH Low than 7 is acidic.
 - ⌚ PH Higher than 7 is base or alkaline.
 - ⌚ Normal pH 7.35- 7.45.

Ra'eda Almashaqba

Regulation of acid base balance

- ⌚ **Buffers:** bicarbonate (HCO_3); prevent excessive changes in pH by removing or releasing hydrogen ions.
- ⌚ **Respiratory regulation:** lung help regulating acid- base balance by eliminating or retaining carbon dioxide (CO_2).
- ⌚ **Renal regulation:** the renal are the ultimate long term regulation of acid base balance by selectively excreting or conserving bicarbonate and hydrogen ions ■

الوحدة الثلاثون - المحاضرة الثلاثون- الزمن: 120 دقيقة

أهداف المحاضرة الثلاثون:

يتوقع في نهاية الجلسة أن يكون الطالب قادراً على معرفة ماهو reproductive system

الأساليب والأنشطة والوسائل التعليمية

الوسائل التدريسية	الأساليب والأنشطة التدريسية	م
<ul style="list-style-type: none">• جهاز حاسوب• جهاز عرض• سبورة• اوراق واقلام	<ul style="list-style-type: none">• محاضرة• مناقشة• سؤال وجواب	30

المادة العلمية:

INTRODUCTION

The reproductive system is a collection of internal and external organs — in both males and females — that work together for the purpose of procreating.

Due to its vital role in the survival of the species, many scientists feel that the reproductive system is among the most important systems in the entire body.

Of the body's major systems, the reproductive system is the one that differs most between sexes, and the only system that does not function until puberty.

The male reproductive system is responsible for delivering sperm to the female reproductive system



MALE REPRODUCTIVE SYSTEM

In males, the reproductive organs include the penis, the testes, a number of storage and transport ducts, and some supporting structures.

The two oval-shaped testes (also called testicles) lie outside the body in a pouch of skin called the scrotum, where they can maintain the optimum temperature for sperm production – approximately 5° F, lower than body temperature.

Testes are oval-shaped glands responsible for the manufacture of sperm and the sex hormone testosterone.

From each testis, sperm pass into a coiled tube – the epididymis – for the final stages of maturation.