

Psoriasis *

* It is a chronic relapsing inflammatory disorder characterized by a variety of morphological lesions that present in a number of forms. Psoriasis can present at any time in life, more prevalent in the 2nd & 5th decades, rare in infants & uncommon in children. Men & women are equally affected. The exact etiology still unclear, but inherited & environmental factors are implicated .

* Psoriasis lesions often develop at sites of skin trauma, such as sunburn & cuts, sometimes following streptococcal throat infection & during period of stress.

* Diagnosis:

The diagnosis of psoriasis can be confusing. It can be located on various parts of the body & in a variety of different forms. Plaque & scalp psoriasis are the only forms of the condition that can be managed by the community pharmacist.

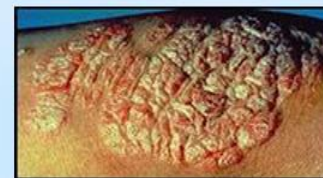
* Clinical features of plaque psoriasis:

It is classically presents with characteristic salmon- pink lesions with silvery –white scales & well defined boundaries.

Lesion located in elbows & knees, it varies in size from pin point to covering extensive areas. If the scales on the surface of the plaque are gently removed & the lesion is then rubbed it reveals pin point bleeding from the superficial dilated capillaries.

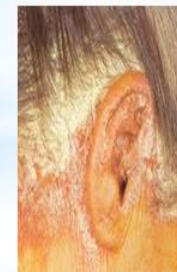Clinical features of scalp psoriasis:

It is mild, exhibit slight redness of the scalp , extends beyond the hair margin & behind the ear. In severe cases there are marked inflammation & thick scaling.



Clinical features of scalp psoriasis:

It is mild, exhibit slight redness of the scalp , extends beyond the hair margin & behind the ear. In severe cases there are marked inflammation & thick scaling.



- ** Psoriasis often presents in asymmetrical distribution . Itching are not present (not a normal feature) unlike other condition like dermatitis & fungal infection (e.g. Dandruff).**
- ** There are number of medicines cause rashes that look like psoriasis or aggravate it, include: Lithium, β - blockers, chloroquine, terbinafine & withdrawal from steroids also might be causes.**

Managements: There is a fact that there is no cure for psoriasis , but therapy may cause remission to some extent .OTC treatment should limited for mild to moderate plaque psoriasis & scalp psoriasis. A severe form should be referred.

Emollients: It helps to soften & soothe the skin, so reducing cracking & dryness. All are chemically inert & can safely used from birth to all ages, e.g.vaseline & Eurax.

Keratolytic : Such as salicylic acid & lactic acid incorporated into emollients(aid in cleaning scale). Often used for scalp psoriasis where very thick scaling occurs).

*** Dithranol:**

It is a traditional & effective treatment of psoriasis. A short- contact therapy is needed because prolong exposure can lead to irritation & burning skin.

Starting its use with a lowest possible concentration 0.1% for 30 minutes(then washed off). Gradually increase the concentration to 1% until improvement is noticed ,if no response then refer the patient to physician.

Patient might experience burning even at low concentration, if not tolerated, discontinue therapy. Both dithranol & coal tar had a pleasant odour & can stain skin.

*** Coal tar:** Remain the mainstay of treatment until the introduction of dithranol, corticosteroid & recently vitamin D analogous. It can cause local irritation & stain the skin & cloths. Safe for all ages group & even during pregnancy.

- * **Calcipotriol**: Vitamin D derivatives doesn't smell or stain, widely used to treat mild to moderate psoriasis .
- * **Topical steroids**: used for scalp psoriasis. Although effective in suppressing skin plaques on the body but large amount are required over time & chronic use, so result in severe steroid side effect.
- * **Second-line treatment** may include phototherapy or systemic therapy with **methotrexate** or **ciclosporin**. Unfortunately, all of these have potentially serious side effects.
- * Methotrexate has been shown to be effective but relapse usually occurs within 6 months of discontinuation.
- * Long-term methotrexate treatment carries the risk of liver damage.