

## **Protection, Support, and Locomotion**

### **Skin: The Body's Protection**

Skin, the main organ of the integumentary system, is composed of layers of the four types of body tissues: epithelial, connective, muscle, and nervous. Epithelial tissue, found in the outer layer of the skin, functions to cover surfaces of the body. Connective tissue, which consists of both tough and flexible protein fibers, serves as a sort of organic glue, holding your body together. Muscle tissues interact with hairs on the skin to respond to stimuli, such as cold and fright. Nervous tissue helps us detect external stimuli, such as pain or pressure. The skin is a flexible and responsive organ. Skin is composed of two principal layers—the epidermis and dermis. Each layer has a unique structure and performs a different function in the body.

One function of skin is to help maintain homeostasis by regulating your internal body temperature.

### **Bones: The Body's Support**

The adult human skeleton contains about 206 bones. Its two main parts. The axial skeleton includes the skull and the bones that support it, such as the ribs. The appendicular skeleton includes the bones of the arms and legs and structures associated with them.

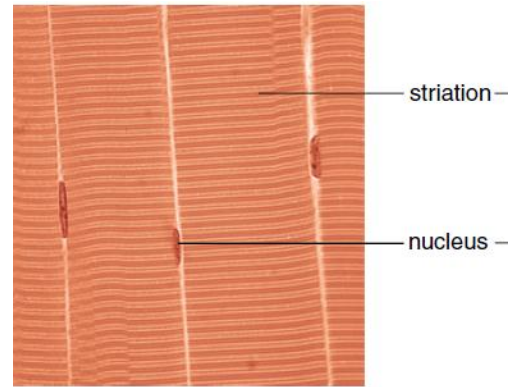
The primary function of your skeleton is to provide a framework for the tissues of your body. The skeleton also protects your internal organs, including your heart, lungs, and brain. The arrangement of the human skeleton allows for efficient body movement. Muscles that move the body need firm points of attachment to pull against so they can work effectively. The skeleton provides these attachment points. Bones also produce blood cells. **Red marrow** (found in the, femur, sternum, ribs, vertebrae, and pelvis) is the production site for red blood cells, white blood cells, and cell fragments involved in blood clotting.

### **Muscles for Locomotion**

Muscle fibers contain actin filaments and myosin filaments, whose interaction accounts for movement. There are three types of muscles:

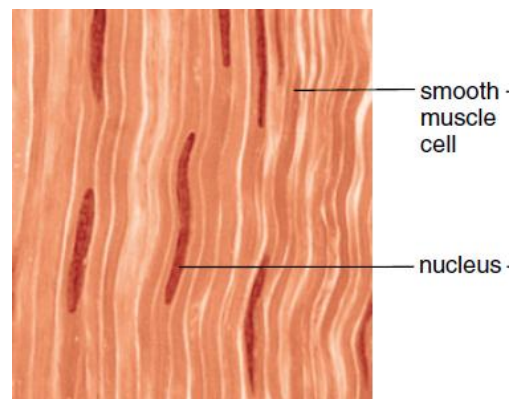
### 1- Skeletal muscle

- Has striated cells with multiple nuclei.
- Usually attached to skeleton.
- Functions in voluntary movement.



### 2- Smooth muscle

- Has spindle-shaped cells, each with a single nucleus.
- Occurs in walls of hollow internal organs.
- Functions in movement of substances in lumens of body.
- No cross striations, involuntary.



### 3-Cardiac muscle

- Has branching striated cells, each with a single nucleus.
- Occurs in the wall of the heart, Involuntary.
- Functions in the pumping of blood.

