

Crown and Bridge

اد. عبد الكريم حاسم العزاوي

Restoration of Endodontically Treated Teeth

Special techniques are needed to restore endodontically treated teeth. Usually a considerable amount of tooth structure has been lost because of caries, endodontic treatment, and the placement of previous restoration. The loss of tooth structure makes retention of subsequent restoration more problematic and increase likelihood of fracture during functional load.

Factors influence the choice of technique: -

- 1- The type of tooth (whether it is an incisor, canine, premolar or molar).
- 2- The amount of remaining coronal tooth structure. Which is the most important indicator when determine the prognosis.

Indications:

1. Restoration of endodontically treated teeth when excessive amount of the tooth structure is removed or lost by caries, trauma , filling, and making the retention of other types impossible.
2. Realignment of malposed teeth.
3. As bridge retainer (short span bridge).
4. Tooth with short clinical crown.

Factors to be considered in selection of a tooth for post crown

1. The root of the tooth should be sufficiently shaped, with adequate length and width.
 - If there is an abnormal shape affecting the shape of the tooth, post crowns can not be constructed.
 - Length of the root should be sufficient to use the post crown.
2. The root should be without internal or external resorption.
3. Alignment of the root, any abnormality in the alignment of the root in relation to the adjacent teeth will affect the steps of post crown construction.
4. Quality of the root filling, in order to construct a post crown the tooth should be filled endodontically with gutta percha

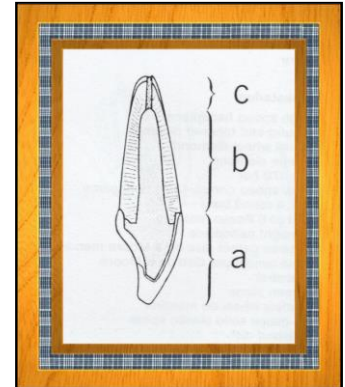
Before restoration, existing endodontically treated teeth need to be assessed carefully for the following: -

- Good apical seal.
- No sensitivity to pressure.
- No exudates.
- No fistula.

No active inflammation.

Parts of post crown:

1. **The post (dowel):** it is the part of the crown, which extended into the root canal; it should be 2/3 of the root length.
2. **The core:** it is the coronal part of the post crown. This replaces any lost coronal tooth structure of the tooth preparation.
3. **The crown,** the crown should be either a full metal, full veneer or jacket crown (acrylic or porcelain).



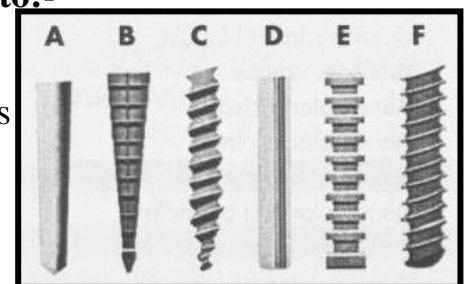
Post can be classified into two main types:-

1-Prefabricated post

Many classifications of prefabricated Posts are available

Prefabricated post could classify according to shape into:-

- A-tapered, smooth-sided posts, B-tapered, serrated posts
 C-tapered threaded posts, D-parallel, smooth-sided posts
 E-parallel, serrated posts, F-parallel, threaded posts





Prefab. Posts fabricated from different materials:-

- Posts made from precious, semiprecious, and non precious alloys.
- Carbon –fiber posts gave increased popularity in recent years consist of bundles of stretched, aligned carbon fibers embedded in an epoxy matrix; it is strong with lower stiffness.

One advantage of carbon fiber post is the ease of its removal for retreatment, by drilling apically.

The chief disadvantage of a carbon fiber post is its black appearance, which presents an esthetic problem.



- High strength ceramic posts (Zirconium) have excellent esthetic properties.

2-Custom-made post: casted in metal, indicated for teeth with root canals whose cross section is not circular or is extremely tapered.

There are two types of post- crowns

1. Two-unit post crown (post and core +crown).
2. One unit post crown (post + core + crown). This type is of historical interest only.

Advantages and indications of two unit system post-crown

1. Young patients under 18 years old, because the gingival-tooth relationship will change with time.
2. Permits fabrication of a replacement crown, if necessary, w/o the need of post removal.
3. A different path of placement than the one selected for the post-and-core may be selected for the crown. This is useful when the tooth is to be used as a FPD abutment.
4. Achieving a satisfactory marginal fit easier because the expansion rate of the two castings can be controlled individually.

POST-CROWN

Procedures:-

A three – stage operation: -

- 1- Removal of the root canal filling material to the appropriate depth.
 - 2- Enlargement of the canal.
 - 3- Preparation of the coronal tooth structure.
- A post cannot be placed if the canal is filled with a full – length silver point, so these must be removed and the tooth retreated with gutta-percha.

Before removing G.P. calculate the appropriate length of the post. It should be adequate for retention and resistance but not long enough to weaken the apical seal.

As a guide, make the post length equal to:-

- 1- The height of the anatomic crown
- 2- Two – thirds the length of the root.

But leave 5mm of apical gutta -percha. On short teeth, it will not be possible to meet both these restrictions, and a compromise must be made. An absolute minimum of 3mm of apical fill is needed.

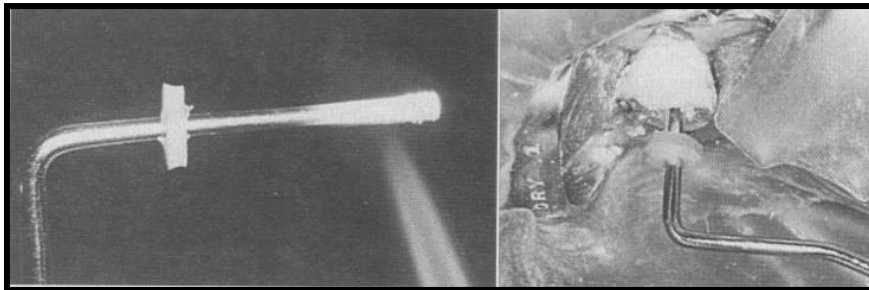
The operator should have acknowledged about the average values for crown and root length.

If the working length is known, the length of the post space can be easily determined.

• **Methods for removing G.P.:-**

A – Using a warmed endodontic plugger.

- Select large enough plugger to hold heat well but not so large that it binds against the canal walls.



- Mark it at the appropriate length (normally endodontic working length minus 5mm) heats it, and places it in the canal to soften the G.P.

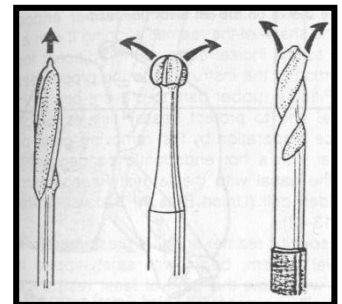
B- Using a rotary instrument.

These are special post preparation instruments, these considered (safe-tip) instruments because they are not end-cutting burs.

- The friction generated between the fill and the tip of these burs softens the G.P. Peeso-Reamers and Gates Glidden drills are often used for this purpose.

- End-cutting instruments should never be used to gain length because root perforation will result.

- The rotary instrument should be slightly narrower than the canal.



- Make sure the instrument follows the center of the G.P. and does not cut dentin.
- When the G.P. has been removed to the appropriate depth, shape the canal as needed, by using an endodontic hand instrument or a low –speed drill.
- Knowledge of average root dimensions is important, because the post should be no more than one third the diameter of the root. With 1mm root wall thickness.
- Knowledge of root canal cross section also is significant in post selection.

Prefabricated posts are circular in cross section, but many root canals are elliptical, which makes uniform reduction with a drill impossible.

In case of prefabricated post system is chosen

Technique simplicity is one advantage of using prefabricated posts.

Enlargement of the canal

1- Enlarge the canal one or two sizes with a drill, endodontic file or reamer that matches the configurations of the post

2- Use a prefabricated post that matches standard endodontic instrument.

- A tapered post will conform better to the canal than a parallel-sided post and require less removal of dentin to achieve an adequate fit. However, it will be slightly less retentive and will cause greater stress concentration.

Most of the time a prefabricated parallel-sided post will fit only in the most apical portion of the canal.

Modified post are available with tapered ends, conform better to the shape of the canal, although they have slightly less retention than parallel-sided do. In the absence of a vertical stop on sound tooth structure, such posts can also create an undesirable wedging effect.

In case of custom made post system is chosen.

Enlargement of the canal: -

- Often very little preparation will be needed. However, undercuts within the canal must be removed, and some additional shaping usually is necessary.
- Be most careful on molars to avoid root perforation.

In mandible molars the distal wall of the mesial root is particularly susceptible. In maxillary molars the curvature of the mesiobuccal root makes mesial or distal perforation more likely.